



Ileum Histoarchitecture Following Aspartame Consumption: Assessment of Actions of *Moringa oleifera* Seed Extract

**Christopher Chiedozi Mbadugha^{a*}, Donatus Gabriel Edem^a,
Iboro Efiong Edet^a, Iberi Patrick Amagwu^b, Francis Nkem Odinukaeze^a
and Abasikponke Raphael Godwin^a**

^a Department of Anatomy, Faculty of Basic Medical Sciences, College of Health Sciences,
University of Uyo, Nigeria.

^b Department of Pharmacognosy and Natural Medicine, University of Uyo, Nigeria.

Authors' contributions

This work was carried out in collaboration among all authors. All authors read and approved the final manuscript.

Article Information

DOI: 10.9734/JAMPS/2022/v24i730311

Open Peer Review History:

This journal follows the Advanced Open Peer Review policy. Identity of the Reviewers, Editor(s) and additional Reviewers, peer review comments, different versions of the manuscript, comments of the editors, etc are available here:
<https://www.sdiarticle5.com/review-history/88096>

Original Research Article

**Received 12 April 2022
Accepted 17 June 2022
Published 01 August 2022**

ABSTRACT

This study aims to determine the effect of *Moringa oleifera* seed extract on ileum histoarchitecture following aspartame consumption. Twenty-seven adult male Albino Wistar rats were used for the study. They were divided into nine groups comprising of: group A (control), administered distilled water; group B, given 0.4 ml (low dose) aspartame; group C, given 1.5 ml (high dose) aspartame; group D1, given 0.6 ml (low dose) aspartame for the first three weeks followed by 1.5 ml (low dose) ethanolic extract of *M. oleifera* seed on the fourth week; group D2 given 0.5 ml (low dose) aspartame for the first three weeks followed by 1.30 ml (low dose) n-hexane extract of *M. oleifera* seed on the fourth week; group E1, given 1.5 ml (high dose) aspartame for the first three weeks and on the fourth week 2.5 ml (high dose) ethanolic extract of *M. oleifera* seed; group E2, given 1.5 (high dose) aspartame for the first three weeks and on the fourth week 3.0 ml (high dose) n-hexane extract of *M. oleifera* seed; group F1 given 1.4ml (high dose) aspartame followed by 2.8ml (high dose) ethanolic extract of *M. oleifera* seed for four weeks; group F2, given 1.3 ml (high dose) aspartame followed by 2.5 ml (high dose) n-hexane extract of *M. oleifera* seed for four weeks.

*Corresponding author: E-mail: christophermbadugha@uniuyo.edu.ng;

Weight measurement of rats was taken once a week throughout the twenty eight days duration of the study. Following anaesthetization, their ileum were harvested and fixed in 10 % buffered formalin. Hematoxylin and Eosin (H&E) staining technique was adopted for routine histological procedure. Data were expressed as mean \pm standard error of mean ($M \pm SEM$) and subjected to one-way analysis of variance (ANOVA). At 95 % confidence interval, P is significant ($P < 0.05$). There was a significant increase ($P = 0.05$) in body weight of both the control and the experimental groups as the experiment progressed. Histological findings revealed that aspartame both in low and high doses has disruptive effects on the histoarchitecture of ileum and high dose ethanolic extract of *M. oleifera* seed has the capacity to ameliorate the effects. Hence, caution is needed in aspartame consumption.

Keywords: Albino wistar rats; aspartame; ethanolic extract *Moringa oleifera* seed; N-hexane extract *Moringa oleifera* seed.

1. INTRODUCTION

Ileum: The second part of the small intestine, the jejunum, begins at the duodenojejunal flexure where the gastrointestinal tract resumes an intraperitoneal course. The third part of the small intestine, the ileum, ends at the ileocecal junction, the union of the terminal ileum and the cecum. Together, the jejunum and ileum are 6 to 7 m long, the jejunum constituting approximately two fifths and the ileum approximately three fifth of the intraperitoneal section of the small intestine [1]. Most of the jejunum lies in the left upper quadrant (LUQ) of the infracolic compartment, whereas most of the ileum lies in the right lower quadrant (RLQ). The terminal ileum usually lies in the pelvis from which it ascends, ending in the medial aspect of the cecum. Although no clear line of demarcation between the jejunum and ileum exists, they have distinctive characteristics that are surgically important. The mesentery is a fan-shaped fold of peritoneum that attaches the jejunum and ileum to the posterior abdominal [1].

Histologically, the mucosa is lined by simple columnar epithelium comprising enterocytes and goblet cells. Underneath lies a connective tissue layer (lamina propria) and a muscle layer (lamina muscularis mucosae). Compared to the rest of the small intestine the circular folds are rather flat and the villi relatively short. The submucosa contains blood vessels, lymph nodes and the Meissner's plexus. The muscularis consists of an inner circular and outer longitudinal muscle layer. The ileum is entirely covered by serosa from the outside. It is made up of simple squamous epithelium and a connective tissue layer underneath (lamina propria serosae). A characteristic feature of the ileum is the Payer's patches lying in the mucosa. It is an important part of the GALT (gut-associated lymphoid

tissue). One patch is around 2 to 5 centimeters long and consists of about 300 aggregated lymphoid follicles and the parafollicular lymphoid tissue. The dome-like bulge above one follicle is called dome area. M cells (microfold cells) are found in the dome epithelium which are counted among the FAE cells (follicle-associated epithelial cells). Their function is to pick up antigens from the intestinal lumen and transport them to the antigen-presenting cells (APC) [2].

Aspartame is an, intense sweetener which is almost 180 to 200 times sweeter than sucrose, with a respective low calorific value [3]. Aspartame is widely used in more than 6000 products worldwide with a huge commercial outcome under many brand names [4]. Aspartame is very much popular owing to its reduced costs, low caloric intake, attractive advertisements and assurance to contribute in weight management [5]. The popularity of aspartame among consumers lies down within the problems associated with sucrose consumption [6]. Aspartame helps in limiting the sucrose intake in the form of substituting sugar and releases very low amount of energy respectively. It is metabolized more slowly than sucrose, allowing blood sugar levels to remain more stable over time. Individuals with reactive hypoglycemia produce an excess of insulin after quickly absorbing glucose into the bloodstream [7]. This causes their blood glucose levels to fall below the amount needed for physiological function. Like diabetic, high glycemic food avoidance often force them to choose artificial sweeteners as an alternative [8]. For these reasons aspartame increasingly introduced into commonly consumed foods such as diets sodas, cereals, and sugar-free desert, yoghurt, chewing gums, mouth fresheners nutritional supplements are being recommended for weight loss and for individuals suffering from glucose intolerance

and type 2 diabetes mellitus [9]. Aspartame is harmful and toxic to human beings, its toxicity is due to its corrosive properties, which can damage internal organs. It tends to accumulate in the ileum, which can lead to Cohn's disease and ulcerative colitis [8].

M. oleifera belongs to a monogeric family of shrubs and tree, Moringaceae. The plant possesses many valuable properties of great scientific interest. These include the high protein content of the leave twigs and stems, the high protein and oil content of the seeds, the large number of unique polypeptides in the seeds that can bind to many moieties; the presence of growth factors in the leaves [10,11]. *M. oleifera* is a fairly large tree native to north India. Almost all part of the tree is eaten or used as ingredients in traditional herbal medicines. They are strong natural antioxidants; they also display other medicinal properties like anti-inflammatory, chemo preventive [12]. *M. oleifera* leaves have essential amino acids, including the sulphur-containing amino acids in higher levels [13], than those recommended by the Food and Agricultural Organisation [14], and with pattern similar to those of soya bean seeds [10]. *Moringa oleifera* leaves are always available throughout the whole year [15]. *M. oleifera* is widely used for its nutritional and medicinal properties. It is packed with antioxidants, substances that can protect cells from damage and boost the immune system; though studies have also indicated that *M. oleifera* at about 2000 mg/kg is toxic [16] and we intend not to reach this level in our research.

Many studies on *M. oleifera* had been carried out, but there is paucity of data on studies making use of *M. oleifera* seed via its ethanolic and n-Hexane extraction. Hence, this study aims: to determine the effect of aspartame on the histoarchitecture of ileum of adult male Albino Wistar rats; to determine the effect of aspartame and *M. oleifera* seed extract on the body weight of adult male Albino Wistar rats; to evaluate the effect of ethanolic extract of *M. oleifera* seed on ileum histology following aspartame administration in adult male Albino Wistar rats; and to evaluate the effect of n-Hexane extract of *M. oleifera* seed on ileum histology following aspartame administration in adult male Albino Wistar rats.

2. METHODOLOGY

Twenty seven adult male Albino Wister rats were used for the study. They were fed pelletized

grower mash and clean drinking water ad libitum. The rats were kept under standard room temperature. They were housed in nine wooden cages, measuring about 18 by 12 inches with wire gauze covers and sawdust as beddings. The animals were handled in compliance with applicable guidelines for the care and use of laboratory animals [17].

The *M. oleifera* pods were purchased from the market. The pods were broken and the seeds removed and well ground using a manual grinder. The Soxhlet method of extraction was used. Typically, Soxhlet extraction is used when the desired compound has a limited solubility in a solvent and the impurity is insoluble in that solvent. It allows for unmonitored and unmanaged operation while efficiently recycling a small amount of solvent to dissolve a large amount of material. 80% of ethanol was added to 500 g of the ground seed; 80% of N-hexane was added to a separate 500 g of the ground seed. Both extracts were gotten by filtration, stored in a glass beaker, covered with foil and placed in the fridge to preserve the efficacy of the extract [18].

The aspartame was also gotten from the market. The aspartame was weighed using an electric weighing balance in the laboratory. The aspartame used was 1.0 g and was dissolve in 50 ml of distilled water. The dissolved aspartame was administered to the rats according to their required dose based on weight. This procedure was carried out daily for 28 days. Group A (control), were administered distilled water; group B, given 0.4 ml (low dose) aspartame; group C, given 1.5 ml (high dose) aspartame; group D1, given 0.6 ml (low dose) aspartame for the first three weeks followed by 1.5 ml (low dose) ethanolic extract of *M. oleifera* seed on the fourth week; group D2 given 0.5 ml (low dose) aspartame for the first three weeks followed 1.30 ml (low dose) n-hexane extract of *M. oleifera* seed on the fourth week; group E1, given 1.5 ml (high dose) aspartame for the first three weeks and on the fourth week 2.5 ml (high dose) ethanolic extract of *M. oleifera* seed; group E2, given 1.5 (high dose) aspartame for the first three weeks and on the fourth week 3.0 ml (high dose) n-hexane extract of *M. oleifera* seed; group F1 given 1.4 ml (high dose) aspartame followed by 2.8 ml (high dose) ethanolic extract of *M. oleifera* seed for four weeks; group F2, given 1.3 ml (high dose) aspartame followed by 2.5 ml (high dose) n-hexane extract of *M. oleifera* seed for four weeks.

Weight measurement of rats was taken once a week throughout the twenty eight days duration of the study. Data were expressed as mean \pm standard error of mean (M \pm SEM) and subjected to one-way analysis of variance (ANOVA). At 95 % confidence interval, *P* is significant (*P* < 0.05).

Following anaesthetization, 1000 ml of normal saline was perfused to clear the blood impurities, the ileum harvested and fixed in 10 % buffered formalin. Hematoxylin and Eosin (H&E) staining technique was adopted for routine histological procedure. The tissue processing involved the following stage: dehydration, clearing, infiltration, embedding, sectioning (microtomy), staining and mounting. The processed tissues were then subjected to microscopy. The Processed tissues were viewed under the light microscope and photomicrographs from control and experimental groups were obtained using the microscope's camera attached to the computer.

3. RESULTS

3.1 Phytochemical Analysis of *M. oleifera*

The extract from the *M. oleifera* was screened for the presence of secondary metabolites using standard methods [19]. The result is shown in the Table 1.

3.2 Comparison of Changes in Body Weight of Adult Male Albino Wistar Rats

The result of the changes in body weight following the administration of aspartame and *Moringa oleifera* seed extract for twenty- eight days is shown in Table 2. There was progressive increase in the weight of both control and experimental rats, contrary to the widely held belief that artificial sweeteners, example, aspartame, are of low calories, hence, implicated in weight reduction and maintenance.

Table 1. Phytochemical results [17]

Test	Observation	Inference
Alkaloids		
1. Dragendof	Red precipitate observed	++
2. Mayer	Red precipitate observed	++
3. Tannin	Bluish-black coloration observed	+++
4. Saponin	Persistent frothing observed	++
5. Flavenoid	Orange precipitate observed	++
Cardiac glycoside		
1. Salkawski	Reddish-brown ring	+++
2. KellLillirin	Brown ring observed at the interphase	++
3. Lieberman	Violet ring observed at the interphase	++

Key: - = absent, + = slightly present, ++ = moderately present, +++ = heavily present

Table 2. Comparison of Changes in Body Weight of Adult Male Albino Wistar Rat in Grams (gm)

Groups	Week 1	Week 2	Week 3	Week 4
A	205.50 \pm 6.50	220.50 \pm 8.50	313.00 \pm 8.00	313.00 \pm 7.00
B	143.00 \pm 5.13	144.50 \pm 5.50	238.00 \pm 9.00	242.00 \pm 10.00
C	182.33 \pm 1.20	192.33 \pm 1.45	288.00 \pm 3.21	292.33 \pm 4.18
D1	182.00 \pm 9.50	188.67 \pm 10.68	286.33 \pm 13.45	289.00 \pm 14.01
D2	151.67 \pm 1.20	161.33 \pm 1.45	254.67 \pm 4.67	255.67 \pm 4.41
E1	144.33 \pm 3.84	155.67 \pm 2.33	244.67 \pm 6.39	245.33 \pm 7.31
E2	174.67 \pm 4.98	191.00 \pm 6.51	282.67 \pm 6.94	284.00 \pm 9.07
F1	179.33 \pm 8.69	197.00 \pm 10.82	281.33 \pm 10.73	276.67 \pm 8.97
F2	154.67 \pm 4.81	171.33 \pm 4.37	253.00 \pm 3.51	248.67 \pm 3.84
	F = 13.50	F = 12.72	F = 9.60	F = 9.12
	P = 0.000	P = 0.000	P = 0.000	P = 0.000

Values are expressed as mean \pm standard error of mean (S \pm SEM). At 95% confidence interval, *P* is significance (*P* < 0.05)

3.3 Hematoxylin and Eosin (H&E) Method for General Demonstration of Ileum

Histological findings revealed that aspartame both in low and high doses has disruptive effects on the histoarchitecture of ileum; and only high dose ethanolic extract of *Moringa oleifera* seed has the capacity to ameliorate the effect. The

figures adopted as low and high doses were calculated and determined based on weight of the rats. The figures representing dosage of aspartame consumed were implicated in the inflammation of the surface epithelium of the ileum and atrophy of the intestinal villi and lamina propria, which predisposes to apoptosis.

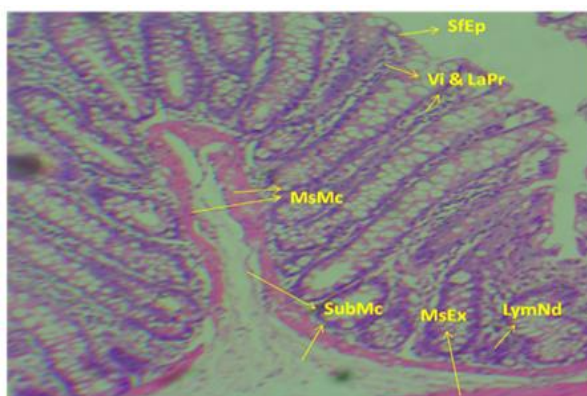


Fig. 1. (H&E method, X100)

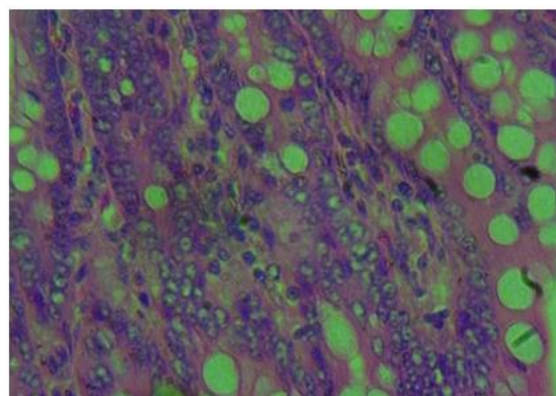


Fig. 2. (H&E method, X400)

Figs. 1 & 2. Transverse section of the ileum of adult male Albino Wister rat given distilled water Group A (Control). (H&E method). Section revealed some features typical of normal ileum, Surface epithelium (SfEp), Villi and Lamina propria (Vi&LaPr), Lymphoid nodule (Payers patch) (LymDd). Muscularis externa (MsEx), Serosa (Srs), Muscularis mucosa (MsMc), Submucosa (SubMc)

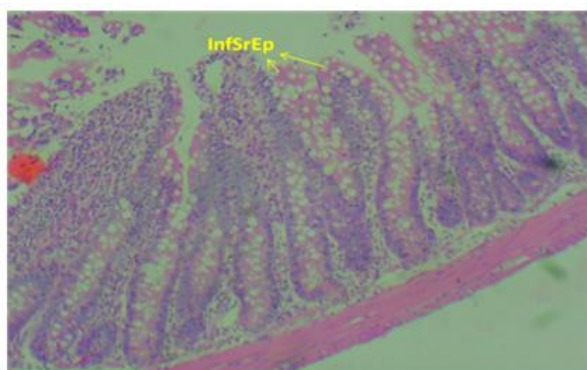


Fig. 3. (H&E method, X100)

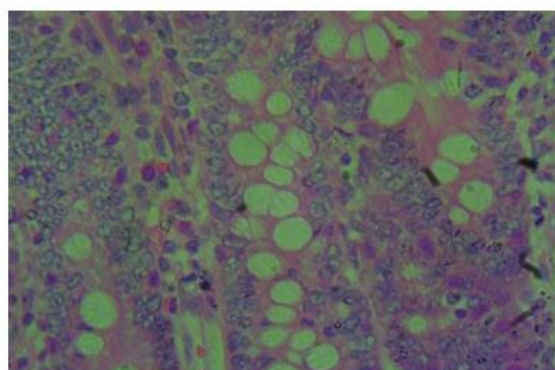


Fig. 4. (H&E method, X400)

Figs. 3 & 4. Transverse section of the ileum of adult male Albino Wister rat given 0.4 ml (low dose) aspartame for 4 weeks (28 days) Group B. (H&E method, X100). Section revealed: Inflammation of Surface epithelium (InfSfEp). Inference: Slightly affected

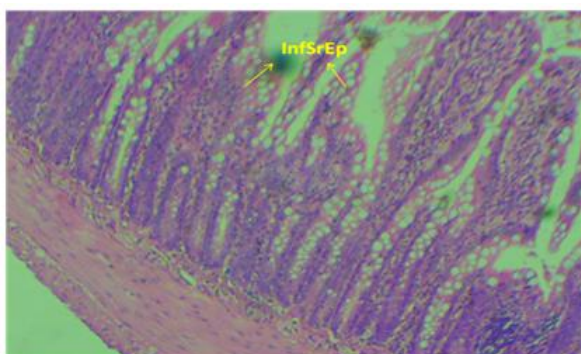


Fig. 5. (H&E method, X100)

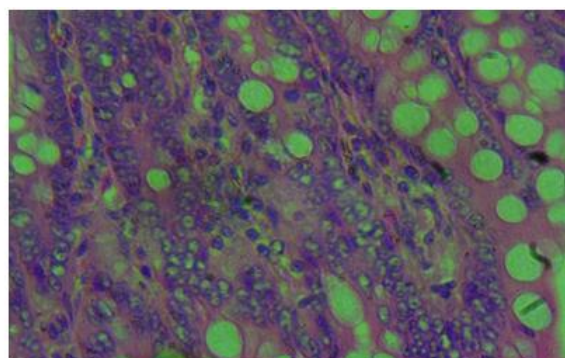


Fig. 6. (H&E method, X400)

Figs. 5 & 6. Transverse section of the ileum of adult male Albino Wistar rats given 1.5 ml (high dose) aspartame for 4 weeks (28 days). Group C. (H&E method). Section revealed: Inflammation of Surface epithelium (InfSfEp). Inference: Slightly affected

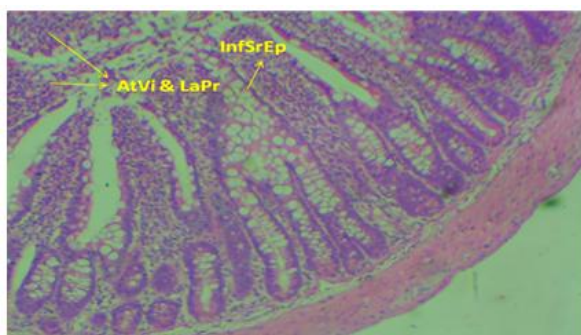


Fig. 7. (H&E method, X100)

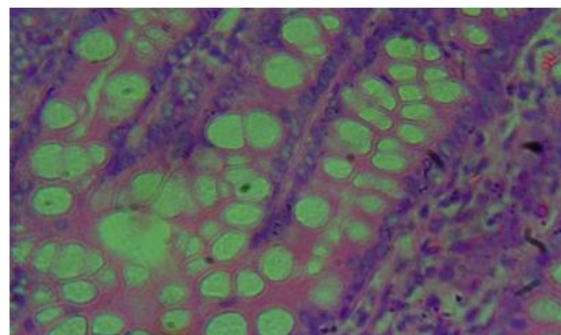


Fig. 8. (H&E method, X400)

Figs. 7 & 8. Transverse section of the ileum of adult male Albino Wister rats given 0.6 ml (low dose) aspartame for the first 3 weeks and on the fourth week, 1.50 ml (low dose) ethanolic extract of *Moringa oleifera* seed only. Group D1. (H&E method, X100). Section revealed. Inflammation of Surface epithelium (InfSfEp), Atrophy of the Villi and Lamina propia (AtVi&LaPr). Inference: Severely affected

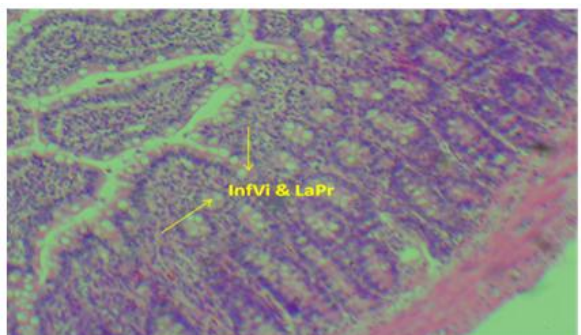


Fig. 9. (H&E method, X100)

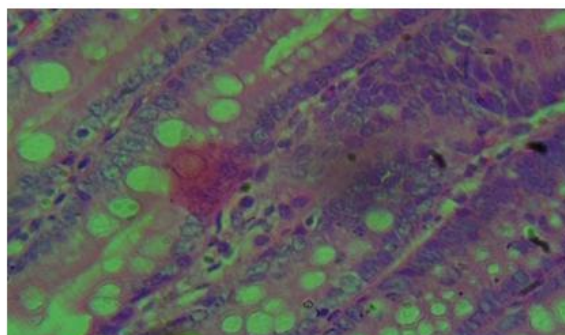


Fig. 10. (H&E method, X400)

Figs. 9 & 10. Transverse section of the ileum of adult male Albino Wistar rats given 0.5 ml (low dose) aspartame for the first 3 weeks and on the fourth week, 1.30 ml (low dose) n-Hexane extract of *Moringa oleifera* seed only. Group D2. (H&E method, X100). Sections revealed. Inflammation of villi and lamina propria (InfVi&LaPr). Inference: Slightly affected




Fig. 11. (H&E method, X100)

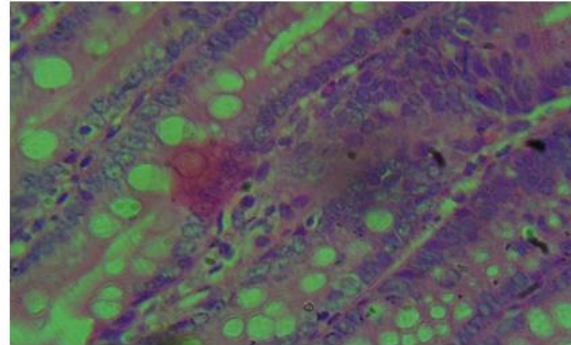


Fig. 12. (H&E method, X400)

Figs. 11 & 12. Transverse section of the ileum of adult male Albino Wistar rats given 1.3 ml (high dose) aspartame for the first 3 weeks and on the fourth week, 2.5 ml (high dose) ethanolic extract of *Moringa oleifera* seed only. Group E1. (H&E method, X100). Section revealed intact: Surface epithelium (SfEp), Villi and Lamina propria (Vi&LaPr). Inference: Not affected

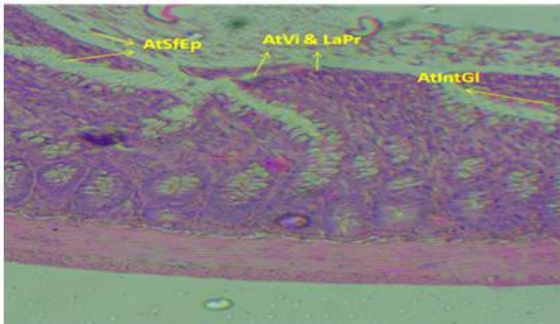


Fig. 13. (H&E method, X100)

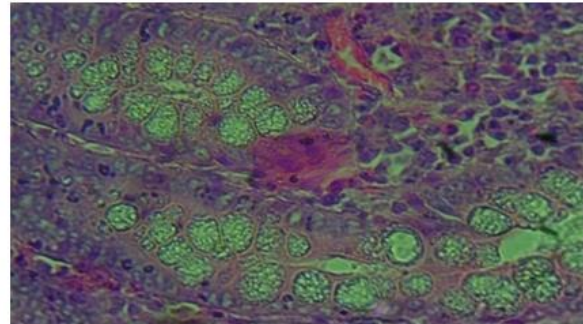


Fig. 14. (H&E method, X400)

Figs. 13 & 14. Transverse section of the ileum of adult male Albino Wistar rats given 1.5 ml (high dose) aspartame for the first 3 weeks and on the fourth week, 3 ml (high dose) n-Hexane extract of *Moringa oleifera* seed only. Group E2. (H&E method, X100). Section revealed: Atrophy of villi and lamina propria (AtVi&LaPr), atrophy of surface epithelium (AtSfEp) and atrophy of intestinal glands (AtIntGI). Inference: Severely affected

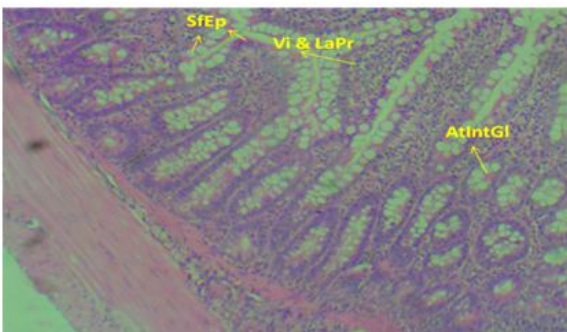


Fig. 15. (H&E method, X100)

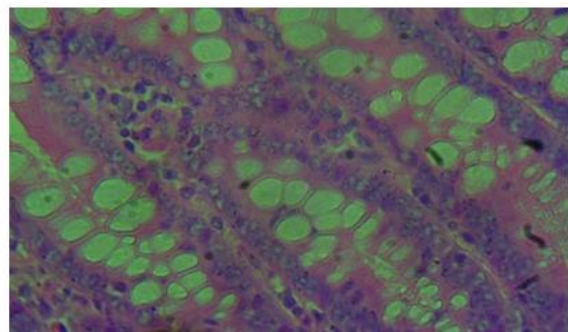


Fig. 16. (H&E method, X400)

Figs. 15 & 16. Transverse section of the ileum of adult male Albino Wistar rats given 1.4 ml (high Dose) aspartame followed by 2.8 ml (high dose) ethanolic extract *Moringa oleifera* seed for four weeks. Group F1. (H&E method, X100). Section revealed intact: Villi and lamina propria (Vi&LaPr), Surface epithelium (SfEp) and Intestinal glands (IntGI) Inference: Unaffected

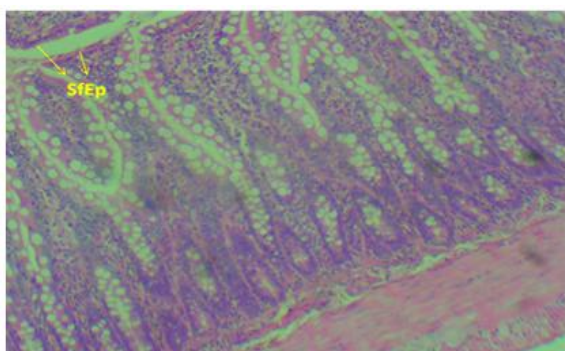


Fig. 17. (H&E method, X100)

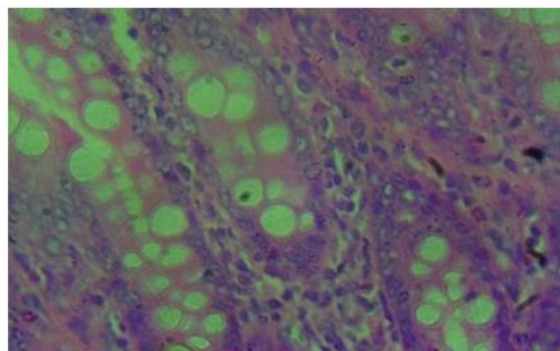


Fig. 18. (H&E method, X400)

Figs. 17 & 18. Transverse section of the ileum of adult male Albino Wistar rats given 1.3ml (high dose) aspartame followed by 2.5 ml (high dose) n-Hexane extract *Moringa oleifera* seed for four weeks. Group F2. (H&E method, X100) Section revealed: Slight inflammation of Surface epithelium (InfSfEp). Inference: Slightly affected

4. DISCUSSION OF FINDINGS

The near arithmetic progression in weight from week one to week three observed in groups A to E2, in addition to the increase in weight at geometric pace observed from week three to four were due to inexplicable reason(s). The idea being that there are reports in literature that food sweetened with aspartame results in a significant decrease in bodyweight. Moreover, according to [20], foods and drinks sweetened with aspartame is an effective way to maintain and lose weight. This notion of [20] and colleagues, was corroborated by the work of, [21], whose study suggests possible advantages to supplementing a diet with aspartame sweetened foods as part of a multidisciplinary weight loss program. Though, [21] and colleagues were of the view that the small sample size of their work prohibits definitive conclusions, and cannot provide the protocol for a larger, outpatient clinical trial. Be that as it may, our findings is consistent with the report of [22]; who reported that Consumption of sweeteners resulted in significantly increased body weight in their research article titled: effects of artificial sweeteners on body weight, food and drink intake. Also in our findings, the same pattern of increase was observed in groups F1 and F2 only in weeks one to three, but in weeks three to four, there was observed abrupt decrease in weight due to reason(s) not well understood. The findings in this research article is also in line with the outcome of experiment conducted by, [23] Qing Yang, in which it was stated that "Why people often choose "diet" or "light" products to lose weight, research studies

suggest that artificial sweeteners may contribute to weight gain".

The fact that aspartame causes cellular damage in some tissues and organs in the body, serves as a pointer to the probability of aspartame having a disruptive properties on the histoarchitecture of the ileum. Histological results as evidenced in the outcome of research work: Acute Impact of the Artificial Sweetener Aspartame on the Ultrastructures of Hepatocyte in Mice, by [24], portrayed cellular changes in the hepatic tissues which were proportional with the increased doses. The result suggested that the hepatocytes developed fatty droplets in the cytoplasm of almost all cells, loss of nuclei and necrosis. Moreover, [25] and colleagues, in their work suggested that "Aspartame generated liver injury and fibrosis. It also decreased the activity of antioxidant enzymes and increased the levels of lipid peroxidation, thus, probably, triggering inflammation and cell death through the induction of protein 53 (p53)". Our findings is consistent with the work of: [26], which suggested that Artificial Sweeteners disrupt tight junctions and barrier Function in the intestinal epithelium through activation of the sweet taste receptor, T1R3. They went further to suggest that "The breakdown of the intestinal epithelial barrier and subsequent increase in intestinal permeability can lead to systemic inflammatory diseases and multiple-organ failure".

In addition to the above, experiments using humans and mice have suggested that the consumption of artificial sweeteners in the diet is linked with the dysbiosis of gut microbiota and

an associated increase in levels of endotoxins secreted from these bacteria, such as lipopoly saccharide (LPS), [27,28]. They were of the view that, LPS released from the gut microbiota is linked to an increase in intestinal permeability, [29].

5. CONCLUSION

Deductions from the histological findings revealed that aspartame both in low and high doses has disruptive effects on the histoarchitecture of ileum and high dose ethanolic extract of *M. oleifera* seed has the capacity to ameliorate the effects. Hence, caution is needed in aspartame consumption.

CONSENT

It is not applicable.

ETHICAL APPROVAL

As per international standard or university standard written ethical approval has been collected and preserved by the author(s).

COMPETING INTERESTS

Authors have declared that no competing interests exist.

REFERENCES

- Moore KL, Arthur FD, Anne MRA. Clinically Oriented Anatomy; 2014.
- Alexandru, Sieroslawska. Histology of the Ileum. Histology of kenhub – Wurznstrabe 154a; 2017.
- Eroschenko VP. Di Fiore's atlas of histology with functional correlations. 10th Ed; 2005.
- Henkel J. Sugar Substitues Americans ept for sweetness and lit. American Journal of food Consumption. 2007; 3(6):12-16.
- Abu Taweel GM. Effect of monosodium glutamate and aspartame on the behaveoural and blochemicalparmaters of albino rice. American Journal Biotech. 2016;15(15):601-612.
- Tandel KR. Sugar substirues.Health controversy over perceived benefits. Journal Pharmacol Pharmacology. 2011; 2(4):236-243.
- Bellisle F, Altenburg de Assis Felix B, Prexlosi P, Galan P, Guy Grand B, Drewpiuwski. Low-energy substitutes for sugars and fats in the human diet: Impact on Nutritional regulation. Neuroscience Behaviour. 2007;18-197-205.
- Bentleg E, Mackee M. A qualitative investigation into general practitioner views on prescribing sugar free medicines for children. Journal of Health Education. 2015;8:819.
- Portela GS, Azoubel R, Battgaliay F. Effect of Aspartame on mental-petal and placental weight. International Journal of Morphology. 2014;25:549-554.
- Foidl N, Becker K. What development potential for Moringa products? A conference onon the potential of *Moringa oleifera* for Agricultural and industrial uses. October 20th – November 2nd 2001. Dar Es Salaam; 2001.
- Oduro I, Ellis WO, Owusu D. Nutritional Potential of two leafy Vegetables: *Moringa oleifera* and Ipomoea batatas leaves. Scientific Research and Essay. 2008;3(2): 57-60.
- Morales FM, Cervantes EM, Espinoza Mai, Martinez OHA. Nutriflonal and Blochemical Effect of Aspartame Intake in rat under experimental diet. Journal of Biology and Agriculture Science. 2015; 3(3):298-306.
- Makkar HPS, Becker K. Nutrients and Antiquality Factors in Different Morphological Parts of *Moringa oleifera* Tree. J. Agric Sci., Cambridge. 1997;128: 311-322.
- FAO. Energy and Protein Requirments. Report of a Joint FAO/WHO/UNU Expert Consultation Meeting Series, N.724, Geneva, Switzerland; 1985.
- Price ML. Te Moringa Tree, ECHO Technical Note (revised 2000 by Kristine Davis); 1985.
- Miltan MJ, Agid V, Brune M, Carter CS. Cognitive Dystunction in Pschyatric also- ders characteristics, lauses and the quest for improved therapy. National Drug Discovery. 2012;141-145.
- Chiedozie MC, Donatus EG, Amoo-Tella SY, Enang UA. *Moringa oleifera* seed actions following aspartame consumption: A systematic evaluation of the large intestine. Sch Int J Anat Physiol. 2022; 5(1):15-24.
- Soxhlet F. Die Gewichtsanalytische Bestimmung Des Milchfettes,

- Polytechnisches, Dingler's Polytechnis-Chem Journal. 1879;23:232– 461.
19. Odebibi OO, Sofowora EA. Phytochemical Screening of Nigerian Medicinal Plants II. Lloydia. 1978;41:234-236.
 20. Hunty, De La, Gibson S, Ashwell M. A review of the effectiveness of aspartame in helping with weight control. Nutrition Bulletin. 2005;31(2):115-128. DOI: 10.1111/j.1467-3010.2006.00564.x
 21. Kanders BS, Lavin IPT, Kowalchuk MB, Greenberg I, Blackburn GL. An evaluation of the effect of aspartame on weight loss. Appetite. 1988;11(Suppl 1):73-84.
 22. Polyák E, Gombos K, Hajnal B, Bonyár-Müller K, Szabó Sz, Gubicskó-Kisbenedek A, Marton K, Ember I. Effects of artificial sweeteners on body weight, food and drink intake. Acta Physiologica Hungarica. 2010;97(4):401–407. DOI: 10.1556/APhysiol.97.2010.4.9
 23. Qing Yang. Neuroscience. Gain weight by “going diet?” Artificial sweeteners and the neurobiology of sugar cravings. Yale J Biol Med. 2010;83(2):101–108.
 24. Norah S, Johani A, Bazzaz AA. Acute Impact of the Artificial Sweetener Aspartame on the Ultrastructures of Hepatocyte in Mice; 2019. DOI: 10.4236/abb.2019.106012
 25. Isabela AF, Caroline AB, Isabel TC, Sergio RP, Marcelo DV, Maria IR, Maria AP, Salvador P. Long-term aspartame administration leads to fibrosis, inflammation activation, and gluconeogenesis impairment in the liver of mice. Biology. 2021;10(2):82. Available:https://doi.org/10.3390/biology10020082
 26. Aparna S, Oluwatobi O, Zaynub G, Benjamin F, Joanne M, Havovi C. Artificial Sweeteners Disrupt Tight Junctions and Barrier Function in the Intestinal Epithelium through Activation of the Sweet Taste Receptor, T1R3. Nutrients. 2020; 12(6):862. DOI: 10.3390/nu12061862
 27. Suez J, Korem T, Zeevi D, Zilberman-Schapira G, Thaiss CA, Maza O, Israeli D, Zmora N, Gilad S, Weinberger A, et al. Artificial Sweeteners Induce Glucose Intolerance by Altering the Gut Microbiota. Nature. 2014;514:181–186. DOI: 10.1038/nature13793.
 28. Nettleton JE, Reimer RA, Shearer J. Reshaping the Gut Microbiota: Impact of Low Calorie Sweeteners and the Link to Insulin Resistance? Physiol. Behav. 2016; 164:488–493. DOI: 10.1016/j.physbeh.2016.04.029.
 29. Guo S, Nighot M, Al-Sadi R, Alhmod T, Nighot P, Ma TY. Lipopolysaccharide regulation of intestinal tight junction permeability is mediated by TLR4 signal transduction pathway activation of FAK and MyD88. J. Immunol. 2015;195:4999–5010. DOI: 10.4049/jimmunol.1402598.

© 2022 Mbadugha et al.; This is an Open Access article distributed under the terms of the Creative Commons Attribution License (<http://creativecommons.org/licenses/by/4.0>), which permits unrestricted use, distribution, and reproduction in any medium, provided the original work is properly cited.

Peer-review history:

The peer review history for this paper can be accessed here:
<https://www.sdiarticle5.com/review-history/88096>