

# Enteropathica Acrodermatitis Complicated by Necrotising Fasciitis in an Infant Admitted to the Paediatric Emergency Department of the Gabriel Touré University Hospital

Aichata Keita<sup>1\*</sup>, Bory Traoré<sup>2</sup>, Adama Dembélé<sup>2</sup>, Rokiatou Diarra<sup>1</sup>, Mariam Diarra<sup>3</sup>, Elmouloud M. Cissé<sup>2</sup>, Mariam Kané<sup>2</sup>, Bakary Coulibaly<sup>1</sup>, Hawa Konaré<sup>2</sup>

<sup>1</sup>Reference Health Center of the Commune VI, Bamako, Mali

<sup>2</sup>Department of Paediatrics CHU Gabriel Touré, Bamako, Mali

<sup>3</sup>Bamako Dermatology Hospital, Bamako, Mali

Email: \*aichatakeita522@gmail.com

**How to cite this paper:** Keita, A., Traoré, B., Dembélé, A., Diarra, R., Diarra, M., Cissé, E.M., Kané, M., Coulibaly, B. and Konaré, H. (2023) Enteropathica Acrodermatitis Complicated by Necrotising Fasciitis in an Infant Admitted to the Paediatric Emergency Department of the Gabriel Touré University Hospital. *Open Journal of Pediatrics*, 13, 831-837.

<https://doi.org/10.4236/ojped.2023.136091>

**Received:** September 20, 2023

**Accepted:** November 5, 2023

**Published:** November 8, 2023

Copyright © 2023 by author(s) and Scientific Research Publishing Inc.

This work is licensed under the Creative Commons Attribution International License (CC BY 4.0).

<http://creativecommons.org/licenses/by/4.0/>



Open Access

## Abstract

Acrodermatitis enteropathica is a rare autosomal recessive genetic disorder characterised by periorificial dermatitis, alopecia and diarrhoea. It is caused by a mutation in the gene that codes for a membrane protein that binds zinc. We report a case in a 7-month-old girl, admitted with altered general condition and scaly, pustular erythematous lesions, initially located in the occipital and cervical regions, and secondarily inguinal and on the knees. Management and outcome in this patient? Genetic assay was not available to confirm this rare genetic disease. A delay in establishing the diagnosis and a disastrous outcome did not save the patient despite the administration of zinc.

## Keywords

Enteropathica Acrodermatitis, Necrotizing Fasciitis, Infant

## 1. Introduction

Acrodermatitis enteropathica is a rare and severe autosomal recessive genetic disorder in which the intestinal absorption of zinc is impaired.

Zinc is an essential trace element required by around a hundred enzymes and plays an important role in nucleic acid metabolism [1] [2]. The SLC39A4 gene located on chromosome 8q24.3 encodes the human zinc/iron-regulated transporter protein 4 (ZIP4) and plays an important role in the transmembrane transport and absorption of zinc [3] [4]. This protein is highly expressed in en-

terocytes of the duodenum and jejunum and is secreted in breast milk. Gene mutation can lead to poor zinc absorption and subsequent deficiency [5]. Acrodermatitis enteropathica occurs in 1/500,000 live infants [6]. There is no predilection for gender or race [3] [6], with formula-fed infants generally presenting with symptoms between the tenth and fourth week of life [5], while breast-fed infants present with symptoms a few days to a few weeks after weaning. Prevalence is estimated at between 1% and 3% in the United States and up to 20% in developing countries [5]. In Brazil, the frequency is unknown, but it is estimated that 1.5 million people are affected [7].

The classic clinical manifestations of acrodermatitis enteropathica are characterised by an eczematous triad (erosive dermatitis, symmetrical acral and periorificial dermatitis), alopecia and diarrhoea. Paronychia, onychodystrophy, angular stomatitis, cheilitis, conjunctivitis and photophobia may also occur [8] [9]. The disorders progress with difficulties relating to: weight gain, growth retardation, neuropsychological disorders, anaemia, anorexia, and marked difficulty in healing wounds.

Zinc deficiency alters immunity, contributing to a high susceptibility to fungal and bacterial infections, which can trigger serious systemic scenarios and high mortality rates in developing countries [10] [11].

Management of this condition is based on oral zinc sulfate. It is administered in doses that need to be increased during the growth acceleration phase. There is no consensus on the dose of zinc sulfate, but most authors recommend an initial dose of 5 to 10 mg/kg/day, with maintenance doses of 1 to 2 mg/d to be maintained for life.

The aim of this study is to report a clinical case of acrodermatitis enteropathica in an infant discovered by chance.

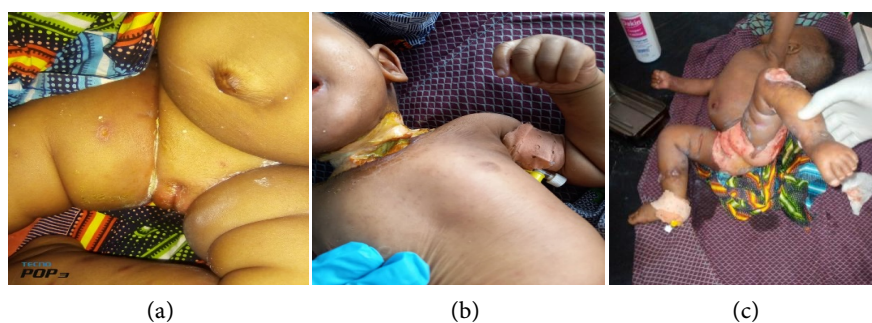
## 2. Patient and Observation

This is a 7-month-old girl, born at term (39 SA + 3 days) with a birth weight of 2150 gm, from a non-consanguineous couple and with no family history of acrodermatitis enteropathica or allergy. Her diet consists of breast milk plus commercial infant milk. She was taken by her parents to the Paediatric Emergency Department of the CHU Gabriel Touré for scaly and pustular erythematous lesions that had been evolving for 15 days. The parents' history revealed chronic glairo-liquid diarrhoea and lesions initially located in the inguinal region (**Figure 1(a)**, **Figure 1(b)**) and on the buttocks (**Figure 1(c)**).

At this stage, the patient was receiving various topical treatments (antiseptic, antimycotic, dermocorticoids). When the treatment failed and other similar lesions reappeared on the neck and left knee, the parents finally decided to consult a hospital.

The physical examination on admission revealed:

- Poor general condition, weight 6.7 kg (??percentage of expected), height 66 cm (% of expected??), (weight/height ratio = +1 Z score, corresponding to good nutritional status), temperature 35°3, heart rate 168 beats/min, respiratory



**Figure 1.** (a) Initial lesion before Hospitalization of the Patient; (b) Initial lesion at the inguinal level; (c) Initial lesion in the gluteal region.

rate 68 cycles/min and oxygen saturation in ambient air 97%. There was also an almost total absence of hair (partial alopecia)—be specific with the type of alopecia the patient has—is it totalis, partialis, androgenetic, scarring, universalis etc?????

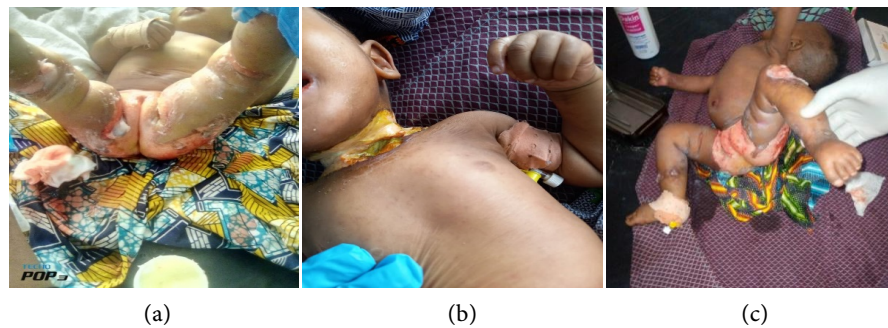
- Moderate conjunctival pallor, signs of dehydration (sunken eyes, slowly receding skin folds) and large, multifocal necrotic ulcerations on the neck, right inguinal region, buttocks and labial perlage (**Figures 2(a)-(c)**).

The diagnosis of staphylococcal dermo-epidermolysis was made and all treatment was directed towards this pathology for 15 days, combining (antibiotics, nutritional management) without any notable improvement. However, some additional tests were ordered, the results of which revealed:

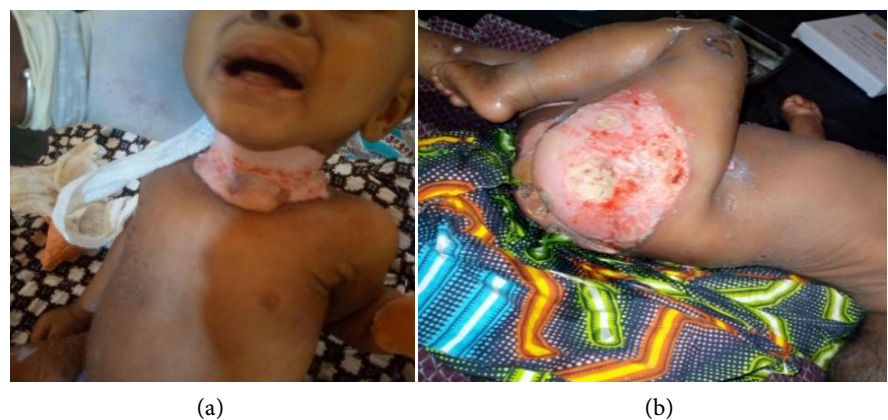- A very low plasma zinc level (8 µg/dl for a normal value of 70 to 120 µg/dl);
- Alkaline phosphatase (88.72 IU/L compared with a normal value of 100 - 200 IU/L);
- IgG (3.64 g/dl for a normal value of 2.5 - 5 g/dl), IgM (0.39 g/dl for a normal value of 0.15 - 1), IgA (0.08 g/dl for a normal value of 0.01 - 0.045);
- The CBC showed anaemia of 9 g/dl, microcytic and hypochromic;
- The mother's plasma zinc was normal (20.7 µmol/l compared with a normal value of 9 - 22 µmol/l);
- HIV serology was negative;
- swabbing of lesions taken from the knee with cytobacteriological study found *Klebsiella pneumoniae* (Gram negative bacillus) and *Candida albicans*;
- Zinc levels in breast milk could not be measured for technical reasons.

In the light of these results, the diagnosis of Acrodermatitis Enteropathica (AE) complicated by Necrotising Fasciitis was made. The treatment consisted of zinc sulfate at 3 mg/kg/day, antibiotic therapy adapted to germs with sensitivity (Amikacin) for *Klebsiella pneumoniae* and , antifungal treatment (Fluconazole) for *Candida albicans*; necrosectomy + wound trimming (**Figure 3(a)**, **Figure 3(b)**) and nutritional support according to the department's protocol.

The course was marked by a progressive deterioration in the patient's clinical condition (weight loss of up to 5.6 kg, altered nutritional status), sepsis, persistent diarrhoea and multifocal necrotic skin ulcers, culminating in the patient's death 57 days after the start of zinc sulphate supplementation.



**Figure 2.** (a) Deepening ulcerations with ragged to fibrinous margins at the inguinal level before Administration of zinc sulfate; (b) Sore ulcerations in the neck before administration zinc sulfate; (c) Deepening ulcerations edges and fibrinous base in the buttocks before administration of zinc sulfate.



**Figure 3.** (a) Necrotic ulceration on the neck 15 days after administration of Zinc sulfate; (b) Necrotic ulceration in the buttocks 15 days after administration zinc sulfate.

### 3. Ethical Considerations

Informed consent was obtained from the parents prior to writing this manuscript after a detailed explanation of the importance we attach to this rare case in our context. All images were provided by the parents.

### 4. Discussion

Zinc is a trace element essential for the proper functioning of all cells and plays an important role in the metabolism of proteins, carbohydrates and vitamins. It is a cofactor in many metal enzymes such as alkaline phosphatase, alcohol dehydrogenase, RNA polymerase and many digestive enzymes [7]. Zinc deficiency can be acquired or inherited. There are many acquired causes of zinc deficiency including prematurity, low birth weight, deficiency in breast milk, exclusive parental mutation, malabsorption syndromes such as Crohn's disease and Coeliac disease, diets low in calcium and phytates, Acquired Immunodeficiency Syndrome and Kwashiorkor [6].

Hereditary zinc deficiency is caused by an autosomal recessive mutation of SLC39A4, a gene on chromosome Aq24.3, which results in partial or total defi-

ciency of the zinc transport protein ligand protein 4 (ZIP4) [12].

The clinical manifestations of acquired and hereditary zinc deficiency are similar and consist of 3 essential symptoms: periorificial dermatitis, alopecia and diarrhoea, which occur in only 20% of patients [13], as was the case in our patient. The disease begins with symmetrical erythematous, scaly or eczematous lesions, sometimes with vesiculobullous or pustular lesions located around the perioral, anogenital and acral areas. In our patient, the lesions were erythematous, scaly and pustular, initially localised to the inguinal region and buttocks, followed by large, multifocal necrotic ulcerations around the neck, right inguinal region and buttocks, diffuse alopecia and labial perleage.

Without treatment, the skin lesions become erosive and spread to other periorificial areas of the face (eyes, nose and ears), neck, lower abdomen, back, inguinal region and thighs. In some cases, lesions may appear as psoriasis. Other mucosal signs include loss of eyelashes and eyebrows, glossitis, gingivitis, stomatitis, anichodystrophy, anicholysis and pachyonychia [6] [14]. Diarrhoea (the predominant extracutaneous symptom) is variable and may be intermittent or absent altogether. In children with watery diarrhoea, general symptoms and neuropsychological disorders are common (irritability, lethargy, anorexia) as well as growth retardation, weight loss and anaemia.

As in the literature, our patient presented with chronic diarrhoea, stunted growth and weight loss. Secondary bacterial infections (gram-positive and sometimes gram-negative) or candidiasis (*Candida albicans*) are common and can alter the clinical picture [15]. This was also the case in our patient, who presented with a bacterial superinfection with *Klebsiella pneumoniae* and a fungal superinfection with *Candida albicans*, which contributed significantly to the deterioration of her clinical condition.

The diagnosis is based on clinical symptoms and confirmed by low plasma zinc levels and a rapid clinical response to zinc supplementation. In our case too, the diagnosis was based on clinical symptoms (chronic diarrhoea, skin lesions and alopecia), confirmed by low plasma zinc levels. However, zinc sulphate supplementation did not bring any clinical improvement, as the patient's clinical condition progressively deteriorated. She developed septicaemia, persistent diarrhoea and multifocal necrotic skin ulcers, which led to her death 57 days after the start of Zinc supplementation.

As this is an autosomal recessive disease, genetic studies with detection of the mutation in the SLC39A4 gene, located in band 8q24, could have helped with the diagnosis. However, this test is not easily available in our centre.

## 5. Conclusion

Acrodermatitis enteropathica is a rare but serious condition. This case highlights the challenges of diagnosis and management of these patients. Early recognition of its clinical manifestations is necessary to avoid complications that may lead to the patient's death.

## Conflicts of Interest

The authors declare no conflicts of interest regarding the publication of this paper.

## References

- [1] Perafan-Riveros, C., Franca, L.F., Alves, A.C. and Sanches Jr., J.A. (2002) Acrodermatitis Enteropathica: Case Report and Review of the Literature. *Paediatrics Dermatology*, **19**, 426-431. <https://doi.org/10.1046/j.1525-1470.2002.00200.x>
- [2] Del Ciampo, I.R.L., Sawamura, R., Del Ciampo, L.A. and Fernandes, M.I.M. (2018) Acrodermatitis Enteropathica: Clinical Manifestation and Paediatric Diagnosis: Case Report. *Revista Paulista de Pediatria*, **36**, 238-241. <https://doi.org/10.1590/1984-0462/2018;36;2:00010>
- [3] Lyengar, S., Chambers, C. and Sharon, V.R. (2015) Bullous Acrodermatitis Enteropathica: Case Report of a Single Clinical Presentation and Review of the Literature. *Dermatology Online Journal*, **21**, No. 4. <https://doi.org/10.5070/D3214026272>
- [4] Li, C.R., Feng, S.Y., Wang, Q., et al. (2012) Two Novel Compound Heterozygous Mutations of SLC39A4 in Generalised Eczematoid Acrodermatitis Enteropathica. *European Journal of Dermatology*, **22**, 794-795. <https://doi.org/10.1684/ejd.2012.1848>
- [5] Lakdawala, N. and Grant-Kels, J.M. (2015) Acrodermatitis Enteropathica and Other Nutritional Diseases of the Folds (Intertriginous Areas). *Clinics in Dermatology*, **33**, 414-419. <https://doi.org/10.1016/j.clindermatol.2015.04.002>
- [6] Cohen, B.A. (2015) Acrodermatitis Enteropathica. In: McMillan, J., Barrett, D. and Boney, C., Eds., *Clinical Decision Support: Pediatrics*, Decision Support in Medicine LLC, Wilmington DE. <http://www.decisionsupportinmedicine.com/>
- [7] Maveraskis, E., Fung, M.A., Lynch, P.J., Draznin, M., Michael, D.J., Ruben, B., et al. (2007) Acrodermatitis Enteropathica and an Overview of Zinc Metabolism. *Journal of the American Academy of Dermatology*, **56**, 116-124. <https://doi.org/10.1016/j.jaad.2006.08.015>
- [8] Kambe, T., Fukue, K., Ishida, R. and Miyzaki, S. (2015) Overview of Inherited Zinc Deficiency in Infants and Children. *Journal of Nutritional Science and Vitaminology*, **61**, S44-S46. <https://doi.org/10.3177/jnsv.61.S44>
- [9] Jensen, S.L., McCuaig, C., Zembowicz, A. and Hurt, M.A. (2008) Bullous Lesions in Acrodermatitis Enteropathica Delaying Diagnosis of Zinc Deficiency: A Report of Two Cases and Review of the Literature. *Journal of Cutaneous Pathology*, **35**, 1-13. <https://doi.org/10.1111/j.1600-0560.2008.00981.x>
- [10] Jat, K.R., Marwaha, R.K., Panigrahi, I. and Kaur, S. (2009) Fulminant Candida Infection in an Infant with Acrodermatitis Enteropathica. *The Indian Journal of Pediatrics*, **76**, 941-942. <https://doi.org/10.1007/s12098-009-0145-7>
- [11] Walker, C.L., Ezzati, M. and Black, R.E. (2009) Global and Regional Infant Mortality and Burden of Disease Attributable to Zinc Deficiency. *European Journal of Clinical Nutrition*, **63**, 591-597. <https://doi.org/10.1038/ejcn.2008.9>
- [12] Kury, S., Dreno, B., Bezieau, S., et al. (2002) Identification of SLC39A4, a Gene Involved in Acrodermatitis Enteropathica. *Nature Genetics*, **31**, 239-240. <https://doi.org/10.1038/ng913>
- [13] da Matta Ain, A.C., Dos, E., Valente, S., Mallozi, M.C., Sarni, R.O.S., Furquin, M. and Solé, D. (2008) Acrodermatitis Enteropathica-Like Simulating Severe Atopic Dermatitis: A Case Report. *Allergologia et Immunopathologia*, **36**, 176-179.

[https://doi.org/10.1016/S0301-0546\(08\)72543-6](https://doi.org/10.1016/S0301-0546(08)72543-6)

- [14] Gutiérrez González, E., Álvarez Pérez, A., Loureiro, M., *et al.* (2012) Acrodermatitis Enteropathica in a Breast-Fed Infant. *Actas Dermo-Sifiliográficas*, **103**, 170-172.  
<https://doi.org/10.1016/j.adengl.2012.03.012>
- [15] Scrivener, Y. and Bessi, D. (2012) Dermatoses Carentielles. In: *Manifestations dermatologiques des maladies d'organe*, Springer Verlag, Paris, 45-62.  
[https://doi.org/10.1007/978-2-287-72073-4\\_4](https://doi.org/10.1007/978-2-287-72073-4_4)