

Unusual Presentation of Bladder Tumour: Haematuria only after Administration of Anti-Platelet Drugs

STEPHEN LALFAK ZUALA SAILO¹, LALTANPUII SAILO², VERACIOUS CORNERSTONE WANN³

ABSTRACT

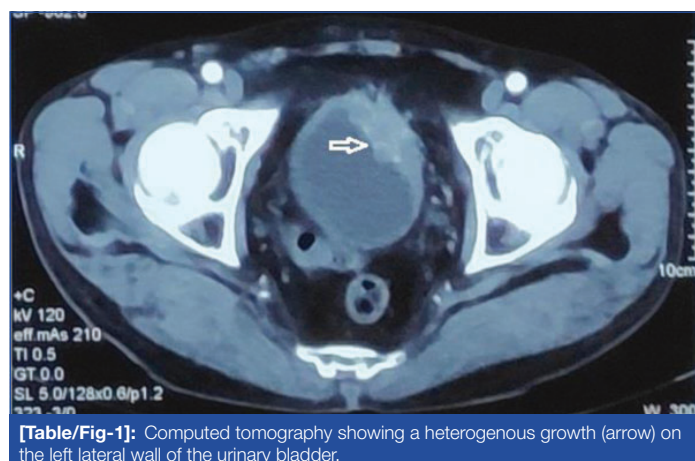
Anti-thrombotic agents are used for the treatment and prevention of cardiovascular diseases. Bleeding is the most important side-effect of these agents. The common causes of haematuria after anti-thrombotic administration are benign prostatic hyperplasia, haemorrhagic cystitis, renal calculi, renal infarction, infection, and adult polycystic kidney disease. Haematuria only after anti-thrombotic administration can be the presentation of a bladder tumour. Here, 71 years old male patient, with a bladder tumour was reported, who presented with haematuria only after he took dual anti-platelet drugs (tablet Ecosprin and tablet Clopidogrel). He took these drugs after he underwent the insertion of cardiac stents. He never had any previous history of haematuria. After the complaint, ultrasonography was performed and it reported a normal urinary system. So, the anti-platelet drugs were suspected to be the cause of haematuria. Tablet Clopidogrel was stopped and patient was sent home on Tablet Ecosprin. However, one month later, he again developed haematuria. Repeat imaging studies (ultrasonography and computed tomography) detected a urinary bladder mass. Transurethral resection of the mass was performed and a biopsy reported high-grade, muscle-invasive transitional cell carcinoma. This case highlights the fact that all cases of haematuria, irrespective of anti-thrombotic agents' administration, should be suspected to be due to urological malignancy and the patients should undergo complete urological investigations, including cystoscopy.

Keywords: Anti-thrombotic agents, Cystoscopy, Ultrasonography, Urological investigation

CASE REPORT

A 71-year-old male patient, underwent cardiac stenting in July 2019 and he was started on anti-platelet agents (Tablet Ecosprin 75 mg and Tablet Clopidogrel 75 mg). He developed haematuria in January 2020 for which he was admitted to a local hospital for evaluation. He was started on urinary bladder irrigation because of profuse bleeding. Ultrasonography reported normal kidneys, normal bladder, and prostate. The haematuria subsided with bladder irrigation. Since, the ultrasonography did not detect any abnormality in the urinary tract, the haematuria was thought to be due to the effect of the anti-platelet agents. So, a cardiologist was consulted, Tablet Clopidogrel was stopped and the patient was discharged home on Tablet Ecosprin.

However, one month after discharge, he again developed haematuria. So, he was re-admitted and ultrasonography was repeated. The repeat ultrasonography detected a polypoidal hypoechoic mass, measuring 2.8x2.0 cm, with internal vascularity on the left lateral wall of the urinary bladder. Computed tomography was then performed which showed a heterogenous growth of the same size on the left lateral wall of the urinary bladder with perivesical fat stranding [Table/Fig-1].



[Table/Fig-1]: Computed tomography showing a heterogenous growth (arrow) on the left lateral wall of the urinary bladder.

The bladder tumour was resected on the 9th of March 2020. Biopsy was reported as high-grade urothelial carcinoma with muscle invasion, clinical staging of T₃N₀M₀ [1]. Since, the bladder growth involved the left lateral wall, he was not suitable for partial cystectomy [2]. So radical cystectomy with ileal conduit was planned but the patient refused the proposed operation. He was then lost to follow-up.

DISCUSSION

Anti-thrombotic agents are used for the treatment and prevention of cardiovascular diseases. The most common anti-thrombotic agents are heparin or its derivatives, vitamin K antagonists and anti-platelet agents, including aspirin and clopidogrel. The most important side-effect of anti-thrombotic agents is bleeding and 2-24% of patients on anti-coagulants develop bleeding complications [3,4]. The bleeding involves the intracranial, gastro-intestinal tract, visceral, musculo-skeletal, soft tissues or urinary tract [5]. The overall risks of haematuria in patients on anti-coagulants and anti-platelet agents are 26.7% and 0.5%, respectively [6].

This patient developed gross haematuria only after anti-platelet drugs were administered. The initial ultrasound examination might have missed the bladder tumour due to blood clots in the urinary bladder or sub-optimally distended urinary bladder, as the patient was on bladder irrigation due to haematuria.

In a pooled meta-analysis of 175000 patients who developed haematuria after anti-thrombotic agents' administration, Bhatt NR et al., reported that urologic pathology in 44% of cases and malignancy was seen in 24% of patients [6]. Yu HT et al., reported that oral anti-coagulation therapy-enhanced haematuria in patients with atrial fibrillation, helped to detect bladder tumour earlier and the tumours were low pathologic grade [7]. Wallis CJD et al., reported that the use of anti-thrombotic medications caused an increased rate of haematuria-related complications and clinically silent bladder cancers may be found by the use of

anti-thrombotic agents [8]. In a study of 227 patients with bladder cancer, Moschini M et al., reported that patients who received anti-platelet or anti-coagulant therapy presented with haematuria significantly earlier resulting in earlier diagnosis and treatment of bladder cancer [9].

This case report underlines the fact that all patients with haematuria, even if the patient is on anti-platelet medication, should be suspected to have urological pathology.

CONCLUSION(S)

A complete urological investigation should be performed in all cases of haematuria, irrespective of anti-thrombotic administration. As seen in this patient, in cases of recurrent or persistent haematuria, though the initial urological investigations may be normal, repeat investigations should be performed so as not to miss any urological tumour. Cystoscopy should be performed to rule out urinary bladder tumours.

REFERENCES

- [1] Ahmadi H, Duddalwar V, Daneshmand S. Diagnosis and staging of bladder cancer. *Hematol Oncol Clin North Am.* 2021;35(3):531-41.
- [2] Koga F, Kihara K, Fujii Y, Yoshida S, Saito K, Masuda H, et al. S. Favourable outcomes of patients with clinical stage T3N0M0 bladder cancer treated with induction low-dose chemo-radiotherapy plus partial or radical cystectomy vs immediate radical cystectomy: A single-institutional retrospective comparative study. *BJU Int.* 2009;104(2):189-94.
- [3] Levi MM, Eerenberg E, Lowenberg E, Kamphuisen PW. Bleeding in patients using new anticoagulants or antiplatelet agents: risk factors and management. *Neth J Med.* 2020;68(2):68-76.
- [4] Mladenov BS, Mariyanovski V, Hadzhiyaska V. Macroscopic haematuria in patients on anticoagulation therapy. *Cent European J Urol.* 2015;68(3):330-33.
- [5] Green L, Tan J, Morris JK, Alikhan R, Curry N, Everington T, et al. A three-year prospective study of the presentation and clinical outcomes of major bleeding episodes associated with oral anticoagulant use in the UK (ORANGE study). *Haematologia.* 2018;103(4):738-45.
- [6] Bhatt NR, Davis NF, Nolan WJ, Flynn RJ, McDermott T, Thomas AZ, et al. Incidence of visible haematuria among antithrombotic agents: A systematic review of over 175, 000 patients. *Urology.* 2018;114:27-32. Doi: 10.1016/j.urology.2017.11.023. Epub 2017 Nov 27.
- [7] Yu HT, Kim TH, Uhm JS, Kim JY, Park HN, Lee MH, et al. Clinical significance of haematuria in atrial fibrillation with oral anticoagulation therapy. *Circ J.* 2017;81(2):158-64.
- [8] Wallis CJD, Juvet T, Lee Y, Matta R, Herschorn S, Kodama R, et al. Association between use of antithrombotic medication and hematuria-related complications. *JAMA.* 2017;318(13):1260-71.
- [9] Moschini M, Karnes RJ, Suardi N, Bianchi M, Pellucchi F, Rocchini L, et al. Potential effect of antiplatelet and anticoagulant therapy on the timing of the diagnosis of bladder cancer. *Clin Genitourin Cancer.* 2016;14(3):e245-50.

PARTICULARS OF CONTRIBUTORS:

1. Professor, Department of Urology, North-Eastern Indira Gandhi Regional Institute of Health and Medical Sciences, Shillong, Meghalaya, India.
2. Assistant Professor, Department of Anaesthesiology, Zoram Medical College, Aizawl, Mizoram, India.
3. Associate Professor, Department of Urology, North-Eastern Indira Gandhi Regional Institute of Health and Medical Sciences, Shillong, Meghalaya, India.

NAME, ADDRESS, E-MAIL ID OF THE CORRESPONDING AUTHOR:

Stephen Lalfak Zuala Sailo,
A-19, Faculty Quarters, NEIGRIHMS, Shillong, Meghalaya, India.
E-mail: stephensailo@gmail.com

PLAGIARISM CHECKING METHODS: [Jain H et al.]

- Plagiarism X-checker: Oct 07, 2022
- Manual Googling: Feb 11, 2023
- iThenticate Software: Mar 27, 2023 (1%)

ETYMOLOGY: Author Origin

AUTHOR DECLARATION:

- Financial or Other Competing Interests: None
- Was informed consent obtained from the subjects involved in the study? Yes
- For any images presented appropriate consent has been obtained from the subjects. Yes

Date of Submission: **Oct 06, 2022**

Date of Peer Review: **Feb 07, 2023**

Date of Acceptance: **Mar 28, 2023**

Date of Publishing: **May 01, 2023**