

Original Research



Problem-solving with clinical reasoning: A case report of coronavirus in immunosuppressive condition

Mahshad Mousavi^{1,2}, Nazanin Mousavi^{1,2}, Babak Abdolkarimi^{3,4*}

¹Student Research Committee, School of Medicine, Lorestan University of Medical Science, Khorramabad, Iran

²Scientific Society of Evidence-Based Knowledge, Research office for the History of Persian Medicine, Lorestan University of Medical Science, Khorramabad, Iran

³Department of Pediatric Hematology-Oncology, Lorestan University of Medical Science, Khorramabad, Iran

⁴Department of Medical Education, Lecturer in the field of Clinical Reasoning Olympiad, School of Medicine, Lorestan University of Medical Science, Khorramabad, Iran

Article info

Article History:

Received: 17 Jul. 2021
Accepted: 4 Sep. 2021
epublished: 19 Oct. 2021

Keywords:

Clinical reasoning
Problem solving
Coronavirus
Pandemia
Rheumatoid arthritis

Abstract

Background: One of the most interesting parts of medical science is using clinical reasoning to solve clinical problems. In today's world of medicine, with increasing amounts of scientific information and new diagnostic and treatment facilities, physicians' responsibility in managing the condition of patients becomes weightier. Making the correct decision is an important goal that can be achieved by having adequate information and using it appropriately. At this stage, we should follow the thought process of successful doctors and use information from books and articles to solve clinical problems. The purpose of this article is to improve the skills of physicians in the effective use of knowledge and experience to solve clinical problems to increase our success in fulfilling our responsibility to patients.

Methods: Clinical reasoning enhances the quality of learning and increases the ability of medical students in clinical problem-solving. In this article, a patient with rheumatoid arthritis in the COVID-19 pandemic developed respiratory distress, is identified by the clinical reasoning method and is treated, with his treatment then discussed. This article includes the following: prepare a list of differential diagnoses based on the list of signs and symptoms of the patient; modify the initial list to reflect findings from history and examinations; specify additional information to make a correct diagnosis; and, finally, decide when the information is obtained is sufficient to make the proper diagnosis.

Results: In recent years, clinical reasoning has received more attention in student Olympiad competitions. Professors in medical sciences should pay special attention to teaching this skill to students. It is necessary to plan for teaching this type of training and to design tests for evaluating students' clinical reasoning. This article can thus be a useful guide for those who enjoy working on a problem to get an answer.

Conclusion: This article shows how insidious and life-threatening a coronavirus infection can be, and how useful clinical reasoning can be when present in all stages of dealing with the patient, from the initial stages of taking the patient history to the end of treatment.

Introduction

Problem-solving is one of the most interesting parts of medical science for those who want to be knowledgeable doctors and enjoy solving a problem until they get a solution. Clinical reasoning is an approach to clinical problem solving and is a necessary skill for physicians.¹ Mere theoretical reading of the material alone cannot solve problems in medical science as in physics, mathematics, and chemistry. Diagnosis begins with obtaining a complete history and a thorough clinical examination and reviewing the patient's medical history (current and past) to find

information that justifies the findings and continues with processing and thinking of a skilled physician to reach a primary diagnosis and treatment.

Integrating the patient's symptoms can be justified with a single diagnosis as the "principle of parsimony," and the "Occam's Razor rule" emphasizes the choice of the simplest solution to achieve the answer. On the other hand, making more differential diagnoses and finding a cause for each patient's complaints and symptoms is known as the "Saint's Triad" theory, which states that "each patient's problems can have a separate cause." In complex cases,

*Corresponding author: Babak Abdolkarimi, Email: b.abdolkarimi@yahoo.com

© 2021 The Author(s). This is an Open Access article distributed under the terms of the Creative Commons Attribution License (<http://creativecommons.org/licenses/by/4.0>), which permits unrestricted use, distribution, and reproduction in any medium, as long as the original authors and source are cited. No permission is required from the authors or the publishers.

when all symptoms and findings cannot be ascribed to a single diagnosis, it is used so that the cause is not ignored and important possible diagnoses are not neglected.² These two rules, which at first glance are in opposition to one other, a balance should be established between them and both should be considered in dealing with patients so they benefit from diagnostic and therapeutic measures and bear the least cost and harm. Differential diagnoses usually change as the patient is examined and new information is obtained. If only common diagnoses are considered, it may lead to misdiagnosis and harm to the patient. Rare but important and urgent diagnoses that can endanger the patient's life should not be omitted. Students and residents can learn how experienced physicians deal with clinical problems by compiling a list of differential diagnoses.

Clinical reasoning is a method for clinical problem solving to achieve a correct diagnosis. In this process, which begins at the same time as taking a history, the physician uses a statistical approach and critical thinking to prepare a problem list. The process of constructing a hypothesis begins with making differential diagnoses.³

Hypothesis testing is performed by referring to differential diagnoses and paraclinical tests. In evaluating and testing the hypothesis, the patient's medical history, examination, and medical history may be referred to several times. More reliable findings may be sought by using a variety of information sources. Making a list of the patient's problems, reaching the correct differential diagnoses, and using appropriate methods to confirm or reject these diagnoses and test the hypothesis is crucial because if a first wrong step is taken, the physician may be led astray and critical time for diagnosis and treatment may be lost.^{4,5}

In this article, to solve a clinical problem, information about a patient is presented to a doctor step by step so the doctor may provide reasons and justifications for reaching a diagnosis of the disease according to the provided explanations. The reader of the article can compare the process that goes through his mind to reach the diagnosis with the description of the specialist doctor. The author's opinion is stated at the end of the article and under the heading entitled, "Discussion".

Case Presentation

A 70-year-old woman with a history of rheumatoid arthritis complained of shortness of breath that started 10 days ago and has gradually progressed with cough without sputum. She also mentioned fever and feeling pain in her right hip from 7 days ago, which has limited her movement.

Referring to the acute onset of the patient's symptoms and her underlying disease, a list of differential diagnoses was prepared. Depending on the clinical context in which the symptoms occur, the multiple complications of rheumatoid arthritis should be considered, such

as interstitial lung disease, minor airway disease, and pleural or pericardial effusion. Other diseases associated with pulmonary complications and arthritis, including Wegener's granulomatosis and systemic lupus erythematosus, should also be considered. The patient may also have a lung infection, especially if she is being treated with immunosuppressive drugs. Pain in the patient's legs and buttocks can be due to septic arthritis of the hip and knee joint, sciatica, deep vein thrombosis, or flare-up of the underlying disease of rheumatoid arthritis. At this stage, a diagnostic hypothesis can be made using the "Principle of parsimony" to integrate the symptoms according to the clinical context in which they occur. Most signs and symptoms present the least number of hypotheses, and after making a hypothesis using a history, it should be evaluated by clinical examination and paraclinical tests.

A few days ago, due to fever, tachypnea, and hypoxia, a chest x-ray and venous color Doppler ultrasound were performed, with normal results.

In evaluating a hypothesis, various methods can be used, one of which is the "Elimination method", in which a diagnosis can be rejected or confirmed by testing a hypothesis using a test with high sensitivity and specificity. Normal chest x-ray denies extensive effusion, but this x-ray was taken in the early stages of the disease, and it does not rule out the involvement of the lung parenchyma, which may show up a few days later, so it needs to be reconsidered more carefully. On the other hand, the normality of venous color Doppler ultrasound dilutes the diagnosis of deep vein thrombosis of the foot, but it does not have a high negative predictive value and cannot rule out this diagnosis.

At this stage, we can focus on four categories of diseases: a primary infectious process in the lungs (especially if the patient is taking an immunosuppressive drug); an infection elsewhere (with attention to pain in the patient's legs and buttocks) with a secondary process involving the lungs including bacteremia or acute respiratory distress syndrome; a non-infectious inflammatory process that can cause fever (such as obliterans bronchiolitis with developing pneumonia, pulmonary embolism, despite normal ultrasound of the leg veins, lupus, or Wegener); or drug side effects (according to the pharmaceutical treatment of her rheumatic disease).

The "Discrimination method" is used to evaluate hypotheses and categorize differential diagnoses to limit them according to their pathophysiology and anatomy. In this case, by categorizing differential diagnoses into four main categories according to their pathophysiological process, initial tests can be requested to differentiate these four categories. This method can help us confirm or reject the hypotheses, the same as using the Discrimination method in clinical reasoning.

In this patient, due to shortness of breath and fever, in the first stage chest, x-ray and venous color Doppler

ultrasound were performed to assess the thrombosis of the deep veins of the right lower extremity, followed by pulmonary embolism, which is a life-threatening diagnosis. In contrast, normal venous color Doppler ultrasound does not rule out pulmonary embolism and needs to be evaluated with higher negative predictive value tests, such as chest CT angiography.

In collecting information, the reliability of the data and the multiplicity of sources that confirm these findings are crucial. The doctor's evidence in the patient's clinical examination (sign) is more valuable than the complaint that the patient mentions (symptom). For example, when a patient complains of fever and expresses it as a symptom, it can be turned into a sign by measuring body temperature. The use of various information sources, including the patient's companions and medical records and history of illness and statements of medical staff, occupation, education and living conditions of the patient and risk factors of the disease and his/her medications are all necessary in obtaining accurate information.

The patient's rheumatoid arthritis was under control with 5 mg prednisolone daily (over the past ten years), 10 mg methotrexate orally weekly on Thursdays and Fridays (over the past year), and 300 mg infliximab by intravenous injection every two months (from four months ago). The patient's tuberculin skin tests, performed one year ago and four months ago, were negative. Other medications taken by the patient included daily folic acid supplementation (except Thursdays and Fridays), acetaminophen, calcium and vitamin D tablets, and weekly alendronate tablets (to prevent osteoporosis).

Methotrexate can be associated with inflammatory complications and involvement of the pulmonary parenchyma. Although the dosage of prednisolone is relatively low, due to the use of methotrexate and especially infliximab, the patient is considered to have an immunosuppressive condition, which puts her at risk for common bacterial and viral pneumonia, including coronavirus, as well as a wide range of opportunistic infections include pneumocystis and fungi and mycobacteria. A particular concern with infliximab, a functional antagonist of tumor necrosis factor (TNF), is mycobacterium tuberculosis's susceptibility. With the high prevalence of coronavirus, it should be considered as an important differential diagnosis. Because of the fever and respiratory symptoms, an opportunistic infection involving the lungs should be seriously considered. A negative tuberculin skin test cannot rule out tuberculosis in immunosuppressive conditions.

The patient was alert, and she had tachypnea and moderate respiratory distress. Blood pressure and heart rate were normal, with a respiration rate of 24 beats per minute and a temperature of 38.3°C. The oxygen saturation was 75% in room air, and she used intercostal muscles to breathe. On examination of the lungs, scattered crackles were heard, largely in the lower areas of the lungs.

On cardiac examination, the first sound was typical, but the second sound was loud. Hypertrophic changes were present in the proximal interdigital joints (PIP) and the joints between the metacarpal and fingers (MCP), with deviation toward the ulnar of both hands. Examination of the right hip joint did not reveal acetabular tenderness, and the range of motion of the joint was normal. The right knee joint had no swelling, erythema, warmth, or restriction of movement. There was no tenderness of leg muscles and edema on examination.

The most interesting point in the examination of this patient is the low degree of oxygen saturation (hypoxia) with a loud P₂ in the examination of the heart. Hypoxia can cause pulmonary vasoconstriction, complicate pulmonary vascular disease, and increase pulmonary artery pressure. A right-to-left shunt inside the heart, possibly due to a patent foramen ovale, may also explain the association of hypoxia and a loud second heart sound. An infectious disease, such as coronavirus infection or an opportunistic lung infection, may have caused hypoxia and high pressure in the pulmonary artery, thereby exacerbating right-to-left intracardiac shunt and worsened oxygen delivery conditions. This can lead to a faulty cycle (Figure 1).

Laboratory data are shown in Tables 1, 2, and 3. Supplemental oxygen was administered through a face mask at 5 L/min, and an arterial blood gas sample was taken (Table 3). In the second chest x-ray, patchy infiltrations of both lungs were seen (Figure 2). The ECG was normal.

A slight increase in aminotransferase levels may indicate an early effect of methotrexate on the liver, although it may also indicate a nonspecific response to a systemic infection. The patient's acid-base status is more suggestive of metabolic acidosis and respiratory alkalosis. High erythrocyte sedimentation rate (ESR=78) and increased C-reactive protein level (CRP=+++) indicate inflammation, infection, or both (Table 2); Can her rheumatic disease alone justify these findings, or are other processes likely to play a role? Pulmonary infiltration is also a non-specific finding on chest x-ray and indicates

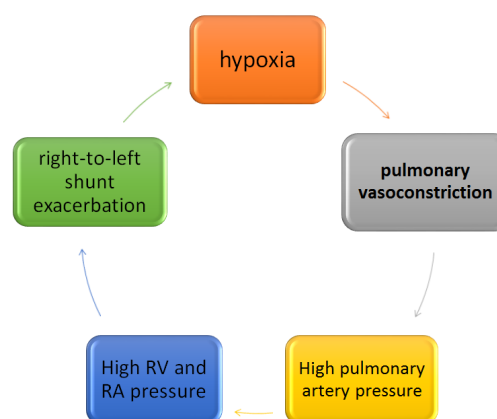


Figure 1. Mechanism of hypoxia due to a right-to-left shunt.

Table 1. Hematology data

Hematology	Result	Unit	Reference Value
WBC	11.1	10 ³ /μL	4-10.5
RBC	4.76	10 ³ /μL	4.7-6
Hb	13.0	g/dL	13.5-18
HCT	39.5	%	42-53
MCV	83.0	fl	78-100
MCH	27.3	pg	27-31
MCHC	32.9	g/dL	32-36
PLT	333	10 ³ /μL	150-450
Differential			
Neutrophils	74.7	%	43-78
Lymphocytes	13.8	%	15-45
Monocytes	9.8	%	4-9
Eosinophils	1.4	%	1-7
Basophils	0.3	%	0.3-1.3
Band Cells	1	%	

WBC: white blood cell, RBC: red blood cell, Hb: hemoglobin, HCT: hematocrit, MCV: mean corpuscular volume, MCH: mean corpuscular hemoglobin, MCHC: mean corpuscular hemoglobin concentration, PLT: platelet, μl: microliter, g/dl: grams per deciliter, fl: femtoliter, pg: picograms.

inflammation or an infectious process. Mostly an infectious process should be considered, principally opportunistic infections (especially tuberculosis, due to treatment with infliximab), coronavirus infection (due to its high prevalence regardless of the PCR test result), septic arthritis (with secondary pulmonary manifestations due to septic embolism and acute respiratory distress syndrome), or a non-infectious inflammatory process, including damage to the pulmonary parenchyma due to methotrexate or obliterans bronchiolitis with developing pneumonia.

Although the patient did not report contact with people with the coronavirus infection, a nasopharyngeal sample was sent for coronavirus PCR testing. Smear and culture of sputum were performed for bacteria and treatment of experimental and temporary antibiotics with levofloxacin, intravenous trimethoprim, and sulfamethoxazole. Treatment with corticosteroids was started.

Although experimental antibiotic treatment for pneumocystis pneumonia or community-acquired pneumonia started, other diagnostic tests had to be done immediately for the patient, as there were other critical possible diagnoses.

Did the patient have an infection involving the joint? Did the patient have thromboembolism? Was opportunistic lung infection the cause of the patient's symptoms? Was the right-to-left shunt inside the heart (for example, patent foramen oval)? Could infectious endocarditis be the main cause of the patient's symptoms? Could TB be the main cause of the patient's manifestations? Did a non-infectious inflammatory process justify all the patient's symptoms? Could coronavirus infection be the main cause of all the

manifestations of this patient? Because more than one of these pathways may be involved, the most important differential diagnoses had to be considered to answer these questions, including thromboembolism and opportunistic infection.

Chest CT scan showed large emboli in the primary and segmental pulmonary arteries and peripheral infiltration with a ground-glass pattern (Figures 3 and 4).

Although deep vein thrombosis has been suggested as a possible cause of leg and hip pain and pulmonary embolism, the diagnosis of extensive pulmonary thromboembolism surprised us. Patchy infiltration is probably unrelated to thromboembolism, and infectious diseases such as coronavirus and opportunistic infections, especially tuberculosis and pneumocystis, should still be considered.

Backward reasoning is necessary at this stage because the CT scan findings do not justify all of the patient's

Table 2. General biochemistry

General Biochemistry	Result	Unit	Reference Value
ESR	78	mm/h	< 20
Urea	45	mg/dL	UPTO 66
Cr	0.98	mg/dL	0.5-1.5
AST	97	U/L	UPTO 40
ALT	55	U/L	UPTO 40
ALK-P	166	U/L	UPTO 300
BS	85	mg/dL	80-125
Ca	7.7	mg/dL	8.5-10.5
Ph	4.75	mg/dL	2.4-5
Na	134	mg/dL	135-145
K	3.6	mg/dL	3.5-5.5
LDH	1142	U/L	104-236
PTT	30	s	25-40
PT	12	s	9-15
INR	1		
CRP	+++		

ESR: erythrocyte sedimentation rate, Cr: creatinine, AST: aspartate transaminase, ALT: alanine transaminase, ALK_P: alkaline phosphatase, BS: blood sugar, LDH: lactate dehydrogenase, PTT: Partial thromboplastin time, PT: prothrombin time, INR: international normalized ratio, CRP: C-reactive protein, mm/h: millimeters per hour, mg/dL: milligrams per deciliter, U/L: units per liter, sec: seconds.

Table 3. Arterial Blood Gas

ABG	Result	Unit	Reference Value
pH	7.45		7.35-7.45
PO ₂	230	mm Hg	60-100
PCO ₂	29	mm Hg	36-44
HCO ₃	19	Mmol/L	20-28

ABG: arterial blood gas, mm Hg: millimeter of mercury, mmol/l: millimoles per liter.

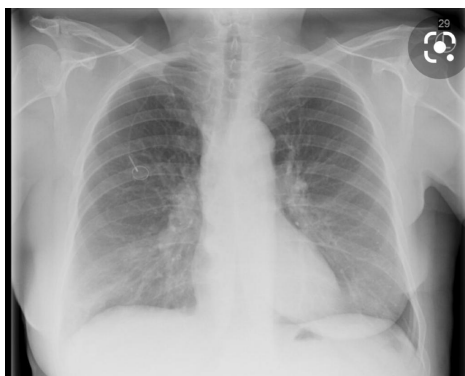

Figure 2. Chest X-ray.

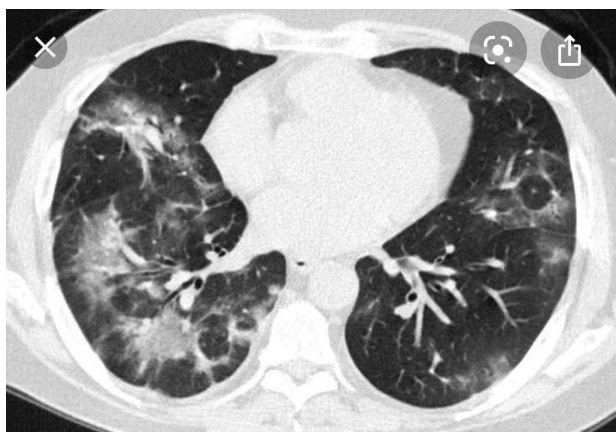


Figure 3. The spiral chest CT scan shows bilateral patchy infiltration.

symptoms. The involvement of the lung parenchyma and the appearance of bilateral pulmonary embolism reinforce the theory that a single disorder alone is not the cause of the findings. As “Hickam’s theory” emphasizes, as the incidence of acute and chronic diseases increases and societies age, the likelihood of two simultaneous diagnoses in one patient increases, especially when not all findings are justified by one diagnosis and are not aligned. This theory prevents ignoring any diagnosis that is far from the mind and provides better and more complete services to patients.

The PCR test of the nasopharyngeal specimen was positive for coronavirus and showed no sputum smear in favor of mycobacterial infection. Heparin was administered as a bolus and continuous intravenous injection. The patient’s hemodynamic and clinical status was stable and no fibrinolytic administration was required. After four days, supplemental oxygen was discontinued, and the patient no longer had shortness of breath at rest. Intravenous trimethoprim and sulfamethoxazole were discontinued and continued orally at prophylactic dosage. The dosage of corticosteroids was gradually reduced, and intravenous heparin treatment was continued (Figure 5). The patient was discharged from the hospital after seven days with oral corticosteroids that were reduced in dosage

and warfarin tablets. Health recommendations to prevent disease transmission and re-infection were explained to the patient and her companions, including how to take warfarin tablets and follow-up to ensure the correct dosage through blood tests.

Discussion

“Occam’s Razor” compared to “Saint’s Triad”

When a patient’s history and clinical examination are not consistent with a single diagnosis, how important is the possibility of several different diseases in a patient? A patient may have a disease for many complaints, signs, and symptoms (Hickam theory).⁶ This patient’s shortness of breath had two causes: “coronavirus infection and extensive pulmonary embolism.” If CT angiography of the chest had not been performed in this patient with suspected pulmonary embolism, this important diagnosis

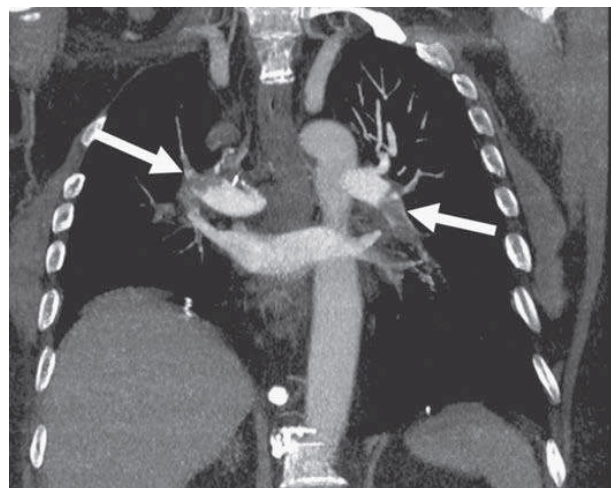


Figure 4. Large bilateral proximal PE on a coronal chest CT image. There are filling defects in the primary and segmental pulmonary arteries bilaterally (white arrows). Only the left upper lobe segmental artery is free of thrombus.

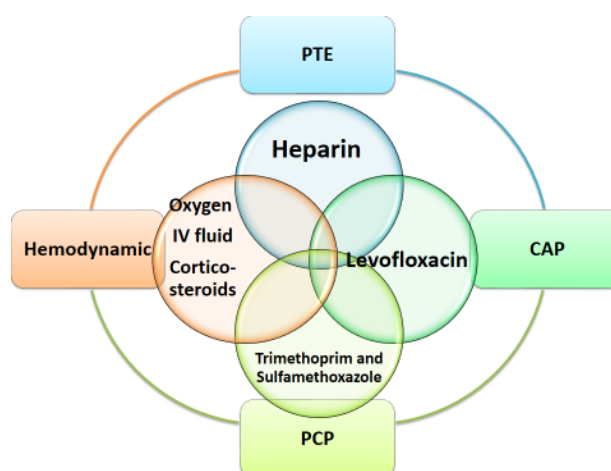


Figure 5. Treatment. PTE: Pulmonary embolism, CAP: Community-acquired pneumonia, PCP: *Pneumocystis jirovecii* virus.

could have been overlooked and neglected, especially considering the normal color Doppler ultrasound of the lower extremity and the appearance of ground glass and patchy infiltration in the chest CT scan and also the positive results of the PCR test of nasopharyngeal sample for COVID-19; all are in favor of lung parenchyma involvement due to coronavirus and justify the patient's shortness of breath and hypoxia and fever.

According to Osler's rule, "unnecessary multiplicity has no place" and the principle that "when dealing with a problem, the simplest solution is the most correct and the simplest of the hypotheses must be selected" (Occam's Razor). As in the case of the patient introduced in this article, sensitivity is a good feature for considering multiple differential diagnoses, but not always, because it can confuse us.

The valuable fact that having a complete history and thorough clinical examination usually leads us to a correct diagnosis is especially true in confusing patients.⁷

If we examine this patient according to "Hickam's theory", we will see that this patient's inflammatory arthritis needed corticosteroid treatment to control her symptoms. Her chronic immunosuppressive condition puts her at increased risk for opportunistic infection and coronavirus due to its pandemic condition. However, coronavirus infection can cause shortness of breath, fever, and fatigue, which reduces a patient's physical activity and exposes her to thromboembolism; it should be noted that systemic inflammation in the body activates the coagulation system and endothelial damage to vessels and the formation of thrombosis in various vessels, even without movement restrictions. Despite just one hypothesis, this line of reasoning justifies the increased risk of developing multiple and seemingly unrelated diseases. To this point, we have to balance the theories of the "Occam's Razor" and the "Saint's Triad", which are opposite at first glance, and strike a balance between them. In this way, the physician avoids drowning in multiple differential diagnoses and additional costs and does not neglect vital diagnoses by considering the possible causes that justify the patient's symptoms. (Figure 6A)

A study has shown that people over 65 with chronic

illnesses are less likely to be treated than those without an underlying disease when they present with disorders and complaints unrelated to their underlying disease. This study suggested that this finding could be due to using the "Occam's Razor" principle in health professionals who try to justify the patient's clinical symptoms and complaints by considering the underlying disease (Principle of parsimony).⁸ If physicians also pay attention to the "principles of the Saint's Triad" and "Hickam Theory", patients will receive better service as long as these do not lead to excessive and misleading paraclinical procedures. Although the "Saint's view" helps in complex medical cases, the "Principle of parsimony" cannot be abandoned. We have to get help from both theories, and we cannot apply one of these principles and ignore the other. In this way, patients benefit most from the correct diagnosis and treatment process while avoiding additional costs to them and the health system and losing time in reaching critical diagnoses.^{9,10}

In the logical course of taking the patient's history and examination and collecting information from various sources such as the patient's medical history and history of hospitalization or medications, we can combine these items such as pieces of a puzzle and make a logical connection between them or build a known syndrome.

Differential diagnoses should be presented according to priority, and thus a preliminary hypothesis is formed, which we evaluate and test the hypothesis by performing paraclinical measures to confirm or reject these hypotheses.¹¹ "Forward reasoning" is used to arrive at differential diagnoses from symptoms and findings. And again, returning from differential diagnoses to the symptoms of the disease and collecting more accurate and complete information using paraclinical measures to confirm or reject the hypothesis as "backward reasoning" can be used.¹² In this way, with each round trip between findings and differential diagnoses and confirmation or rejection of each of them, we can get closer to the correct diagnosis and appropriate and timely treatment (Figure 6B).

Given the importance of clinical reasoning in increasing the quality of learning of medical students and their ability

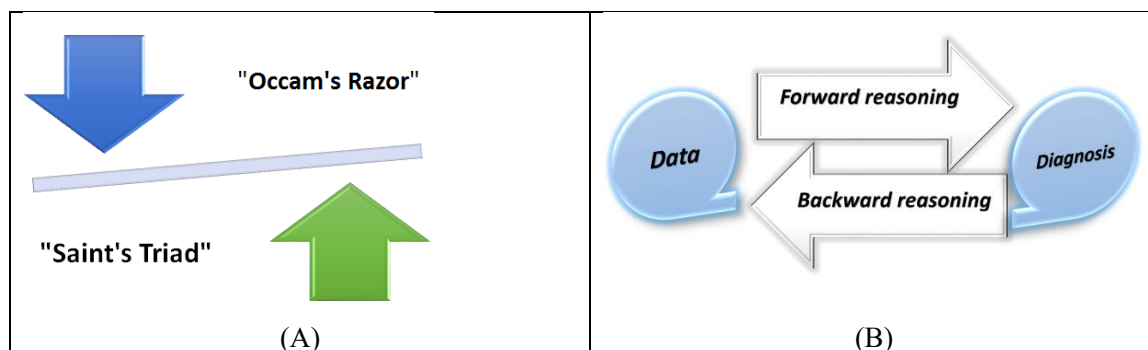


Figure 6. (A): Occam's Razor compared to Saint's Triad (B): Forward reasoning and Backward reasoning.

to solve clinical problems and reduce medical errors as well as the attention of student Olympiad organizers in recent years, professors in the medical sciences should pay special attention to cultivating and teaching this skill in students. For the Deputy Minister of Education of the Ministry of Health, necessary measures should be taken to learn this type of education and design tests to evaluate students in clinical reasoning.

How insidious and life-threatening can COVID-19 infection be?

In December 2019, numerous cases with coronavirus disease were reported in China; COVID-19 has since spread throughout the world; however, its impact on patients with rheumatoid arthritis was unknown. Acute infections are associated with a transiently increased risk of venous thromboembolic events. Bompard et al reported an overall 24% (95% CI: 17–32%) cumulative incidence of pulmonary embolism in patients with coronavirus infection, 50% (30–70%) in ICU, and 18% (12–27%) in other areas.¹³ Pulmonary embolism may be encountered in patients with coronavirus infection, showing how insidious and life-threatening COVID-19 infection can be. An asymptomatic young case of COVID-19 presenting with sudden death during physical activity due to acute massive pulmonary embolism has been previously described by Polat and Bostancı in a 41-year-old woman with diabetes mellitus.¹⁴ The risk factors for pulmonary embolism in patients with COVID-19 disease include obesity, a high d-dimer value, elevated C-reactive protein level, and a rising d-dimer value over time.¹⁵

It is recommended to raise awareness for possible benefits of examining known COVID-19 patients presenting sudden clinical worsening with CT pulmonary angiography instead of standard non-contrast chest CT.¹⁶ Griffin et al reported three patients with COVID-19 pneumonia who had persistent hypoxia responded well to intravenous corticosteroids and interleukin-6 receptor antagonist therapy, but later showed the development of persistent hypoxia were given a diagnosis of pulmonary embolisms.¹⁷

Danzi et al treated a 75-year-old woman with severe bilateral coronavirus pneumonia and concomitant acute pulmonary embolism with low molecular weight heparin, lopinavir/ritonavir, and hydroxychloroquine.¹⁸ Faggiano et al reported seven patients with COVID-19 pneumonia and increased risk of venous thromboembolic events (deep venous thrombosis and pulmonary embolism). Six of seven patients were treated with heparin with clinical benefit within few days; one patient needed systemic thrombolysis and unfortunately died from hemorrhagic complication.¹⁹ Decisions about extending prophylaxis with low molecular weight heparin after discharge from the hospital should be made after balancing the reduced risk of venous thromboembolism with the risk of increased bleeding events. Therapeutic anticoagulation is the

cornerstone in the management of pulmonary embolism, and selection of an appropriate agent and correct dosing requires attention to underlying comorbidities.²⁰

Durmaz and Ilhanli evaluated six months of treatment with low-dose rituximab in rheumatoid arthritis and found that it is an effective treatment option in treating RA during coronavirus disease 2019 (COVID-19) pandemic.²¹ Song et al. reported a case of coronavirus disease in a 61-year-old female patient with RA who was receiving conventional disease-modifying antirheumatic drugs (DMARDs) and was treated with antiviral agents (lopinavir/ritonavir). The treatment with DMARDs was discontinued except hydroxychloroquine, and her symptoms improved in three weeks.²²

Conclusion

Clinical reasoning enhances the quality of learning, increases medical students' proficiency in clinical problem solving, and reduces medical errors. In recent years, clinical reasoning has received more attention in student Olympiad competitions. Professors of medical sciences should pay special attention to teaching this skill to students. The Deputy Minister of Education of the Ministry of Health must plan for learning this type of training and design tests for assessing students in clinical reasoning.

Ethical approval

The authors completely attest to no ethical issues (including plagiarism, data fabrication, or dual publication).

Competing interests

The authors declare that they have no competing interests.

Authors' contributions

BA conceived the idea. MM and NM conducted clinical practice and prepared the primary draft, and finalized the manuscript.

Acknowledgments

The authors extend their appreciation towards those who helped us conduct the study.

References

1. Banning M. Clinical reasoning and its application to nursing: concepts and research studies. *Nurse Educ Pract.* 2008;8(3):177-83. doi: 10.1016/j.nepr.2007.06.004.
2. Guraya SY. The pedagogy of teaching and assessing clinical reasoning for enhancing the professional competence: a systematic review. *Biosci Biotechnol Res Asia.* 2016;13(3):1859-66. doi: 10.13005/bbra/2340.
3. Regehr G. *International Handbook of Research in Medical Education.* Dordrecht, the Netherlands: Kluwer Academic Publishers; 2002.
4. Ayers WR. Sherlock Holmes and clinical reasoning: empiric research on a methodology to teach clinical reasoning. In: Scherpbier AJ, van der Vleuten CP, Rethans JJ, van der Steeg AF, eds. *Advances in Medical Education.* Dordrecht: Springer; 1997. p. 600-1. doi: 10.1007/978-94-011-4886-

- 3_182.
5. McMillan WJ. Teaching for clinical reasoning - helping students make the conceptual links. *Med Teach.* 2010;32(10):e436-42. doi: 10.3109/01421591003695303.
 6. Levin M, Cennimo D, Chen S, Lamba S. Teaching clinical reasoning to medical students: a case-based illness script worksheet approach. *MedEdPORTAL.* 2016;12:10445. doi: 10.15766/mep_2374-8265.10445.
 7. Monajemi A, Adibi P, Soltani Arabshahi K, Arbabi F, Akbari R, Custers E, et al. The battery for assessment of clinical reasoning in the Olympiad for medical sciences students. *Iran J Med Educ.* 2011;10(5):1056-67. [Persian].
 8. Kernan WN, Quagliarello V, Green ML. Student faculty rounds: a peer-mediated learning activity for internal medicine clerkships. *Med Teach.* 2005;27(2):140-4. doi: 10.1080/01421590500047047.
 9. Batchelder AJ, Rodrigues CM, Lin LY, Hickey PM, Johnson C, Elias JE. The role of students as teachers: four years' experience of a large-scale, peer-led programme. *Med Teach.* 2010;32(7):547-51. doi: 10.3109/0142159x.2010.490861.
 10. Robinson Z, Hazelgrove-Planel E, Edwards Z, Siassakos D. Peer-assisted learning: a planning and implementation framework. *Guide supplement 30.7--practical application. Med Teach.* 2010;32(9):e366-8. doi: 10.3109/01421590903505679.
 11. Buckley S, Zamora J. Effects of participation in a cross year peer tutoring programme in clinical examination skills on volunteer tutors' skills and attitudes towards teachers and teaching. *BMC Med Educ.* 2007;7:20. doi: 10.1186/1472-6920-7-20.
 12. Araghian Mojarad F, Sadeghi A, Sanagoo A, Jouybari L. Necessity approach clinical reasoning in medical education. *Iran J Med Educ.* 2019;19(13):124-5. [Persian].
 13. Bompard F, Monnier H, Saab I, Tordjman M, Abdoul H, Fournier L, et al. Pulmonary embolism in patients with COVID-19 pneumonia. *Eur Respir J.* 2020;56(1):2001365. doi: 10.1183/13993003.01365-2020.
 14. Polat V, Bostancı G. Sudden death due to acute pulmonary embolism in a young woman with COVID-19. *J Thromb Thrombolysis.* 2020;50(1):239-41. doi: 10.1007/s11239-020-02132-5.
 15. Poyiadji N, Cormier P, Patel PY, Hadied MO, Bhargava P, Khanna K, et al. Acute pulmonary embolism and COVID-19. *Radiology.* 2020;297(3):E335-E8. doi: 10.1148/radiol.2020201955.
 16. Rotzinger DC, Beigelman-Aubry C, von Garnier C, Qanadli SD. Pulmonary embolism in patients with COVID-19: time to change the paradigm of computed tomography. *Thromb Res.* 2020;190:58-9. doi: 10.1016/j.thromres.2020.04.011.
 17. Griffin DO, Jensen A, Khan M, Chin J, Chin K, Saad J, et al. Pulmonary embolism and increased levels of d-dimer in patients with coronavirus disease. *Emerg Infect Dis.* 2020;26(8):1941-3. doi: 10.3201/eid2608.201477.
 18. Danzi GB, Loffi M, Galeazzi G, Gherbesi E. Acute pulmonary embolism and COVID-19 pneumonia: a random association? *Eur Heart J.* 2020;41(19):1858. doi: 10.1093/eurheartj/ehaa254.
 19. Faggiano P, Bonelli A, Paris S, Milesi G, Bisegna S, Bernardi N, et al. Acute pulmonary embolism in COVID-19 disease: preliminary report on seven patients. *Int J Cardiol.* 2020;313:129-31. doi: 10.1016/j.ijcard.2020.04.028.
 20. Sakr Y, Giovini M, Leone M, Pizzilli G, Kortgen A, Bauer M, et al. Pulmonary embolism in patients with coronavirus disease-2019 (COVID-19) pneumonia: a narrative review. *Ann Intensive Care.* 2020;10:124. doi: 10.1186/s13613-020-00741-0.
 21. Durmaz Y, Ilhanli I. Six month assessment of low dose rituximab in the treatment of rheumatoid arthritis during coronavirus disease 2019 (COVID-19) pandemic. *Egypt Rheumatol.* 2021;43(3):253-6. doi: 10.1016/j.ejr.2021.05.001.
 22. Song J, Kang S, Choi SW, Seo KW, Lee S, So MW, et al. Coronavirus disease 19 (COVID-19) complicated with pneumonia in a patient with rheumatoid arthritis receiving conventional disease-modifying antirheumatic drugs. *Rheumatol Int.* 2020;40(6):991-5. doi: 10.1007/s00296-020-04584-7.