

The Effects of Q Inside™ Safety Technology Micro Transponder on Routine Breast Implant Imaging

Sina Meisamy, Michael T. Nelson

Department of Radiology, University of Minnesota, Minnesota, USA

Email: mtnelsonrad@comcast.net

How to cite this paper: Meisamy, S. and Nelson, M.T. (2019) The Effects of Q Inside™ Safety Technology Micro Transponder on Routine Breast Implant Imaging. *Open Journal of Medical Imaging*, 9, 19-31.
<https://doi.org/10.4236/ojmi.2019.92002>

Received: April 2, 2019

Accepted: June 27, 2019

Published: June 30, 2019

Copyright © 2019 by author(s) and Scientific Research Publishing Inc.
This work is licensed under the Creative Commons Attribution International License (CC BY 4.0).

<http://creativecommons.org/licenses/by/4.0/>



Open Access

Abstract

Objectives: A recent entry into the silicone gel-filled breast implant market from Motiva Implants (Establishment Labs Holdings Inc., NY, USA) contains a radio frequency identification device micro-transponder (RFID-M), known as the Q Inside Safety Technology, as an added safety feature embedded in the shell of its breast implant. This RFID-M device allows for the rapid unique identification of the implant. Concern for imaging voids due to the presence of the RFID device during MRI screening scans have arisen given its metallic components. Our investigation aims to determine whether the Q Inside Safety Technology RFID-M device in the Motiva Implants Limits the visualization of breast tissue in conventional breast imaging modalities. **Methods:** Seven patients with Motiva Implants were referred to dedicated diagnostic breast imaging centers for evaluation of their prostheses and surrounding breast parenchyma between January and May 2018. Imaging indications included routine evaluation of implant integrity, evaluation of significant breast symptoms, oncologic follow-up, and breast cancer screenings. **Results:** Under mammography, the Motiva Implants have a similar contour and mobility to other commonly used implants. The RFID-M is not visible and produces no artifact, allowing for proper visualization and screening of all visualized parenchymal tissues. Under ultrasound, the Motiva Implants are well-visualized in all patients. The RFID-M was not visible *in vivo*. No related ultrasound artifact was apparent within the lumen or behind the implant as shown in **Figure 2(a)**. Five patients received MRI. The breast parenchyma and axillae were well-visualized in all 5 patients. The RFID-M was found to produce a “butterfly-shaped” susceptibility artifact that projects into the lumen of the breast implant and causes image distortion in some of the surrounding soft tissues and chest wall posterior to the implant. **Conclusion:** Aside from making its presence evident inside the implant, the Q Inside

Safety Technology RFID-M does not interfere with the mammographic or sonographic exam, its results, or any consequent diagnosis made via their analysis. In the same respect using optimized MRI sequences to evaluate patients we were able to obtain satisfactory visualization of breast tissue in patients with the new Motiva Implants, and recommend using optimized study protocols for both early cancer detection and assessment of the implant's integrity.

Keywords

Breast, MRI, Ultrasound, Mammography, Implants, Radio Frequency Identification Device, RFID

1. Introduction

Over 1.3 million breast implants are placed each year around the world with almost 300,000 of those being implanted in the U.S. [1]. In compliance with FDA guidelines, each implant must be imaged at 2-year intervals for the first 10 years after implantation to verify and monitor their structural integrity [2]. Patients with increased breast cancer risks are often monitored even more frequently [3]. The sheer number of patients with implants and the frequency with which they are monitored has made encountering implants on imaging studies ever more common. It is therefore imperative that radiologists interpreting these studies can quickly and accurately identify relevant findings concerning the patient's implants and the surrounding tissues.

Breast implants interact permanently with a patient's body and exhibit unique radiologic imaging characteristics [4]. These characteristics are well understood by today's radiologists and pose little concern when diagnostic imaging is required. However, recent advancements in breast implant technology have altered the imaging characteristics of breast implants [4]. Motiva Implants® (Establishment Labs Holdings Inc., NY, USA) has developed a radio frequency identification device micro-transponder (RFID-M), known as the Q Inside™ Safety Technology, as an added safety feature embedded in the shell of its breast implant. This RFID-M device allows for the rapid unique identification of implants through a three-point authentication system that provides important information about the implants manufacturing date, serial number, volume, and size. Considering that between 20 to 40 percent of augmentation patients and 40 to 70 percent of reconstruction patients undergo reoperations during the first 8 to 10 years after receiving implants [5], this method of implant identification could prove invaluable when issues of product safety or quality arise concerning a specific product lot or model.

The Q Inside™ Safety Technology RFID-M is located in the base of the implant and contains a ferrite core that exhibits a positive magnetic susceptibility artifact on MRI [4]. This susceptibility artifact may affect the routine practice of a breast

MRI interpretation as more women with these implants are routinely imaged in accordance with current FDA guidelines.

The purpose of our investigation is to determine whether the Q Inside™ Safety Technology RFID-M device in the Motiva Implants® limits the visualization of breast tissue in conventional breast imaging modalities.

2. Methods

Seven patients with Motiva Implants® were referred to dedicated diagnostic breast imaging centers for evaluation of their prostheses and surrounding breast parenchyma between January and May 2018. Imaging indications included routine evaluation of implant integrity, evaluation of significant breast symptoms, oncologic follow-up, and breast cancer screenings.

Written informed consent was obtained from all patients following the principles of the Helsinki declaration. All patients were informed of their options to refuse to participate in this small study, and all voluntarily participated. **Table 1** illustrates participant demographics as well as method of implantation.

Imaging modality and sequence collection were performed according to the unique clinical indications of each participant's presentation. Four patients received mammography with Full-field digital mammography SIEMENS Mammomat Inspiration Prime or HOLOGIC Selenia Dimensions. A 2-view mammographic exam with standard push-back and non-push back techniques was performed on these patients.

All patients had bilateral whole breast and axillary ultrasound performed by a dedicated breast sonographer in addition to real-time scanning by a breast radiologist with a CANON (TOSHIBA) Aplio i600 breast-dedicated unit using 14L5 and 18L7 high resolution probes.

5 patients received bilateral breast MRI on a SIEMENS SKYRA 3-Tesla 48-channel system with 16-channel dedicated breast coil. Both a non-contrast implant protocol and post-contrast dynamic breast parenchyma protocol were routinely performed on all patients unless otherwise indicated.

Table 1. Patients' demographic and method of surgical implantation.

Patient	Age (mean 33, 5)	Procedure	BMI (mean 22, 29)	Incision
1	57	Subpectoral Breast Reconstruction	25.51	IMF
2	20	Subpectoral Breast Augmentation	20.08	IMF
3	31	Subpectoral Breast Augmentation	19.59	IMF
4	27	Subpectoral Breast Augmentation	21.41	IMF
5	35	Subfascial Breast Augmentation	22.49	IMF
6	29	Subglandular Breast Augmentation	25.89	IMF
7	36	Subpectoral Breast Augmentation	21.05	IMF

A non-contrast implant evaluation was performed first with direct axial and sagittal high-resolution silicone-specific T1 and T2 sequences. This was followed by dynamic post-contrast subtraction sequences to evaluate the breast parenchyma. These T1 sequences were multiplanar reconstructed with maximum intensity projection and review of temporal enhancement profiles. The parameters of MRI sequences utilized are listed in **Table 2**. For dynamic imaging sequences, we use a bolus injection of 0.1 mmol/kg gadobutrol IV.

All images were reviewed and reported by one of two experienced breast radiologists with double-reporting of all breast MRIs.

3. Results

3.1. Mammography

Under mammography, the Motiva Implants® have a similar contour and mobility to other commonly used implants. The RFID-Mis not visible and produces no artifact, allowing for proper visualization and screening of all visualized parenchymal tissues. The posterior wall of implant and chest wall are not usually visualized on the mammogram as shown in **Figure 1**.

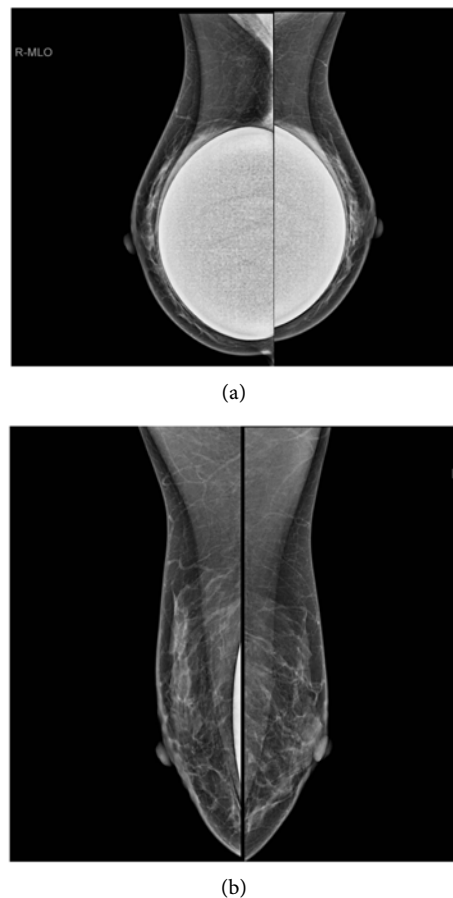


Figure 1. (a) Images of full-field digital mammography MLO views of a patient with sub-pectoral Motiva Implants® with micro transponder with push-back technique and (b) non-push back technique.

Table 2. MRI parameters and sequences used.

Sequence	Axial FSE taken from Siemens Library	Sagittal STIR with water suppression high res TIRM	Axial STIR	Axial STIR with water saturation high res TIRM	Axial STIR with Silicone suppression
TR	6120	4000	6750 ms	4880 ms	4880 ms
TE	79	65	76 ms	64 ms	64 ms
TI	-	230	230 ms	230 ms	230 ms
Slice thickness/Gap	4 mm/0.8 mm	3.5/0.35 mm	2 mm/0 mm	3 mm/0 mm	3 mm/0 mm
Matrix size (PXF)	320 × 320	256 × 256	384 × 384	326 × 384	326 × 384
Field of view	34 cm	22 cm	34 cm	34 cm	34 cm

3.2. Ultrasound

The ultrasound shows the breast tissue behind the RFID is normal. The RFID-M was not visible *in vivo*. No related ultrasound artifact was apparent within the lumen or behind the implant as shown in **Figure 2(a)**.

This *in vivo* imaging appearance contrasts with *ex vivo* imaging which showed an echogenic line produced by the 3 cm patch region around the RFID-M, as shown in **Figure 2(b)**. However, it is apparent that no ultrasound artifact deeps into this area.

3.3. Breast MRI

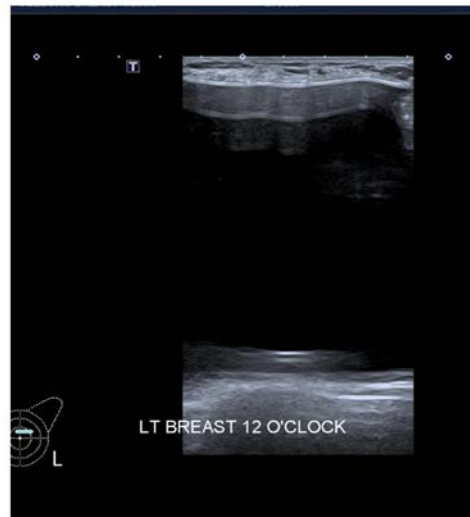
5 patients received MRI. The breast parenchyma and axillae were well-visualized in all 5 patients. The RFID-M was found to produce a “butterfly-shaped” susceptibility artifact that projects into the lumen of the breast implant and causes image distortion in some of the surrounding soft tissues and chest wall posterior to the implant. The blooming effect results in a susceptibility artifact that is larger than the RFID-M and involves approximately 20% of acquired images.

Figures 3(a)-(e) is an example of MRI patient with a history of left mastectomy with implant-based reconstruction and native right breast.

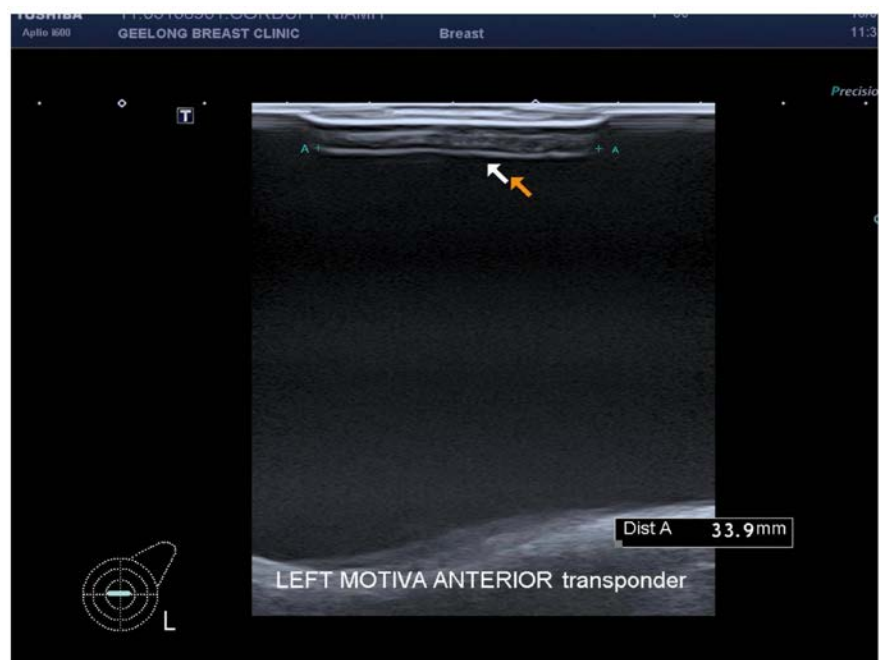Several techniques were used to minimize the susceptibility artifact created around the micro-transponder [6] [7] [8].

Magnetic susceptibility is known to be lower at 1.5 Tesla [7] [8]. However, we were unable to explore this effect in our study because of our sole access to 3T scanners fitted with dedicated breast coils. Another strategy proven to reduce magnetic susceptibility artifact is to reduce slice thickness as much as possible. Slice thicknesses for breast implant studies are routinely 2 - 3 mm for implant evaluation and 1.2 mm for axial T1-weighted post-contrast subtracted dynamic series. Substituting an inversion recovery sequence for fat suppression with dual echo Dixon for fat and water separation has also been shown to reduce the volume of susceptibility artifacts produced by metallic clips in the breast [8]. When applied to our image series we realized the same effect with the RFID-M artifact.

Choosing the smallest practical FOV to maximize in-plane resolution also reduces metallic artifact without compromising breast coverage and creating a



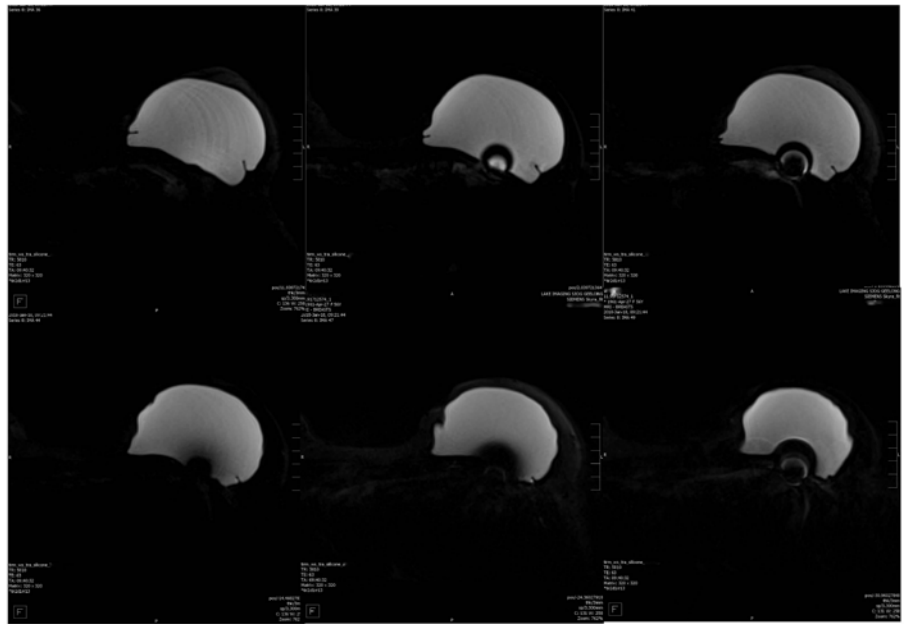
(a)



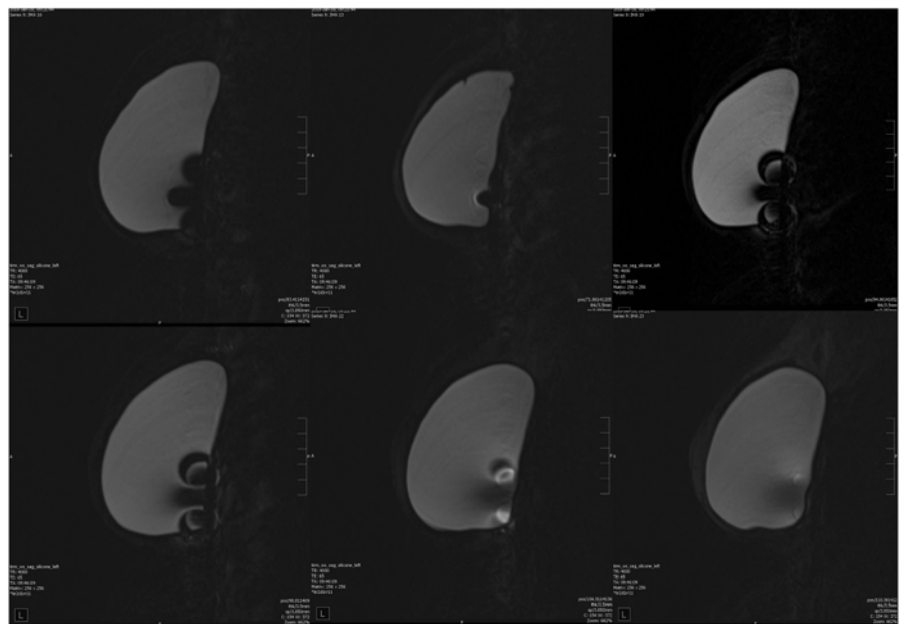
(b)

Figure 2. (a) Ultrasound of a patient with Motiva implant in vivo. Implant-based reconstruction of a 57-year-old patient after skin-sparing mastectomy for multifocal invasive breast cancer in 2015; (b) Ultrasound implant ex-vivo with RFID-Mside up shows a 33 mm echogenic linear band from the circular patch implant wall.

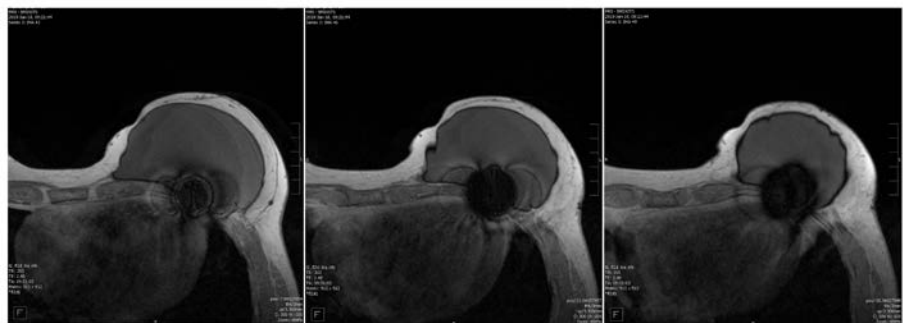wrap-around artifact. The FOV used in our study ranged from 220 mm to 340 mm. Another option for artifact reduction which is not always available is the use of metallic artifact reduction software [9]. We were unable to demonstrate the potential effect of this on the RFID-M artifacts in our study because this software was not fitted on our 3T scanner. The use of this software also significantly adds time to the study and is not feasible to use when performing the rapid dynamic post-contrast sequences necessary to evaluate breast parenchyma.



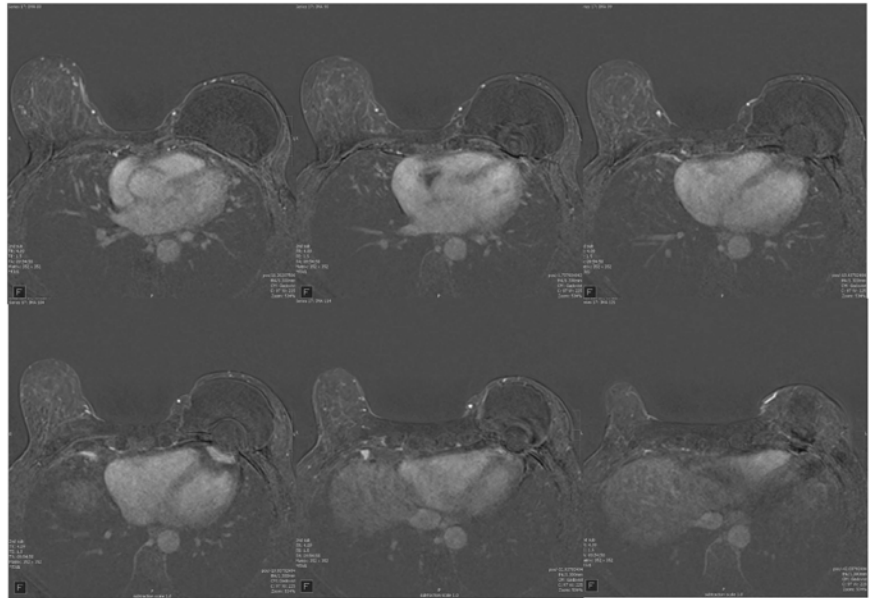
(a)



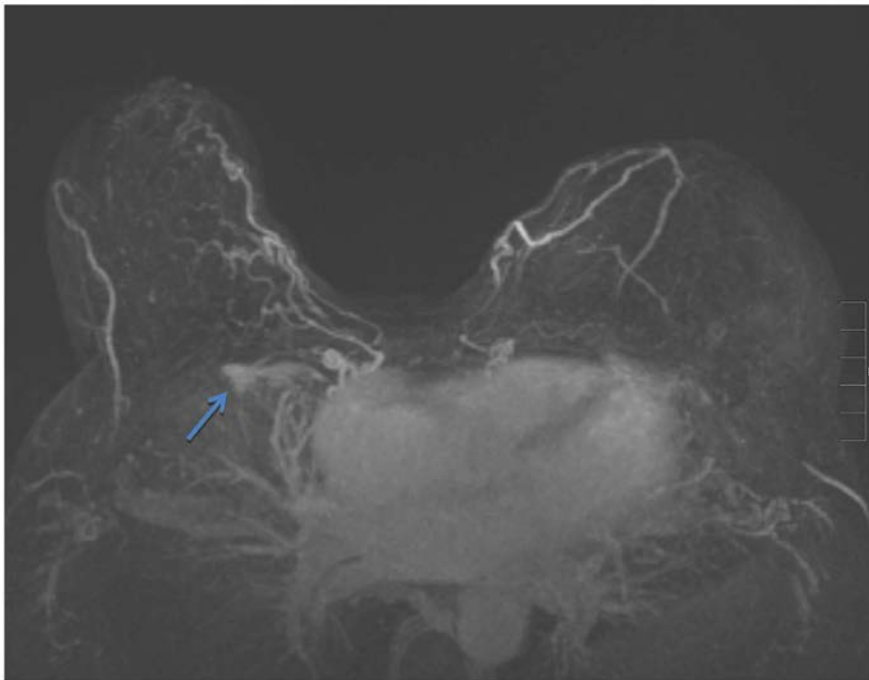
(b)



(c)



(d)



(e)

Figure 3. (a)-(e) patient with a history of left mastectomy and implant-based reconstruction using a Motiva Implant® imaged at 3T with 3 mm slice thickness. (a) High-resolution axial T2-WI TIRM water saturation 3mm slice thickness shows susceptibility artifact from the ferromagnetic RFID-M along the posterior wall; (b) High resolution sagittal T2-WI with water suppression shows the “butterfly” artifact from RFID-M in posterior wall of the implant; (c) Pre-contrast T1-WI non-fat saturation shows the appearance of butterfly susceptibility artifact over several consecutive slices; (d) Post-contrast axial T1-WI dynamic series with second subtraction shows the signal void deep to implant in the region of RFID-M; (e) Maximum intensity projection image shows mild background enhancement near the site of the RFID-M.

4. Discussion

Inclusion Criteria: All women who present for imaging with the Motiva Q Inside™ safety technology were asked to participate in this study. They could reject the study on a personal basis.

Radio frequency identification (RFID) technology has been used for decades and has experienced considerable growth in recent years, especially in relation to the multitude of applications that are being devised for it. In its most simplistic dimension, RFID devices behave much like modern bar-codes and have improved the effectiveness of supply chain management, asset control, and even drug authentication by providing a mechanism for rapid and independent identification. Many corporate and government entities have recognized the potential benefits that RFID technology can have on patient safety and outcome improvement [10]. In the medical industry, its application has been explored in several ways and is currently used in patient surveillance, lesion identification, and even in dosimetry tracking.

The demographic and mobility of women that undergo breast augmentation predisposes them to less than the perfect follow-up and leaves room for a more robust implant registry, superior to the current simple system of voluntary reporting which is susceptible to low-data capture rates [11].

The *Poly Implants Prothèse* (PIP) case has had a large socioeconomic impact at an international level, affecting nearly 400,000 patients in 55 different countries [7], and raising concerns on the regulatory and quality control procedures that failed to safeguard thousands of women from health risks associated with PIP breast implants [12].

The growing presence of implantable devices with metallic components poses new challenges to radiologists and increases the need for continuous medical education. Imaging artifacts have been extensively described for other devices such as surgical and biopsy clips [7] [13] [14]. Time-consuming artifact-reduction strategies are available for reducing susceptibility artifact in MRI [9]. However, advances in imaging modalities have provided a variety of more reliable and less time-consuming options to assess suspicious findings in and around tissue containing ferromagnetic compounds. Nelson *et al.* recently showed that breast tissue containing implants with an RFID-M can be successfully evaluated through a multi-modality approach, using tomosynthesis and/or sonography [9].

Both radiologists involved in this study agreed that the integrated RFID-M had no negative effect on image interpretation of mammography or ultrasounds in any patients. All ultrasounds in this study demonstrated good visualization of both implant and surrounding soft tissues. However, in some patients, visualization of the breast implant under ultrasound and tissues deep to the implant can be suboptimal when the implant is retro-pectoral, or when patient body habitus inhibits an optimal exam.

Alternatively, MRI is well known to be the most sensitive imaging examination for the evaluation of rupture in silicone gel breast implants. It provides a re-

liable method to assess implant integrity and is highly sensitive for the detection of both intracapsular and extracapsular rupture [15]. Ultrasound examination and MRI are often offered as diagnostic techniques and as aides to the pre- and post-operative checkup. The latest generations of breast implants contain a more highly cohesive silicone gel that is encapsulated by a stronger and denser shell. This confers the advantage of improved shape retention and a possibly lower incidence of rupture [14]. Nevertheless, a focal implant rupture could theoretically be masked if it lay in the region of the RFID-M related susceptibility artifact projecting from the posterior wall into the lumen.

From a historical perspective, mammography has been the recommended imaging tool for screening the general population for suspicious breast lesions. Full-field Digital Mammography has been progressively endorsed as the modality of choice for breast cancer screening [3]. Ultimately, 5 major medical organizations formulated the current screening guidelines in the United States mostly based on mammography indications [16]. More recently Digital Breast Tomosynthesis (DBT) was approved as a breast imaging tool and has shown great potential because it overcomes the limitations of the 2D imaging (the overlapping of breast tissue) [17].

However, a different approach is recommended for women with increased risk of breast cancer, including those with a history of breast cancer. Supplemental screening via breast MRI with contrast may be considered for special high-risk populations [14]. Although breast MRI has been shown to be effective, it is important to emphasize that breast MRI is not meant to replace mammography [18]. Moreover, the combined use of both modalities has proven to be the most cost-effective choice in some populations [19]. For these reasons, multiple modality assessments should be considered for any woman with or without Motiva Implants® and Q Inside™ Safety Technology. With easy access to ultrasound evaluation, no safety concerns should be raised keeping in mind that all breast tissue can be fully evaluated in patients with Motiva Implants using ultrasound or MRI techniques.

Of equal concern is the potential to miss a lesion located in the soft tissues behind the implant, *i.e.* the chest wall, if it lay in the signal void artifact produced by the RFID-M. This should be taken into consideration when screening patients at high risk or for follow-up post breast cancer treatment. Both radiologists involved in this study felt that breast ultrasounds should be routinely performed in these patients by experienced breast sonographers or radiologists.

Image Susceptibility artifacts associated with the presence of metal are a well-known type of artifact caused by magnetic susceptibility differences between substances ferromagnetic properties. While they cannot be eliminated entirely they can be minimized by strategically selecting pulse sequences (when possible) and utilizing optimized sequence parameters [13]. Several techniques can be used to reduce the severity of metal susceptibility artifact, such as increasing the frequency encoding bandwidth or orienting the long axis of the metal object with the frequency encoding direction [7].

Breast MRI remains the most sensitive imaging modality, and in expert hands, it is the most specific imaging tool for both breast implants and breast parenchymal evaluation. In spite of the artifact produced by the RFID-M, both radiologists in this study agreed that MRI techniques could be successfully performed in patients with Motiva Implants® containing the Q Safety Technology micro transponders.

In 2006, the U.S. Food and Drug Administration (FDA) recommended screening of all women with silicone gel breast implants with MRI three years after implantation and every two years thereafter to detect silent ruptures [20]. Yet, retrospective case reviews identified methodologic biases in prior studies that resulted in the overestimation of this imaging modalities benefit [21]. Therefore, the FDA recommendations should be interpreted with caution, taking into account other optimal and economical strategies [22]. The recently published ACR Appropriateness Criteria for breast implant evaluation considers breast MRI usually not appropriate for evaluation of silicone breast implants in asymptomatic patients despite its potential diagnostic benefits [23].

Managing symptomatic patients and those in high-risk populations requires special monitoring considerations and vigilant clinical assessment. Though the RFID-M related artifact could impede the proper visualization in the region of the chest wall, malignant and metastatic chest wall tumor diagnosis begins after taking a careful history with plain chest X-ray, followed by techniques such as chest radiography, computed tomography (CT), MRI and positron emission tomography [24]. Evidence review also supports the use of mammography for surveillance after primary breast cancer treatment [25], thus providing a variety of complementary options to examine the breast region. With these additional screening modalities being utilized it is highly unlikely that any artifact produced by the RFID-M would hinder early identification of a breast lesion in these patients.

Although compelling, the results of this study and the conclusions drawn upon them do have limitations. The primary limiting factor of this study is the small number of patients involved. Future studies will be needed to confirm our impressions with larger and more diverse patient cohorts. Additionally, studies using different and more powerful MR imaging units must be examined to determine their ability to better reduce artifact created by the RFID-M.

5. Conclusions

Aside from making its presence evident inside the implant, the Q Inside™ Safety Technology RFID-M does not interfere with the mammographic or sonographic exam, its results, or any consequent diagnosis made via their analysis. In the same respect using optimized MRI sequences to evaluate patients we were able to obtain satisfactory visualization of breast tissue in patients with the new Motiva Implants®, and recommend using optimized study protocols for both early cancer detection and assessment of the implant's integrity.

Concerning the area obscured by susceptibility artifact via MRI, the concomitant use of standard imaging modalities such as ultrasound and mammography may provide sufficient visualization of the obscured areas to accomplish a thorough radiological survey of the breast and chest wall tissues in patients with the Motiva Implants®.

Acknowledgements

We would like to thank Dr. Linda West and her team at the Geelong Breast Clinic, Lake Imaging, Victoria, Australia for acquiring the images presented in this manuscript.

Disclosure: Dr. Michael Nelson and Dr. Sina Meisamy are paid consultants from JAMM Technologies, Inca subsidiary of Establishment Labs; however, neither Dr. Nelson nor Dr. Meisamy has any conflicts of personal interests in the material and conclusions of this paper. Neither physician has any stock or ownership in ELabs or JAMM Technologies, Inc.

Conflicts of Interest

The authors declare no conflicts of interest regarding the publication of this paper.

References

- [1] 2017-2018 Plastics Surgery Statistics Report. <https://www.plasticsurgery.org/documents/News/Statistics/2017/plastic-surgery-statistics-report-2017.pdf>
- [2] FDA Update on the Safety of Silicone Gel-Filled Breast Implants. <https://www.fda.gov/downloads/medicaldevices/productsandmedicalprocedures/implantsandprosthetics/breastimplants/UCM260090.pdf>
- [3] Mackenzie, S., *et al.* (2015) Breast Cancer Screening: An Evidence-Based Update. *Medical Clinics of North America*, **99**, 451-468. <https://doi.org/10.1016/j.mcna.2015.01.002>
- [4] Fei, *et al.* (2014) Application Safety Evaluation of the Radio Frequency Identification Tag under Magnetic Resonance Imaging. *BioMedical Engineering OnLine*, **13**, 129. <https://doi.org/10.1186/1475-925X-13-129>
- [5] Oulharj, S., Pauchot, J. and Tropet, Y. (2014) PIP Breast Implant Removal: A Study of 828 Cases. *Journal of Plastic, Reconstructive & Aesthetic Surgery*, **67**, 302-307. <https://doi.org/10.1016/j.bjps.2013.12.016>
- [6] Yitta, S., Joe, B.N., *et al.* (2012) Recognizing Artifacts and Optimizing Breast MRI at 1.5 and 3 T. *American Journal of Roentgenology*, **200**, 673-682. <https://doi.org/10.2214/AJR.12.10013>
- [7] Kolind, S.H., *et al.* (2004) Quantitative Evaluation of Metal Artifact Reduction Techniques. *Journal of Magnetic Resonance Imaging*, **20**, 487-495. <https://doi.org/10.1002/jmri.20144>
- [8] Le, Y., Kipfer, H.D., *et al.* (2014) Comparison of the Artifacts Caused by Metallic Implants in Breast MRI Using Dual-Echo Dixon versus Conventional Fat-Suppression Techniques. *American Journal of Roentgenology*, **203**, 307-314. <https://doi.org/10.2214/AJR.13.10791>

- [9] Talbot, B.S. and Weinberg, E.P. (2016) MR Imaging with Metal Suppression Sequences for Evaluation of Total Joint Arthroplasty. *Radiographics*, **36**, 209-225.
- [10] Fei, X., *et al.* (2014) Application Safety Evaluation of the Radio Frequency Identification Tag under Magnetic Resonance Imaging. *BioMedical Engineering OnLine*, **13**, 129.
- [11] Martindale, V. and Menach, A. (2013) The PIP Scandal: An Analysis of the Process of Quality Control That Failed to Safeguard Women from the Health Risks. *Journal of the Royal Society of Medicine*, **106**, 173-177.
<https://doi.org/10.1177/0141076813480994>
- [12] Berry, M.G. and Stanek, J. (2012) The PIP Mammary Prosthesis: A Product Recall Study. *Journal of Plastic, Reconstructive & Aesthetic Surgery*, **65**, 697-704.
<https://doi.org/10.1016/j.bjps.2012.02.019>
- [13] Faulkner, W. (2015) Managing Metallic Artifacts in MRI.
https://www.medtronic.com/content/dam/medtronic-com/mri-surescan/document/s/Managing_Metallic_Artifacts_in_MRI.pdf
- [14] Hallet, *et al.* (2017) Imaging in Breast Implant Rupture.
<https://emedicine.medscape.com/article/345877>
- [15] Nelson, *et al.* (2018) Second Look Ultrasound and Tomosynthesis for High-Risk Patients Undergoing MRI Screening with Implants Embedded with RFID Markers.
- [16] Fiorica, J. (2016) Breast Cancer Screening, Mammography, and Other Modalities. *Clinical Obstetrics and Gynecology*, **59**, 688-709.
<https://doi.org/10.1097/GRF.0000000000000246>
- [17] Lam, *et al.* (2017) Imaging Surveillance after Primary Breast Cancer Treatment. *American Journal of Roentgenology*, **208**, 676-686.
<https://doi.org/10.2214/AJR.16.16300>
- [18] Lee, *et al.* (2010) Breast Cancer Screening with Imaging: Recommendations from the Society of Breast Imaging and the ACR on the Use of Mammography, Breast MRI, Breast Ultrasound, and Other Technologies for the Detection of Clinically Occult Breast Cancer. *Journal of the American College of Radiology*, **7**, 18-27.
- [19] Wellings, E., *et al.* (2016) Breast Cancer Screening for High-Risk Patients of Different Ages and Risk—Which Modality Is Most Effective? *Cureus*, **8**, e945.
- [20] Kuhl, C.K., Strobel, K., *et al.* (2017) Supplemental Breast MR Imaging Screening of Women at Average Risk of Breast Cancer. *Radiology*, **283**, 361-370.
<https://doi.org/10.1148/radiol.2016161444>
- [21] Chung, K.C., Malay, S. and Shauver, M.J. (2012) Economic Analysis of Screening Strategies for Rupture of Silicone Gel Breast Implants. *Plastic and Reconstructive Surgery*, **130**, 225-237. <https://doi.org/10.1097/PRS.0b013e318254b43b>
- [22] Lourenco, A.P., *et al.* (2018) ACR Appropriateness Criteria Breast Implant Evaluation. *Journal of the American College of Radiology*, **15**, S13-S25.
<https://doi.org/10.1016/j.jacr.2018.03.009>
- [23] Lin, G., *et al.* (2015) Chest Wall Tumors: Diagnosis, Treatment and Reconstruction. *Experimental and Therapeutic Medicine*, **9**, 1807-1812.
<https://doi.org/10.3892/etm.2015.2353>
- [24] Runowicz, C.D., *et al.* (2016) American Cancer Society/American Society of Clinical Oncology Breast Cancer Survivorship Care Guideline. *CA: A Cancer Journal for Clinicians*, **66**, 43-73. <https://doi.org/10.3322/caac.21319>
- [25] Senkus, E., *et al.* (2015) Primary Breast Cancer: ESMO Clinical Practice Guidelines for Diagnosis, Treatment, and Follow-Up. *Annals of Oncology*, **26**, v8-v30.
<https://doi.org/10.1093/annonc/mdv298>