



Role of Magnetic Resonance Imaging and Magnetic Resonance Spectroscopy in Evaluation of Different Types of Dementia

Abeer Salah Abd El Razek El Esawy ^{a*},
Rasha Lottfy Younis ^b, ELSayed Aly Mohamed Tag EL Din ^c
and Mahmoud Abd El Aziz Dawoud ^b

^a Ministry of Health Department, Faculty of Medicine, Tanta University, Egypt.

^b Department of Radiodiagnosis, Faculty of Medicine, Tanta University, Egypt.

^c Department of Neurology, Faculty of Medicine, Tanta University, Egypt.

Authors' contributions

This work was carried out in collaboration among all authors. All authors read and approved the final manuscript.

Article Information

DOI: 10.9734/JAMMR/2023/v35i64975

Open Peer Review History:

This journal follows the Advanced Open Peer Review policy. Identity of the Reviewers, Editor(s) and additional Reviewers, peer review comments, different versions of the manuscript, comments of the editors, etc are available here:

<https://www.sdiarticle5.com/review-history/95295>

Original Research Article

Received: 05/11/2022

Accepted: 10/01/2023

Published: 23/02/2023

ABSTRACT

Aims: The aim of this work is to study the role of magnetic resonance imaging and magnetic resonance spectroscopy in evaluation of dementia patients.

Patients and Methods: This study conducted on fifty patients referred to radio diagnosis and medical imaging department from Neuropsychiatry department at Tanta University Hospital with clinical diagnosis of different types of dementia.

Results: The grade of medial temporal lobe atrophy was higher in AD than in the other two types of dementia. Vascular lesions that fulfill these criteria were present in all patients diagnosed as VaD and their Fazekas score was 3, while patients diagnosed as AD and PDD didn't have vascular

*Corresponding author;

lesions that fulfill NINDS-AIREN criteria and Fazekas scoring of these patients did not exceed 2. Decreased NAA/Cr ratio in the posterior cingulate gyrus was less valuable in diagnosing AD when compared with elevated ml/Cr. Decreased NAA/Cr ratio in the centrum semiovale, Decreased NAA/Cr ratio in the occipital lobe.

Conclusion: MRS is complementary to MRI revealing variable underlying metabolic abnormalities in different dementia subtypes even in cases with apparently normal conventional MRI series. Elevated ml/Cr ratio in the posterior cingulate gyrus is useful indicator when assessing Alzheimer's dementia and also differentiating it from Vascular dementia and Parkinson's disease dementia. Decrease in NAA/Cr ratio in the centrum semiovale is useful indicator when assessing suspected vascular dementia. Decrease in NAA/Cr ratio in the occipital lobe is useful indicator when assessing suspected Parkinson's disease dementia.

Keywords: *Magnetic resonance imaging; magnetic resonance spectroscopy; dementia.*

1. INTRODUCTION

Dementia is characterized by a widespread impairment in cognitive and social occupational functioning. It is linked to neuropsychiatric manifestations including depression, psychosis, and behavioral issues [1].

Alzheimer's dementia (AD), vascular dementia (VaD), fronto-temporal dementia (FTD), and dementia with Lewy Bodies (DLB) account for over 90 percent of dementia cases in younger and older age groups [1].

There are additional, less prevalent forms of dementia, such as Huntington's disease, post-alcoholic dementia, Creutzfeldt-Jakob disease, progressive supranuclear palsy, multiple system atrophy, and corticobasal degeneration (CBD) [1].

Despite the fact that computed tomography (CT) scanning is useful in diagnosing Alzheimer's dementia, it has been proven to be of little value in early diagnosis and in distinguishing AD from other types of dementia [2].

In AD, magnetic resonance imaging (MRI) has been intensively studied. It demonstrates extremely early abnormalities in the hippocampus and entorhinal cortex, although it is uncertain which structure is most relevant for early diagnosis [3,4]. Also, it has been found to be of little use in distinguishing between senile dementia and late-onset Alzheimer's disease (over 80 years) [5].

CT and MRI scans of the brain are useful in diagnosing Vascular Dementia (VaD), with MRI being more sensitive in this regard than CT [6].

Absence of brain vascular lesions CT or MRI is the most essential factor in

distinguishing Alzheimer's dementia from vascular dementia [7].

In diagnosing atypical Parkinson's syndrome, MRI results are often normal, including a normal hippocampus. This discovery is significant because it allows us to distinguish this disease from Alzheimer's, the primary differential diagnosis [8].

The Magnetic Resonance Spectrometer (MRS) is a noninvasive device for measuring the chemical compositions of tissues (*in vivo*) and identifying the functional processes of various organs [9].

Magnetic resonance spectroscopy (MRS) is a very useful tool for evaluating the various types of dementia by assessing the metabolites, such as N-Acetyl aspartate (NAA), creatine (Cr), Choline (Cho), Lactate (Lac), and lipids (Lip) at the nuclear level of the brain cells. For instance, NAA is diminished in the cortical, semioval, and temporal lobes with ageing, and these methods may be useful in diagnosing neurodegenerative diseases [10].

2. MATERIALS AND METHODS

The study will be conducted on fifty patients referred to radio diagnosis and medical imaging department from Neuropsychiatry department at Tanta University Hospital with clinical diagnosis of different types of dementia. The study was conducted from 10/2015 to 10/2020

2.1 Inclusion Criteria

Any patient presenting to the radiology department in Tanta University Hospital with clinical diagnosis of dementia for fulfilling the criteria of diagnosis of each type.

2.2 Exclusion Criteria

- Patients with artificial metallic prosthesis e.g., artificial cardiac valves.
- Patients with renal failure (GFR less than 30 ml/min).
- Patients with past history of allergy from the MRI contrast media.
- Cases with mixed types of dementia.

All cases were submitted to a comprehensive history taking examination. Imaging by MRI was conducted utilizing a 1.5 Tesla MR system with a conventional head coil. In terms of imaging, standard MRI and proton magnetic resonance spectroscopy were utilized. The multi-voxel approach was utilized for proton magnetic resonance spectroscopy.

The study was conducted on thirty patients clinically diagnosed as dementia, 17 of the patients were AD dementia, 23 were vascular dementia and the remaining 10 were Parkinson disease dementia.

By conventional MRI each patient was assessed for medial temporal lobe atrophy, Fazekas scale and NINDS-ARIEN criteria for vascular lesions and for the presence of abnormal findings in the substantia nigra.

2.3 Statistical Analysis

Data were entered into the computer and analyzed using version 20.0 of the IBM SPSS software suite.

Quantitative and percentage descriptions were provided for qualitative data. Range (minimum and maximum), mean, standard deviation, and median were used to characterize quantitative data. Using a t-test on a single sample, MRS results were compared to normal values. The results of significance tests are expressed as two-tailed probability. At the 5% significance level, the acquired findings were deemed significant.

3. RESULTS

In the Alzheimer's disease, it was noted that ml/Cr ratio in the posterior cingulate gyrus was elevated in all the patients (0.62 ± 0.09 was considered as normal range value) and showed statistical significance ($P < 0.001$), while NAA/Cr ratio in the posterior gyrus was decreased in twelve out of seventeen patients (1.5 ± 0.09 was

considered as normal range value) which could be proved to be statistically significant ($P < 0.001$) (Table 1).

In Vascular dementia, it was observed that ml/Cr ratio at the posterior cingulate gyrus was normal in ALL of the cases (0.62 ± 0.09 was considered as normal range value), while NAA/Cr ratio at the centrum semiovale was decreased in twelve cases out of twenty three patients (2.14 ± 0.20 was considered as normal range value) but showed no statistical significance in comparison to controls (Table 2).

In Parkinson's disease dementia, it was observed that NAA/Cr ratio at the occipital lobe was decreased in eight patients out of ten patients (2.16 ± 0.22 was considered as normal range value). It was also noted that ml/Cr ratio at the occipital lobe was relatively decreased in all patients ($0.53-0.67$ was considered as the normal range value). These findings are statistically significant (Table 3).

3.1 Case 1

70 years old female patient was presented by Dementia.

3.1.1 MRI findings

MR imaging show involuntional brain changes in the form of diffuse symmetrical widening of the supratentorial ventricular system, as well as cortical sulci widening, and multiple deep white matter hyperintensities in the corona radiata.

MRS spectrum in the posterior cingulate gyrus using both intermediate TE=144 ms and short TE=35 ms show:

- Normal NAA level with decreased NAA/Cr ratio=1.55
- Increase ml level with increase ml/Cr ratio= 1.1

Both conventional MRI and MRS are matching with AD.

3.2 Case 2

70 years old female patient was presented with Dementia.

3.2.1 MRI findings

MR imaging show involuntional brain changes in the form of dilatation of the cortical sulci and

dilatation of the supratentorial ventricular system. There is deep white matter hyperintensities lesions in the posterior cingulate gyrus.

MRS spectrum of the posterior cingulate gyrus using intermediate TE=144 ms show:

- Decreased NAA level with decrease NAA/Cr ratio= 1.29

Beside MRS spectrum of the centrum semiovale using short TE=35 ms show:

- Normal ml level with normal ml/Cr ratio= 0.63
- Both conventional MRI and MRS are matching with Vascular Dementia.

4. DISCUSSION

In Alzheimer's dementia patients who were examined by MRS, the area of interest was posterior cingulate gyrus (PSG) and the study by Kantarci et al [11] showed similar results who reported that single- voxel MRS from the posterior cingulate gyri is sensitive to the metabolic changes in the brain of people with Alzheimer's disease dementia.

When we examined seventeen patients who were clinically suspected of Alzheimer's dementia by the MRS at the area of interest the posterior cingulate gyrus, it was observed that

ml/Cr ratio was elevated in all cases (0.62 +/- 0.09 was considered normal range value) [12], while NAA/Cr ratio was decreased in twelve out of seventeen patients (1.51 +/- 0.09 was considered as normal range value) [12].

These findings were in agreement with Kantarci et al. [13] who reported that during the pathologic progression of Alzheimer's dementia disease the first metabolic changes detected by MRS is increase ml/Cr ratio, while the decrease in NAA/Cr develops later in the course of the disease [13].

This is also in confirmation with Huang et al. [14] who suggested that concentration of NAA metabolite was significantly decreased, while ml concentration was significantly increased in Alzheimer's dementia compared with controls, and higher concentration of ml occurred in mild Alzheimer's dementia while NAA abnormalities don't occur in mild Alzheimer's dementia but during the progressive changes of the dementia.

Subcortical ischemic vascular dementia and Alzheimer's dementia have overlapped pathologies and risk factors, but the underlying neurodegenerative mechanisms are totally different; so, it's very important to identify the pathological subtype of dementia so that the appropriate therapy can be planned.

Table 1. MRS findings in Alzheimer's disease

Case number	NAA/Cr ratio in posterior cingulate gyrus	ml/Cr ratio in posterior cingulate gyrus
Min – Max	1.05 – 1.59	0.72 – 1.10
Mean ± SD.	1.50 ± 0.43	0.79 ± 0.10
Median	1.32	0.78
Normal	1.51 ± 0.09	0.62 ± 0.09
t	8.457*	29.635*
p	<0.001*	<0.001*

t: One sample t-test *: Statistically significant at $p \leq 0.05$

Table 2. MRS findings in vascular disease

Case number	ml/Cr ratio at posterior cingulate gyrus	NAA/Cr ratio at centrum semiovale
Min – Max	0.53 – 0.71	1.01 – 2.34
Mean ± SD.	0.62 ± 0.59	5.05 ± 0.47
Median	0.63	1.9
Normal	0.62 ± 0.09	2.14 ± 0.20
t	11.831*	5.114
p	<0.001*	0.995

t: One sample t-test *: Statistically significant at $p \leq 0.05$

Table 3. MRS findings in Parkinson's disease dementia

Case number	NAA/Cr ratio at the occipital region	ml/Cr ratio at the occipital region
Min – Max	0.73 – 2.38	0.16 – 0.45
Mean ± SD.	1.62 ± 0.54	0.28 ± 0.09
Median	1.60	0.26
Normal	2.16 ± 0.22	0.6 ± 0.07
t	3.157*	11.664*
p	0.012*	<0.001*

t: One sample t-test *: Statistically significant at $p \leq 0.05$

Table 4. Comparison between conventional MRI and MRS in evaluation of suspected Alzheimer's, vascular and Parkinson's disease dementia

Type of dementia	Total number of studied cases		Number of cases that shows findings in conventional MRI matching with studied type of dementia		Number of cases that shows findings in MRS matching with studied type of dementia	
	No.	%	No.	%	No.	%
Alzheimer's dementia	17	34.0	14	28.0	17	34.0
Vascular dementia	23	46.0	23	46.0	12	24.0
Parkinson's disease dementia	10	20.0	7	14.0	8	16.0

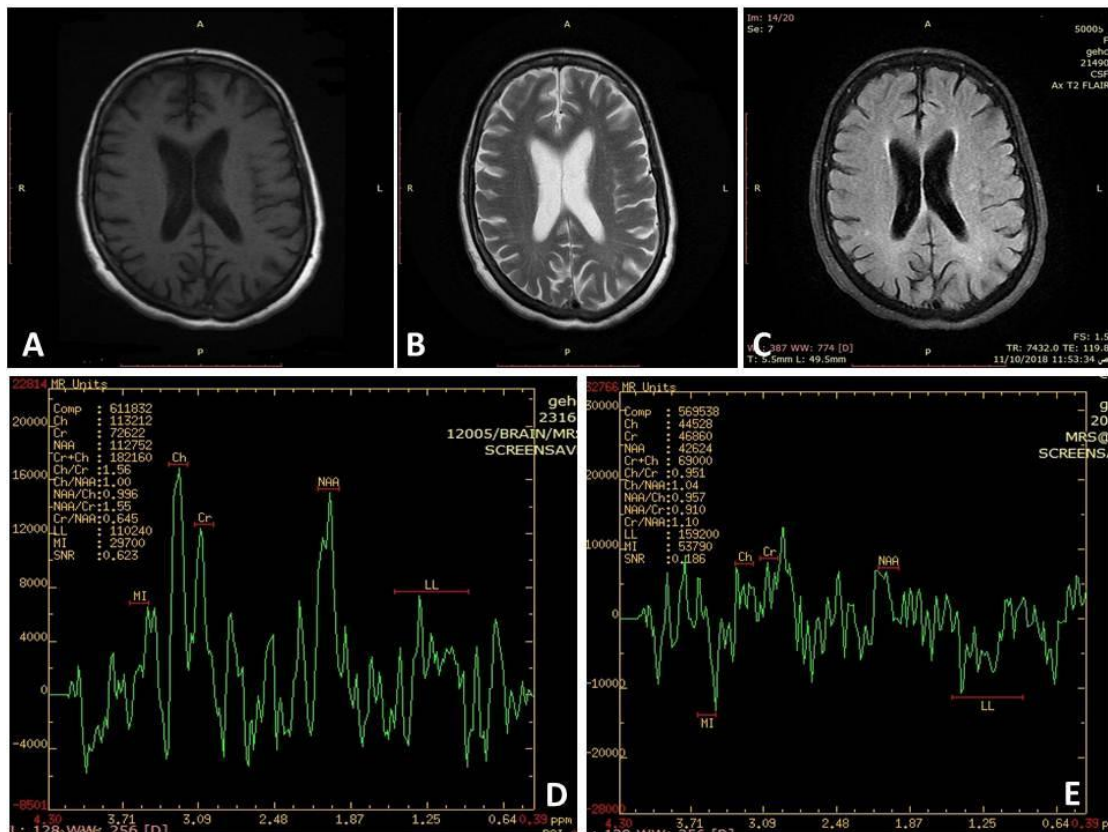


Fig. 1. (A) Axial T1w image show widening of the cortical sulci. (B) Axial T2w image show widening of the lateral ventricle. (C) Axial T2 FLAIR show minimal deep white matter hyperintensities in the corona radiata. (D) Intermediate MRS spectrum=144ms. (E) Short MRS spectrum=35 ms

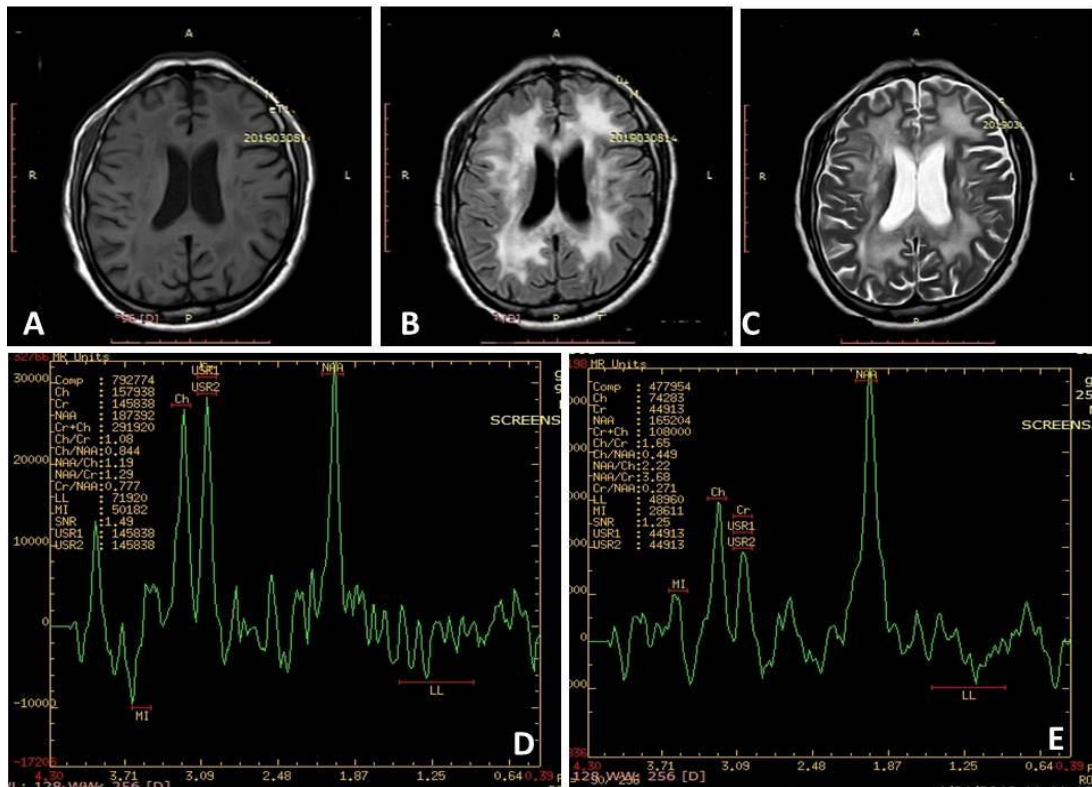


Fig. 2. (A) Axial T1W image show multiple hypointense white matter lesions. (B) Axial T2W image show multiple deep white matter hyperintense lesions and lateral ventricle dilatation. (C) Axial T2 FLAIR image shows multiple white matter hyperintense lesions beside cortical sulci dilatation. (D) Intermediate MRS spectrum TE=144 ms. (E) Short MRS spectrum TE=35 ms

On performing MRS of the vascular dementia patients the area of interest was the centrum semiovale. On examining twenty-three patients who are clinically suspected as vascular dementia and some of them with questionable alzheimer's dementia, it was found that NAA/Cr in centrum semiovale was decreased in twelve patients out of twenty-three (2.14 ± 0.20 was considered normal range value) [12]. While mI/Cr ratio in PSG was normal in all patients (0.62 ± 0.09 was considered normal range value) [12]. This was in agreement with Capizzane et al. [15] who reported that dementia and lacunes have reduced NAA/Cr ratio in the cortex that independent of atrophy and tissue composition.

On performing MRS of the Parkinson's disease dementia patients, the area of interest was the occipital lobe. In our study, it was observed that NAA/Cr ratio at the occipital lobe was decreased in eight out of ten patients suspected clinically as Parkinson's disease dementia (2.16 ± 0.22 was considered normal range value) [12], this is in confirmation with Christopher Summerfield et al. [16] who reported that in the occipital region

NAA/Cr ratio is significantly decreased in comparison with control groups.

In our study, it is observed that all the ten Parkinson's disease dementia showed relative decreased mI/Cr ratio in the occipital region ($0.53-0.67$ was considered as the normal range value) [12]. Eight out of ten cases of Parkinson's disease dementia underwent MRS of the posterior angulate gyrus and showed normal mI/Cr ratio.

Statistical analysis of metabolite ratios in our study was significant for:

- mI/Cr ratio in PSG in AD patients.
- NAA/Cr ratio in the occipital lobe in PDD patients.
- mI/Cr ratio in the occipital lobe in PDD patients.

In contrast, statistical study did not show significance the ratios:

- NAA/Cr in PSG in AD patients.
- NAA/Cr in the centrum semiovale in VaD patients.

5. CONCLUSION

In our study we can conclude that MRS is superior to conventional MRI in both Alzheimer's dementia (MRS was positive in all patients while conventional MRI was positive in fourteen out of seventeen patients) and Parkinson's disease dementia [17] (MRS was positive in eight out of ten patients while conventional MRI was positive in seven out of ten patients); on the other hand it was found that conventional MRI is superior to MRS in detecting findings of vascular dementia (conventional MRI was positive in all vascular dementia while MRS was positive only in twelve out of seventeen patients) [18].

The idea of our study is that the combination of conventional MRI and MRS is useful in diagnosis of Alzheimer's, vascular and Parkinson's disease dementia. This is in agreement with Schuff et al who found that the combination of conventional and MRS appears superior in terms of sensitivity and specificity to either measure alone.

CONSENT

As per international standard or university standard, patient(s) written consent has been collected and preserved by the author(s).

ETHICAL APPROVAL

It is not applicable.

COMPETING INTERESTS

Authors have declared that no competing interests exist.

REFERENCES

1. O'Brien J. Role of imaging techniques in the diagnosis of dementia. *British Journal of Radiology*. 2007;80(2):S71-S7.
2. O'Brien JT, Metcalfe S, Swann A, et al. Medial temporal lobe width on CT scanning in Alzheimer disease: Comparison with vascular dementia, depression and dementia with Lewy bodies. *Dementia and Geriatric Cognitive Disorders*. 2005;11(2):114-8.
3. Du AT, Schuff N, Amend D, et al. Magnetic resonance imaging of the entorhinal cortex and hippocampus in mild cognitive impairment and Alzheimer's disease. *Journal of Neurology, Neurosurgery & Psychiatry*. 2007;71(4):441-7.
4. Jack CR, Dickson DW, Parisi JE, et al. Antemortem MRI findings correlate with hippocampal neuropathology in typical aging and dementia. *Neurology*. 2002;58:750-7.
5. De Leon MJ, DeSanti S, Zinkowski R, et al. MRI and CSF studies in the early diagnosis of Alzheimer's disease. *Journal of Internal Medicine*. 2004;256(3):205-23.
6. Scheltens P, Fox N, Barkhof F, et al. Structural magnetic resonance imaging in the practical assessment of dementia: beyond exclusion. *The Lancet Neurology*. 2013;1(1):13-21.
7. Roman GC. Vascular dementia: Distinguishing characteristics, treatment, and prevention. *Journal of the American Geriatrics Society*. 2003;51(5s2):S296-S304.
8. De Vos RAI, Jansen ENH, Stam FC, et al. Lewy body disease: Clinico-pathological correlations in 18 consecutive cases of Parkinson's disease with and without dementia. *Clinical Neurology and Neurosurgery*. 2011;97(1):13-22.
9. Mandal PK. Magnetic Resonance Spectroscopy (MRS) and its application in Alzheimer's disease. *Concepts in Magnetic Resonance Part A*. 2007;30(1):40-64
10. Cady E, Joan Dawson M, Hope P, et al. non-invasive investigation of cerebral metabolism in newborn infants by phosphorus nuclear magnetic resonance spectroscopy. *The Lancet*. 2011;321(8333):1059-62.
11. Kantarci K, Reynolds G, Petersen RC, et al. Proton MR spectroscopy in mild cognitive impairment and Alzheimer disease: comparison of 1.5 and 3 T. *American Journal of Neuroradiology*. 2003;24(5):843-9.
12. Brandão LA, Domingues RC. *MR Spectroscopy of the Brain: Wolters Kluwer Health*; 2004.
13. Kantarci K, Jack C, Xu Y, et al. Regional metabolic patterns in mild cognitive impairment and Alzheimer's disease A 1H MRS study. *Neurology*. 2005;55(2):210-7.
14. Huang W, Alexander G, Chang L, et al. Brain metabolite concentration and dementia severity in Alzheimer's disease A 1H MRS study. *Neurology*. 2001;57(4):626-32.
15. Capizzano AA, Schuff N, Amend DL, et al. Subcortical ischemic vascular dementia: assessment with quantitative MR imaging and 1H MR spectroscopy. *American*

- Journal of Neuroradiology. 2000;21(4):621-30.
16. Summerfield C, Gómez-Ansón B, Tolosa E, et al. Dementia in Parkinson disease: A proton magnetic resonance spectroscopy study. Archives of Neurology. 2002;59(9):1415.
 17. Pfefferbaum A, Adalsteinsson E, Spielman D, et al. *In vivo* spectroscopic quantification of the N-acetyl moiety, creatine, and choline from large volumes of brain gray and white matter: Effects of normal aging. Magn Reson Med. 2013;41(2):276–284.
 18. Schuff N, Amend D, Ezekiel F, et al. Changes of hippocampal N-acetyl aspartate and volume in Alzheimer's disease. A proton MR spectroscopic imaging and MRI study. Neurology. 1997;49(6):1513-21.

© 2023 El Esawy et al.; This is an Open Access article distributed under the terms of the Creative Commons Attribution License (<http://creativecommons.org/licenses/by/4.0>), which permits unrestricted use, distribution, and reproduction in any medium, provided the original work is properly cited.

Peer-review history:

The peer review history for this paper can be accessed here:
<https://www.sdiarticle5.com/review-history/95295>