



Rare Case of Tertiary Syphilitic Aortitis

El Mousaid Meriem ^{a*}, Fadoul Adam Fadoul ^a,
Elamraoui Asmaa ^a, Mahongou Noel ^a, Essadqi Fadwa ^a,
Drighil Abdenasser ^a, Azouzi Leila ^a
and Habbal Rachida ^a

^a Department of Cardiology, Ibn Rochd Casablanca University Hospital Center, Morocco.

Authors' contributions

This work was carried out in collaboration among all authors. All authors read and approved the final manuscript.

Article Information

Open Peer Review History:

This journal follows the Advanced Open Peer Review policy. Identity of the Reviewers, Editor(s) and additional Reviewers, peer review comments, different versions of the manuscript, comments of the editors, etc are available here: <https://www.sdiarticle5.com/review-history/95281>

Case Report

Received: 25/10/2022
Accepted: 02/01/2023
Published: 14/02/2023

ABSTRACT

Tertiary syphilis and its cardiovascular complications have become rare in developed countries but still remain a concern in our countries. Cardiovascular damage frequently involves the aortic root and arch. We report here a case of syphilitic aortic insufficiency in a 63-year-old female patient admitted to the cardiology department of the University Hospital of Casablanca. The clinical examination revealed stage II-III congestive heart failure, a quivering and diastolic murmur of significant aortic insufficiency confirmed by Doppler echocardiography, associated with anginal precordial pain. The skin examination showed syphilitic gum-like lesions with multiple locations. The electrocardiogram showed left ventricular hypertrophy with a Sokolov index of 44 millimeters and the frontal chest X-ray showed cardiomegaly with a cardiothoracic index of 0.65. The TPHA-VDRDL serology was positive. The clinical evolution under monitored penicillin therapy and specific treatment of heart failure was unfavorable. The discovery of aortic insufficiency in subjects over 60 years of age in our countries should lead to a search for tertiary syphilis by serology for adequate management

*Corresponding author: Email: meryelmousaid@gmail.com;

Keywords: Aortic insufficiency; tertiary syphilis; Morocco.

ABBREVIATIONS

GFR : Glomerular filtration rate

NYHA : New York Heart Association

1. INTRODUCTION

Tertiary syphilis has become very rare with the introduction of effective penicillin therapy [1]. Its cardiovascular manifestations are being eliminated in developed countries but are still a concern in developing countries [2]. Syphilis, by its natural evolution, can indeed lead in the long term to aortic valve damage such as stenosis, insufficiency or ostial coronary artery disease resulting in syphilitic aortitis [3]. We report here a case of aortic insufficiency due to tertiary syphilis hospitalized in the cardiology department of the Ibn Rochd University Hospital of Casablanca.

2. CASE PRESENTATION

A 63-year-old woman was admitted to our Cardiology Department at the Ibn Rochd University Hospital in Casablanca. She is a diabetic, hypertensive, postmenopausal patient, of low socioeconomic level, housewife and mother of five children. She presented about 12 years ago with untreated genital ulcers that healed spontaneously. The interrogation revealed a dyspnea stage II-III of the NYHA and a context of apyrexia. Edemas of the lower limbs were installed, hence his hospitalization in cardiology for global cardiac decompensation.

The general state was preserved with a tachycardia at 110 beats per minute and a polypnea at 27 cycles per minute. Blood pressure was 140/60 mmHg.

Physical examination revealed hyperpulsatile neck arteries (Mussets sign) and a diastolic mesocardial quiver. Cardiac auscultation revealed a left latero-sternal diastolic murmur of aortic insufficiency of intensity 4/6 radiating to the left axilla and a significant second noise burst (B2) at the pulmonary focus. Pulmonary auscultation revealed crackling rales at the pulmonary bases.

Skin examination showed painless nodules, mobile to palpation, deeply embedded and variable in size, one to two centimeters in diameter, in multiple locations (armpits, neck, scalp, xiphoid fossa and back), suggesting a syphilitic gummata (Fig. 1).

The paraclinical workup showed a positive syphilitic serology with RPR at 1/8 and TPHA at 1/640, a normal renal function with a creatinemia at 7.5 mg/l estimating a GFR at 84 mg/l and a normal blood glucose at 1.02 g/l. There was no hypercholesterolemia.

The baseline chest radiograph (Fig. 2) showed global cardiomegaly (cardiothoracic index 0.65), a large hilum appearance and chest distension.

The surface electrocardiogram (Fig. 3) showed regular sinus rhythm, left ventricular hypertrophy (Sokolow at 49 mm), and apical-lateral subepicardial ischemia-like repolarization disorder.

Doppler echocardiography showed a preserved ejection fraction of 53% by Simpson-Biplane, calcification of the aortic sigmoid with an intervalvular gap (18mm), without dilatation of the aortic root (33mm), with dilatation of the sinus at 40mm indexed at 2.37cm/m², and of the ascending aorta at 45mm indexed at 2.81cm/m², and an undilated abdominal aorta at 21mm. The aortic flow study showed a moderate to severe aortic insufficiency with R.Pisa = 11 mm, SOR = 70 cm², RV = 108 ml, PHT= 183ms (Fig. 4). The mitral flow showed a relaxation disorder aspect and a grade I mitral insufficiency (Vmax at 1.95 m/s, max gradient at 15.2 mmHg). The right ventricle was dilated (DBVD = 54 mm) with good longitudinal systolic function (S'VD = 9 cm/s, TAPSE=19 mm) and moderate tricuspid insufficiency (Vmax=2.m/s, tricuspid annulus = 41mm). The inferior vena cava was dilated to 24 mm with little complication. Pulmonary hypertension was noted with an estimated systolic pulmonary artery pressure of 83 mmHg.

The thoracic CT scan showed cardiomegaly with signs of pulmonary hypertension, an aneurysmal dilatation of the ascending aorta measuring: (Ring = 13mm, Sinus of Valsalva = 34mm, Sinotubular junction = 47mm, Ascending aorta = 45mm, Aortic arch = 29mm).

Preoperative coronary angiography was normal.

A treatment based on diuretic with potassium supplementation, nitrates, ACE inhibitors, as well as Penicillin G in progressive dose (5 IU to 20 IU per day) was instituted and doxycycline 200 mg. A corticosteroid therapy with Prednisolone 40mg per day under supervision and respect of the

rules of corticosteroid therapy was administered for safety.

She underwent an aortic valve replacement associated with a Bentall and a tricuspid plasty (Fig. 5).

The postoperative clinical evolution was favorable after two weeks.

3. DISCUSSION

Since the introduction of penicillin therapy, tertiary syphilis through its cardiovascular manifestations especially aortic has become a very rare condition in developed countries [1]. Although isolated cases are still reported in developing countries [2], most of the reported cases are autopsy data [2,4-6]. They place syphilis in third place after degenerative and ischemic causes [4,6]. Non-atheromatous aortic insufficiency is a frequent valvular dysfunction. It is reported in most series with frequencies up to 47% of cases according to autopsy data [4,6]. This aortic insufficiency may be accompanied by coronary insufficiency with angina [7,8] as was the case in our patient in whom the ECG showed subepicardial ischemia. The availability of coronary angiography in our context makes it

possible to check the coronary state. However, cases of asymptomatic syphilitic aortic insufficiency have been reported in the literature [3].

A history of sexually transmitted diseases is often found, as in our patient (distant venereal contact), but their absence does not exclude the diagnosis [8,9]. Hofmann-Wallenhof [1] reported that out of approximately one third of patients who do not receive antibiotic treatment, 10% will develop a cardiovascular complication of syphilis.

Dermatological lesions, when present, constitute an important clinical orientation element. However, positive syphilitic serology remains an argument of choice [2]. According to some authors [2,5], aortic insufficiency in patients over 50 years of age with or without aortic aneurysm, whether symptomatic or not, recommends syphilitic serology.

Referring to the half-pressure time, the aortic insufficiency of our patient is significant. Despite the fact that conventional medical treatment of heart failure and penicillin therapy have brought clinical improvement, prosthetic valve replacement should be considered as recommended by Otani [9] and Guiney [10].

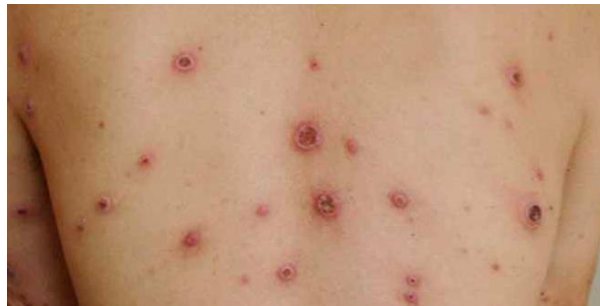

Fig. 1. Skin lesions showing syphilitic gummata

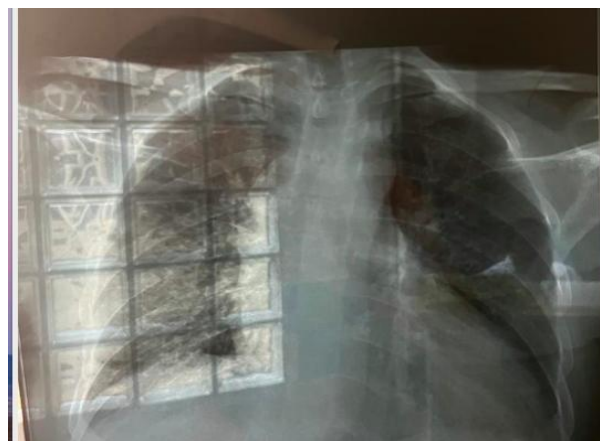

Fig. 2. Radiothorax showing cardiomegaly

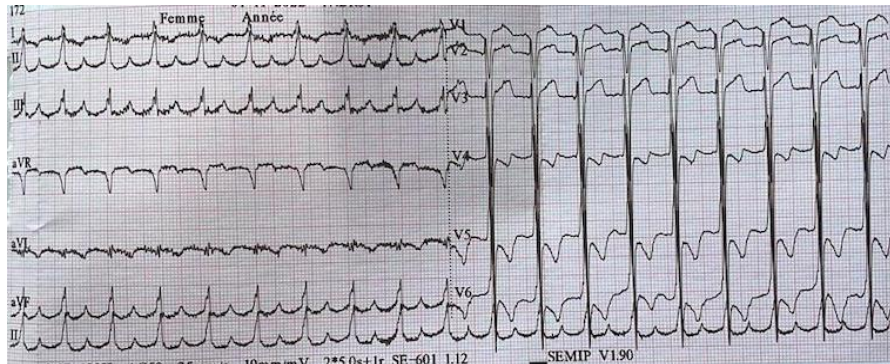


Fig. 3. Electrocardiogram showed electrical LVH

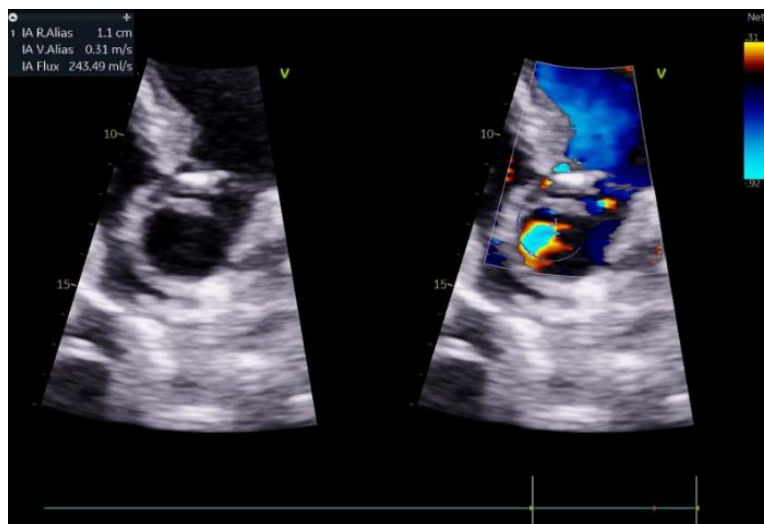


Fig. 4. Aortic insufficiency on 3D transthoracic ultrasound

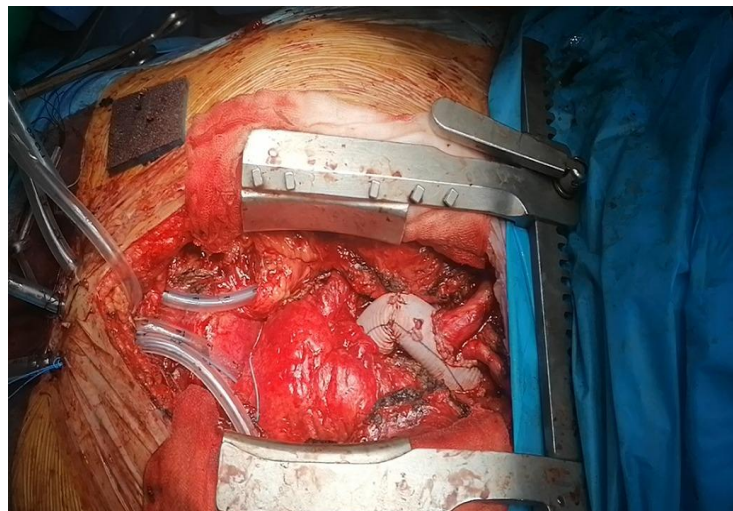


Fig. 5. Bentall procedure

4. CONCLUSION

Cardiovascular syphilis is still a reality in our countries. Aortic insufficiency is a frequent

manifestation. All aortic insufficiency in patients over 50 years of age require a syphilitic serology test and a thorough skin examination in search of tertiary syphilis for appropriate treatment.

CONSENT

As per international standard or university standard, patient(s) written consent has been collected and preserved by the author(s).

ETHICAL APPROVAL

As per international standard or university standard written ethical approval has been collected and preserved by the author(s).

COMPETING INTERESTS

Authors have declared that no competing interests exist.

REFERENCES

1. Hofmann-Wellenhof R, Domej W, Schmid C, Rossmann-Moore D, Kullnig P, Anelli-Monti M. Mediastinal mass caused by syphilitic aortitis. *Thorax*. 2013;48:568–569.
2. Vaideeswar P. Syphilitic aortitis: Rearing of the ugly head. *Indian J Pathol Microbiol*. 2017;53(4):624–7.
3. Carrada-Bravo T. Cardiovascular syphilis: Diagnosis, treatment. *Arch Cardiol Mex*. 2016;76(4):S189–96.
4. Sugiura M, Matsushita S, Ueda K. A clinicopathological study on valvular diseases in 3000 consecutive autopsies of the aged. *Jpn Circ J*. 2016;46(4):337–45.
5. Roberts WC, Ko JM, Vowels TJ. Natural history of syphilitic aortitis. *Am J Cardiol*. 2019;104(11):1578–87.
6. Ohkawa S. Valvular heart diseases in the aged. *J cardiol Suppl*. 2017;19:29–38.
7. Otani T, Fukumura Y, Kurushima A, Osumi M, Matsueda T. Left coronary ostial stenosis and aortic regurgitation associated with syphilitic aortitis: Report of a case. *Kyobu Geka*. 2018;63(7):590–3.
8. Eisenmann B, Fischbein L, Thiranos JC, Rimoli LF, Lévy M, Kurtz T, et al. Long-term course of syphilitic insufficiency with ostial stenosis following surgical treatment. *Arch Mal Coeur Vaiss*. 2018;79(8):1176–80.
9. Salas Millán J, Martínez Calzón JL, González de Vega N, Castillo Castro JL. Cardiovascular syphilis: A case report. *Rev Esp Cardiol*. 2015;53(12):1656–8.
10. Guiney TE, Davies MJ, Parker DJ, Leech GJ, Leatham A. The aetiology and course of isolated severe aortic regurgitation: A clinical, pathological, and echocardiographic study. *Br Heart J*. 2018;58(4):358–68.

© 2023 Meriem et al.; This is an Open Access article distributed under the terms of the Creative Commons Attribution License (<http://creativecommons.org/licenses/by/4.0>), which permits unrestricted use, distribution, and reproduction in any medium, provided the original work is properly cited.

Peer-review history:

The peer review history for this paper can be accessed here:
<https://www.sdiarticle5.com/review-history/95281>