



## **A Comprehensive Rehabilitation of a known Case of Leprosy Operated for Midshaft Femur Fracture**

**Laukik Vaidya<sup>1</sup>, Dushyant Bawiskar<sup>1</sup>, Prateek Upadhyay<sup>2</sup>  
and Pratik Phansopkar<sup>1\*</sup>**

<sup>1</sup>*Department of Musculoskeletal Physiotherapy, Ravi Nair Physiotherapy College, Datta Meghe Institute of Medical Sciences, Sawangi Meghe, Wardha, Maharashtra, India.*

<sup>2</sup>*Department of Orthopaedics, Jawaharlal Nehru Medical College, Datta Meghe Institute of Medical Sciences, Sawangi Meghe, Wardha, Maharashtra, India.*

### **Authors' contributions**

*This work was carried out in collaboration among all authors. All authors read and approved the final manuscript.*

### **Article Information**

DOI: 10.9734/JPRI/2021/v33i38A32089

#### Editor(s):

(1) Dr. Prabakaran Nagarajan, Ohio State University, USA.

#### Reviewers:

(1) Oksana G. Zabuga, National Academy of Medical Sciences of Ukraine, Ukraine.

(2) Kastanis Grigorios, General Hospital of Heraklion – Venizeleio, Greece.

Complete Peer review History: <https://www.sdiarticle4.com/review-history/71119>

**Case Report**

**Received 17 May 2021**

**Accepted 20 July 2021**

**Published 24 July 2021**

### **ABSTRACT**

**Background:** A persistent infection triggered by Mycobacterium leprae is also known as leprosy or Hansen's disease, transmitting by tiny droplets of the nose and mouth to the skin and peripheral nerves, producing disability. Leprosy therapy is based on the combination of the rifampicin, dispo and clofazimine (MDT) three-drug regimen. In patients who undergo hormone therapy, avascular femoral necrosis (ANFH) or femoral head osteonecrosis (ONFH) may occur, causing steroid-induced femoral head avascular necrosis (SANFH) Core decompression (CD) reduces bone pressure, opens the hardening area, prevents osteonecrosis repair, promotes blood vessel development through the tunnel for decompression, increases bone replacement and delays osteonecrosis.

**Patient information, diagnosis and therapeutic interventions:** In this case, we found a 20 years old girl known case of leprosy, was on corticosteroids for two and half years. After an increase in dosage of corticosteroids she began difficult for her walk and do her activities of daily living. She visited Acharya Vinoba Bhave Rural Hospital (AVBRH), DMIMS (DU) Sawangi Meghe, Wardha, Maharashtra, India where she got to know about necrosis of head of femur of both lower limbs. She

\*Corresponding author: E-mail: drpratik77@gmail.com;

underwent core decompression surgery of bilateral femoral head. For further management she was referred to Physiotherapy Department.

**Outcomes and Conclusion:** this case, we found that a patient who is young who had Midshaft femur fracture with interlock nailing and sever kinesiophobia, affecting rehabilitation, was able to resume her ADLs independently.

*Keywords: Leprosy; bilateral avascular necrosis of neck femur; core decompression; rehabilitation.*

## 1. INTRODUCTION

A persistent infection triggered by Mycobacterium leprae is also known as leprosy or Hansen's disease, transmitting by tiny droplets of the nose and mouth to the skin and peripheral nerves, producing disability [1]. Leprosy therapy is based on the combination of the rifampicin, dapsone and clofazimine(MDT) three-drug regimen [2].

Corticosteroids have many reverse reaction effects on the disease. Reverse reactions are immunological responses and are the main cause of disability. The standard therapy for reverse reactions is glucocorticoids [3]. In patients who undergo hormone therapy, avascular femoral necrosis(ANFH) may occur, causing steroid-induced femoral head avascular necrosis(SANFH) [4]. Avascular femoral head is also known as femoral head osteonecrosis [5], in which bone reshaping and cell death induced by insufficient blood supply [6] to head of femoral, triggers deterioration as well as associated bone cell recompense with marrow of bone, resulting to change in structure of the head of femur and head of femur collapse [5].

The non-traumatic risk factors for AVNFH include radiation therapy, haematologic problems, excessive glucocorticoid use and overuse of alcohol [6]. The symptom of these patients typically consists of pain, frequently found in their groin; this pain can impair movement (ROM), in particular passive internal rotation, dramatically

decreasing regular daily living activities and consequently the quality of life [7]. Increased blood viscosity may contribute to femoral head vasospasm, thus deficient blood oxygen in the head of femoral and then a loss of osteocyte function and cell death. Which triggers a division and area of head of femur which have microfracture in the trabecular bone which bare the weight [4].

Core decompression (CD) reduces bone pressure, opens the hardening area, prevents osteonecrosis repair, promotes blood vessel development through the tunnel for decompression, increases bone replacement and delays osteonecrosis [5].

## 2. PATIENT INFORMATION

In this case, we found a 20 years old girl with complains of tingling, numbness in limbs and itching over low back visited local hospital where she was diagnosed with leprosy. She was on corticosteroids for two and half years. After an increase in dosage of corticosteroids she began to complain of pain in both hips while walking, standing, bending forward and sit to stand activities. She visited AVBR Hospital, (MH) as the pain increased making it difficult for her walk and do her activities of daily living. She had been diagnosed with bilateral femur head avascular necrosis. She underwent core decompression of bilateral femoral head surgery. For further management, she was recommended for physiotherapy.

**Table 1. Timeline**

Events	Date
Complains of tingling, numbness in limbs and itching over low back	07/2016
Visited local hospital and Diagnosed with Leprosy, Managed with anti-Leprosy drugs and corticosteroids	07/2016
Visited AVBRH with complains of pain in both hips while walking, standing, bending forward and sit to stand activities.	19/01/2020
Diagnosed with bilateral avascular necrosis of head of femur where in right was more affected than left.	20/01/2020
Underwent core decompression surgery of bilateral femoral head.	26/01/2020
For further management, referred to physiotherapy	28/01/2020

**2.1 Findings from Clinical**

Her examination was done at same level with both shoulder in a supine lying position. Upon inspection, the patient maintains both legs abducted and a bit internally rotated, both knees supported with pillow in extended position, legs

and ankle, both ankles slightly plantar flexed. Presence of swelling on both hip & site of operation. On palpation, there was rise in temperature of local area, and oedema which was non-pitting. No failure of superficial sensations was found (pin prick, light touch and temperature and light touch).

**Table 2. Range of motion**

Joint	Lt Active	Lt Passive	Rt Active	Rt Passive	Restriction
<b>Hip</b>					
Flexion	Not-Available	Not-Available	Not-Available	Not-Available	Cannot do it because of discomfort.
Extension	Not-Available	Not-Available	Not-Available	Not-Available	Cannot do it because of discomfort.
Abduction	Not-Available	Not-Available	Not-Available	Not-Available	Cannot do it because of discomfort.
Adduction	Not-Available	Not-Available	Not-Available	Not-Available	Cannot do it because of discomfort.
<b>Knee</b>					
Flexion	Not-Available	Not-Available	Not-Available	Not-Available	Cannot do it because of discomfort.
Extension	Not-Available	Not-Available	Not-Available	Not-Available	Cannot do it because of discomfort.
<b>Ankle</b>					
Plantar Flexion	0-45 <sup>0</sup>	0-45 <sup>0</sup>	0-45 <sup>0</sup>	0-45 <sup>0</sup>	NA
Doris Flexion	0-15 <sup>0</sup>	0-15 <sup>0</sup>	0-15 <sup>0</sup>	0-15 <sup>0</sup>	NA
Inversion	0-30 <sup>0</sup>	0-30 <sup>0</sup>	0-30 <sup>0</sup>	0-30 <sup>0</sup>	NA
Eversion	0-20 <sup>0</sup>	0-20 <sup>0</sup>	0-20 <sup>0</sup>	0-20 <sup>0</sup>	NA

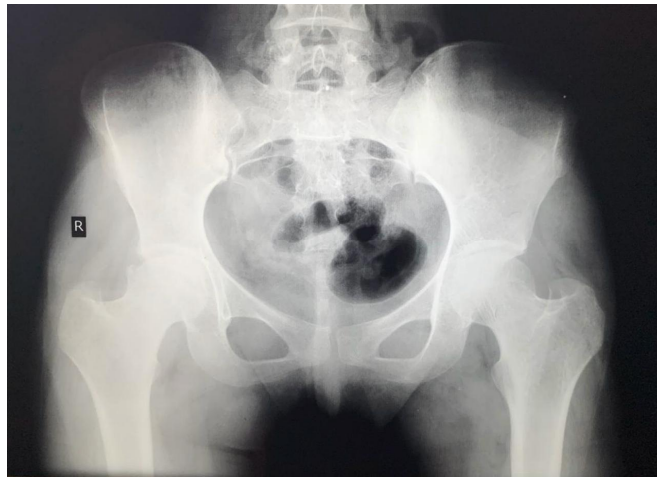**Table 3. Manual muscle testing strength**

Muscles	Right	Left
<b>Hip</b>		
Flexion of hip	3 plus	3 plus
Extension of hip	3 plus	3 plus
Abduction of hip	3 plus	3 plus
Adduction of hip	3 plus	3 plus
<b>Knee</b>		
Flexion	3 plus	3 plus
Extension	3 plus	3 plus
<b>Ankle</b>		
Plantar Flexion	3 plus	3 plus
Doris Flexion	3 plus	3 plus
Inversion	3 plus	3 plus
Eversion	3 plus	3 plus

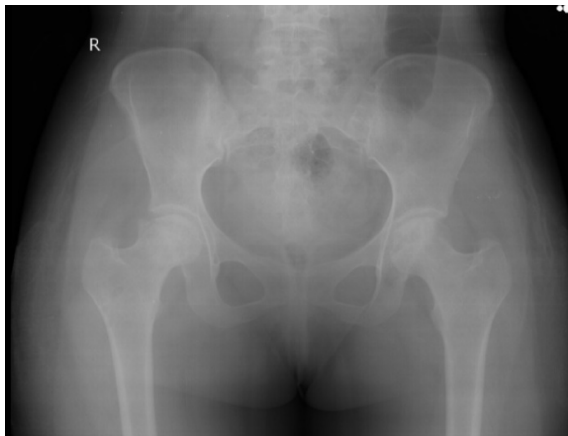**Table 4. Isometric strength**

Muscles	Right	Left
<b>Hip</b>		
Flexors of hip	Poor	Poor
Extensors of hip	Poor	Poor

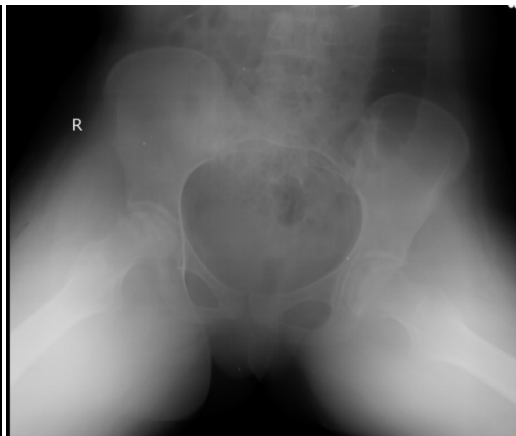
<b>Muscles</b>	<b>Right</b>	<b>Left</b>
Abductors of hip	Poor	Poor
Adductors of hip	Poor	Poor
<b>Knee</b>		
Flexors	Poor	Poor
Extensors	Poor	Poor
<b>Ankle</b>		
Plantar Flexors	Poor	Poor
Doris Flexors	Poor	Poor
Invertors	Poor	Poor
Evertors	Poor	Poor



**Fig. 1. Pre operative X-ray**



**Fig. 2. Post operative X-ray**



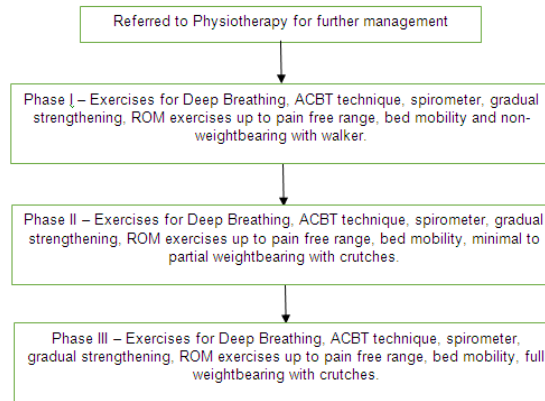
**Fig. 3. Post operative X-ray**

## 2.2 Medical Treatment

She came to AVBRH with pain as a complaint in bilateral hip, difficult for her walk and do her work of daily routine, where for the same she was admitted. MRI revealed bilateral necrosis of vessel of the head of the femur where right was more

affected than left. A dermatologist's consult was taken for tapering the dose of the drug Tab Thalidomide 100mg to 50mg and was stopped after few days. She underwent core decompression of bilateral femoral head followed by analgesics, calcium and vitamin C supplements.

## 2.3 Therapeutic Management



## 2.4 Goals

### 2.4.1 Post-operative

Air-related complications are prevented short term, pain and oedema are reduced, joint range of motion and strength is maintained and increased, early mobility is promoted, pressures are avoided, walking is encouraged, and the ADL activities are independent. The long-term objective was to support independent walking (partly/full-weight), static and dynamic bala with or without a walker.

## 2.5 Management

**Phase I (0- 3 months):** Phase I exercises emphasis on counselling, knee and hip strengthening, bed mobility and mobility of joint.

Immediately after surgery, active motion range, knee bending exercises, and lower limbs are initiated. Cryotherapy and limb elevation were frequently used to resolve effusion and oedema. In an immediate strengthening, extensor of knee with active control musculature and abductor of hip was concentrated. To Strengthen a non-weight bearing position, chain which is open practice such as removal of hip simply, flexing and extension exercises have been done. During these training workouts, attention was given to maintaining a quadriceps with complete contraction which must be powerful in a completely longer posture with the being. The knee extension was actively carried out without weight in a sitting position.

**Phase II (3-5 months):** Phase II involves exercise of Phase 1 to boost bearing wight work ,

few gear re-educating, leisure tasks and start-ups. Crutch weight bearing was tolerated with minimum to partial weight. Reinforcement to weight-bearing with minimal weight and by crutches and hand-bearing weight. More weightless exercises have been introduced, such as knee flexion and resistance bands extension.

Increasing the duration of the exercises achieved in terms of strengthening by increasing resistance with progressive resistance exercises (PRESSs). Hip reinforcement evolved by practice such as kidnapping and standing hip flexion. In addition, weight bearing advances of up to 50 percent with a support method stared at strengthening exercises such as step-ups. The knee extension and the abduction of hip movement are continued. Increased resistance and greater repetition were given to training at Phase I.

**Phase III (5-7 months):** The exercise focuses on accelerate the strength of the lower extremity through weight of partial weigh, maximum weight exercises to weight-bearing functions during phase III in order to enhance mobility, balance, proprioception, coordination and agility training. Phase II exercises proceeded according to requirement.

Stable platform practices were progressed to improve the dynamicity of stable and unstable surfaces while preparation was improved by emphasizing the need to apply more natural gear patterns. In addition to reverse walking, training gaits have been carried out with appropriate assistance to facilitate side-stepping movement. Improvements in intensity, normalization of gait and a potential transition to preferred activities.

In terms of strengthening, the duration of the exercises initiated by the improved PREs is increased. Similarly, individuals who perform task like step-up, half lung and mini squat for weight improvement up to 100% with or without crutches. Lateral walking with resistance is the advanced techniques used for the hip abduction strengthen in close chain exercise.

In weight bearing with or without aids the balance and proprioception training were advanced as one-legged activities. Strong Platform exercises on solid and unstable surfaces with the transition from static balancing to more dynamic one-leg exercises during recovery with focus put on a more natural gait style.

### 3. DISCUSSION

In this case report, we found that a young girl who had leprosy and was on corticosteroid suffered with bilateral avascular necrosis of head of femur. Aim of the rehabilitation is based on the bilateral core decompression done, beginning from low intensity exercises to gradual strengthening and partial to total weight bearing with crutches. All the exercises were done three times a day of 10 sets each. With the help of rehabilitation programme, she was able to resume her ADLs independently.

We encouraged the strengthening of the gluteal muscles and quadriceps [7,8] in the hip joint to preserve the strength of the muscles.

We focused on the muscles of gluteal group, as it is essential during gait in hip stability [9]. Activation of the hamstring prior gluteal muscle group results in hip instability and anterior hip muscles. Abductor force contributions are needed prevent pelvic tilt. The prime mover will be iliopsoas muscle, TFL and rectus femoris are activated in very less amount.

ROM exercises are performed in the early stages immediately after the surgery [10]. These exercises are proceeded slowly throughout the late stage. Hence, we worked on ROM exercises, which were encouraged from early stage.

As both lower limbs were involved, we did not choose initial weight bearing during the first 3 months of post-surgery [11], whereas quadriceps isometric contraction exercise became essential to prevent muscle atrophy.

Few studies on fractures of lower extremities were reviewed [12-14]. Bukhari et. al. conducted study of clinico-radiological outcome assessment in proximal femoral fractures treated with proximal femoral nail [15]. Dhankar and Bele reported a case of fracture shaft femur in a patient with transtibial amputation [16-18]. Some articles on Global injury studies were reviewed [19-21].

### 4. CONCLUSION

In this case study a young leprosy girl, who had secondary bilateral femoral head avascular necrosis, arising from the corticosteroids that were used for leprosy treatment and impaired recovery. The recovery program consisted of a target-based therapy program that decreased postoperative pain, oedema, increases energy, range and enhanced patient responsiveness. She was able to resumed daily living activities (ADLs) voluntarily with the help of regular rehabilitation.

### 5. LIMITATIONS

Early weight bearing was delayed as she underwent core decompression for bilateral hip for avascular necrosis.

### CONSENT

The patient included in the study received informed consent.

### ETHICAL APPROVAL

As per international standard or university standard written ethical approval has been collected and preserved by the author(s).

### COMPETING INTERESTS

Authors have declared that no competing interests exist.

### REFERENCES

1. Van Veen NH, Nicholls PG, Smith WCS, Richardus JH. Corticosteroids for treating nerve damage in leprosy. In: The Cochrane Collaboration, editor. Cochrane Database of Systematic Reviews [Internet]. Chichester, UK: John Wiley & Sons, Ltd; 2016 [cited 2020 Jul 11]. p. CD005491.pub3.

- Available:<http://doi.wiley.com/10.1002/14651858.CD005491.pub3>
2. Perez-Molina JA, Arce-Garcia O, Chamorro-Tojeiro S, Norman F, Monge-Maillo B, Comeche B, et al. Use of methotrexate for leprosy reactions. Experience of a referral center and systematic review of the literature. *Travel Med Infect Dis.* 2020;101670.
  3. Yuniati R, Khrisna MB. Glucocorticoids in Leprosy Reversal reaction. *Serbian J Dermatol Venereol.* 2019;11(3):77–83.
  4. Li H, Meng D, Zhang X, Yuan D. Effect of psoralen on the expression of PPAR $\gamma$ , osteocalcin, and trabecular bone area in rabbits with steroid-induced avascular necrosis of the femoral head. *J Orthop Surg.* 2019;14(1):11.
  5. Hua K, Yang X, Feng J, Wang F, Yang L, Zhang H, et al. The efficacy and safety of core decompression for the treatment of femoral head necrosis: a systematic review and meta-analysis. *J Orthop Surg.* 2019;14(1):306.
  6. Economopoulos DG, Triantafyllopoulos IK. Minimally invasive treatment of femoral head avascular necrosis in a beta thalassemia carrier. A case-report. 2017;5.
  7. D'Ambrosi R, Biancardi E, Massari G, Ragone V, Facchini R. Survival Analysis after Core Decompression in Association with Platelet-Rich Plasma, Mesenchymal Stem Cells, and Synthetic Bone Graft in Patients with Osteonecrosis of the Femoral Head. *Joints.* 2018;06(01):016–22.
  8. Grassi M, Salari P, Massetti D, Papalia GF, Gigante A. Treatment of avascular osteonecrosis of femoral head by core decompression and platelet-rich plasma: a prospective not controlled study. *Int Orthop.* 2020;44(7):1287–94.
  9. Wahoff M, Dischiavi S, Hodge J, Pharez JD. Rehabilitation After Labral Repair And Femoro-acetabular Decompression: Criteria-Based Progression Through The Return To Sport Phase. 2015;14.
  10. Aoyama T. Rehabilitation Program after Cell Therapy for Treatment of Femoral Head Osteonecrosis: A Narrative Review of Literature. *Int J Phys Med Rehabil [Internet].* [cited 2020 Jul 11]. 2016;4(4). Available:<https://www.omicsonline.org/open-access/rehabilitation-program-after-cell-therapy-for-treatment-of-femoral-head-osteonecrosis-a-narrative-review-of-literature-2329-9096-1000354.php?aid=77329>
  11. Yang P, Bian C, Huang X, Shi A, Wang C, Wang K. Core decompression in combination with nano-hydroxyapatite/polyamide 66 rod for the treatment of osteonecrosis of the femoral head. *Arch Orthop Trauma Surg.* 2014;134(1):103–12.
  12. Khan K, Dhaniwala N, Chitriv YU. “Outcome analysis of pelvic fractures in tertiary care health centre.” *European Journal of Molecular and Clinical Medicine.* 2020;7(7):1856–59.
  13. Jr BFP, Federico R. Tewes. What attorneys should understand about Medicare set-aside allocations: How Medicare Set-Aside Allocation Is Going to Be Used to Accelerate Settlement Claims in Catastrophic Personal Injury Cases. *Clinical Medicine and Medical Research.* 2021;2(1):61-64. Available:<https://doi.org/10.52845/CMMR/2021v1i1a1>
  14. Awasthi A, Saoji K, Palsodkar P. “To study the outcome/analysis of fracture distal end radius managed with antegrade k/l-Wire Fixation.” *International Journal of Current Research and Review.* 2020;12(22):S-137-S-139. Available:<https://doi.org/10.31782/IJCRR.2020.SP68>.
  15. Bhatt P, Nikose S, Bapat AV. “Functional and radiological evaluation of the management of tibial plateau fractures.” *International Journal of Current Research and Review.* 2020;12(22):102–4. Available:<https://doi.org/10.31782/IJCRR.2020.SP73>.
  16. Daniel V, Daniel K. Perception of nurses' work in psychiatric clinic. *Clinical Medicine Insights.* 2020;1(1):27-33. Available:<https://doi.org/10.52845/CMI/2020v1i1a5>
  17. Bukhari RR, Ambade R, Palsodkar P. “A prospective study of clinico-radiological outcome assessment in proximal femoral fractures treated with proximal femoral nail.” *European Journal of Molecular and Clinical Medicine.* 2020;7:71861–67.
  18. Dhankar S, Bele A. “A case of fracture shaft femur in a patient with transtibial amputation.” *Journal of Datta Meghe Institute of Medical Sciences University.* 2019;14(4):394–96. Available:[https://doi.org/10.4103/jdmimsu.jdmimsu\\_190\\_19](https://doi.org/10.4103/jdmimsu.jdmimsu_190_19).
  19. James SL, Castle CD, Dingels ZV, Fox JT, Hamilton EB, Liu Z, Roberts NLS, et al.

- “Global injury morbidity and mortality from 1990 to 2017: Results from the Global Burden of Disease Study 2017.” *Injury Prevention*. 2020;26(1):196–114.  
Available:<https://doi.org/10.1136/injuryprev-2019-043494>.
20. Daniel V, Daniel K. Exercises training program: It's effect on muscle strength and Activity of daily living among elderly people. *Nursing and Midwifery*. 2020;1(01):19-23.  
Available:<https://doi.org/10.52845/NM/2020v1i1a5>
21. Lozano R, Fullman N, Mumford JE, Knight M, Barthelemy CM, Abbafati C, Abbastabar H, et al. “Measuring universal health coverage based on an index of effective coverage of health services in 204 countries and territories, 1990–2019: A Systematic Analysis for the Global Burden of Disease Study 2019.” *The Lancet*. 2020;396(10258):1250–84.  
Available:[https://doi.org/10.1016/S0140-6736\(20\)30750-9](https://doi.org/10.1016/S0140-6736(20)30750-9).

---

© 2021 Vaidya et al.; This is an Open Access article distributed under the terms of the Creative Commons Attribution License (<http://creativecommons.org/licenses/by/4.0>), which permits unrestricted use, distribution, and reproduction in any medium, provided the original work is properly cited.

*Peer-review history:*

*The peer review history for this paper can be accessed here:*  
<https://www.sdiarticle4.com/review-history/71119>