



Codeine Substitute Challenges Drug and Substance Abuse Controls in Nigeria: Histopathology Evaluations of *Norvegicus rattus* on Lacatomtom

Nnaemeka Okorie ^a, Emmanuel Ifeanyi Obeagu ^{b*},
Olayinka Catherine Adeniran ^c, Azi Simon Onyema ^a
and Ude, Ugomma Agwu ^a

^a Department of Medical Laboratory Science, Faculty of Health Sciences and Technology,
Ebonyi State University, Abakaliki, Ebonyi State, Nigeria.

^b Department of Medical Laboratory Science, Kampala International University, Western Campus,
Uganda.

^c School of Medical Laboratory Sciences, Ahmadu Bello University Teaching Hospital (ABUTH),
Zaria, Kaduna State, Nigeria.

Authors' contributions

This work was carried out in collaboration among all authors. All authors read and approved the final manuscript.

Article Information

DOI: 10.9734/JOCAMR/2022/v19i130366

Open Peer Review History:

This journal follows the Advanced Open Peer Review policy. Identity of the Reviewers, Editor(s) and additional Reviewers, peer review comments, different versions of the manuscript, comments of the editors, etc are available here: <https://www.sdiarticle5.com/review-history/90436>

Original Research Article

Received 22 June 2022
Accepted 13 August 2022
Published 19 August 2022

ABSTRACT

Codeine substitute challenges to drug and substance abuse controls in Nigeria: Histopathology evaluations of *Norvegicus rattus* on lacatomtom is novel research that aimed to evaluate the Codeine substitute challenges to drugs and substance abuse; histopathology perspective and oxidative biomarkers evaluation of the tissues cum chemical pathology analysis of the serum of the control and intervened subjects. The experimental subjects were grouped into control, acute and chronic (T1, T2, and T3) respectively; the acute groups of the oral administration of lacatomtom mixture were given 0.01mg/g of lacatomtom for 14 days while the chronic were given for 42 days and periodically weighed and recorded; The Animals were sacrificed and the organs harvested following ethical procedures for animal killing. The blood and tissues of the harvested organs (blood, lungs, liver, and kidney) under investigation were subjected to chemical pathology analysis

*Corresponding author: E-mail: emmanuelobeagu@yahoo.com;

to assess the liver and kidney functions, then proceeded to histopathological examination using formalin fixed paraffin processed methods with both routine and special stains, liver, lungs and kidney homogenate were subjected to oxidative stress biomarkers test (MDA, SOD, Gpx, GSH and Catalase). Histopathology results first revealed a severe cellular injury in all the organs under study compare to the normal control; significance ($p < 0.5$) elevation found among some enzymes AST, ALP ALT are also an indication of damaged liver, increase MDA and reduced SOD, Gpx, GSH and catalase correlate the histology results and biochemistry.

Keywords: Codeine substitute; drug; substance abuse; histopathology; *Novegius rattus*; lacatomtom.

1. INTRODUCTION

La casera soft drink is non-alcoholic, flavoured, carbonated beverage commercially prepared and sold in Nigerian markets, shops, fast food joints and hawkers along major roads to the desires of travelers among millions of its consumers, usually it is commercially prepared and sold in plastic bottles. Examples of such soft drinks include Coca-cola products: Coke, Fanta, Sprite; Mountain Dew, La Casera among others. It was launched in 2009 and is a flagship brand of the La Casera Company Plc [1].

In Southwest Nigeria, Olley [2] found that 47% of the respondents (University students) smoked dried pawpaw leaf to get high. In Southeast Nigeria, Dumbili et al. [3] reported that young adult interviewees (University undergraduates and graduates) used Gutter-Water (a cocktail of tramadol, cannabis, codeine, and vodka) and Monkey-Tail (a cocktail of locally-produced gin, cannabis seeds, leaves, stems, and roots). The study also revealed the use of a mixture of 'La Casera Apple Drink (carbonated soft drink) and 'Tom-Tom' (menthol-flavoured candy) to get high (Lacatomtom) [4]. According to Dumbili et al. [3], the motivations for taking these substances include heightening and prolonging intoxication and pleasure. In the North, Danjuma et al. (2015) examined the awareness of nonconventional use of substances among 204 youth. They found that 87% were aware that Northern youth smoke lizard waste, dry pawpaw leaf and seeds, Zakami (*Datura metel*) seeds, Moringa (*Zogale*) leaf, mandrakes, and also inhale/sniff hydrogen sulphide gas (sewer gas), nail polish, gun powder, amongst others as psychoactive substances. Furthermore, 40.5% stated that their friends or acquaintances use these substances (Danjuma et al. 2015). Aside from the BBC report on the codeine/dextromethorphan-containing cough syrup epidemic in the Northern Nigeria, other local and international media outlets have reported the use of plant-based and non-classical substances among young Nigerians

and the associated poor mental health. For instance, some young people sniff/snort pit toilets or sewages and smoke the white part of lizard faeces and cobwebs, searching for 'chemical' or 'pharmacological' bodily effects [5]. BBC News Pidgin reportage of the National Drug Law Enforcement Agency's (NDLEA) media chat shows that aside from dry pawpaw leaf, people also smoke cassava and plantain leaf, spirogyra, and dry human faeces [5]. The report also highlighted that some inhale burnt tyres, while others drink a mixture of bleach (sodium hypochlorite solution) and carbonated soft drinks and 10-day-old urine for psychoactive effects. Both media reports [5] and empirical research [3] have revealed the harm associated with the use of these non-classical substances in the country, in that some users of Gutter-Water have died from drug overdoses.

2. MATERIALS AND METHODS

2.1 Study Area

This research was carried out in Animal House of Ebonyi State University Abakaliki, Histopathology Department Federal Teaching Hospital Abakaliki, Nigeria.

2.2 Sample Size Estimation

Resource Equation method (E) was used for the sample size estimation; the formula is:

$$E = (\text{Total number of animals in a group} \times \text{number of groups}) - \text{Number of groups as reported by Nnaemeka et al, [6].}$$

Inclusion criteria: Eligibility of the subjects includes; healthy *Rattus norvegicus*, body weight between 150g to 200 g and must be male *Rattus norvegicus*.

Exclusive criteria: Other species of rats except *Rattus norvegicus*, non-healthy *Rattus norvegicus*, and body weight below 150g or above 200 g were excluded in this study.

2.3 Experimental Animal

Twenty-one (21) *Rattus norvegicus* with average weight of 275 g was procured from the central animal house of the College of Health Sciences of Ebonyi State University, Abakaliki, were all housed in Histopathology laboratory, allowed to acclimatize to the standard laboratory conditions [6].

2.4 Experimental Design

The experimental subjects were grouped into three (T1, T2 and T3) which are normal control (group without any intervention), Acute and chronic oral administration of lacatontom 'gigabyte' solution respectively. Each of the groups contains seven replicate of the subjects and each subject in the intervention groups were given 0.01mg/g twice daily for 21 and 42 days for acute and chronic administration respectively with body weight obtained in each of the subjects in the group. The animals were all in their individual cages throughout the period of study till termination.

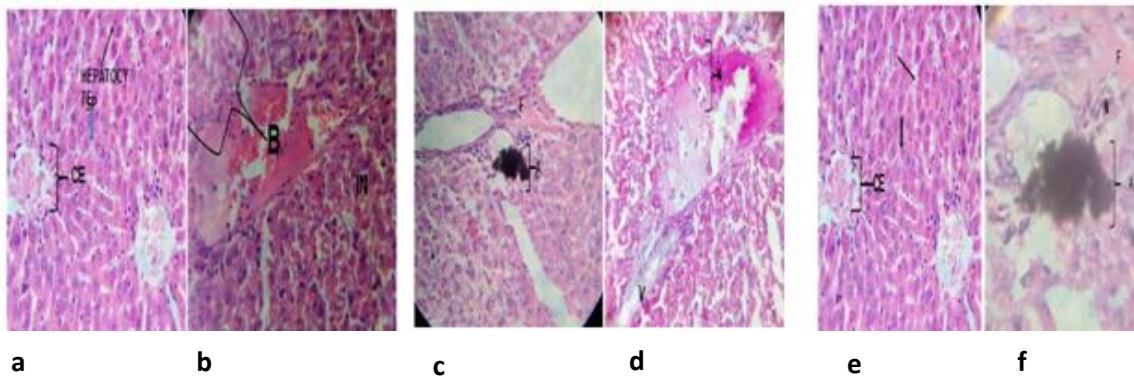
2.5 Sacrifice and Collection of Samples

The animals were anaesthetized using chloroform vapour in an enclosed transparent plastic jar, bloods were collected in plain container through cardiac puncture for chemical pathology analysis dissected to remove the Liver, kidney and lung; parts were fixed in 10% Buffered formal saline for histopathological evaluation, others then homogenized to demonstrate oxidative stress biomarkers using standard methods [6].

2.6 Laboratory Analysis

Liver, lungs and kidney specimens were grossed into triplicates, processing using conventional paraffin wax methods, using automatic Tissue Processor and embed using standard embedding Centre, sectioned and stained using both routine and special stained, oxidative stress biomarkers were done using standard method [6].

3. RESULTS



Plates 1a and b. Liver section of *Norvegicus rattus* on acute administration of la casera tomtom mixture and its control

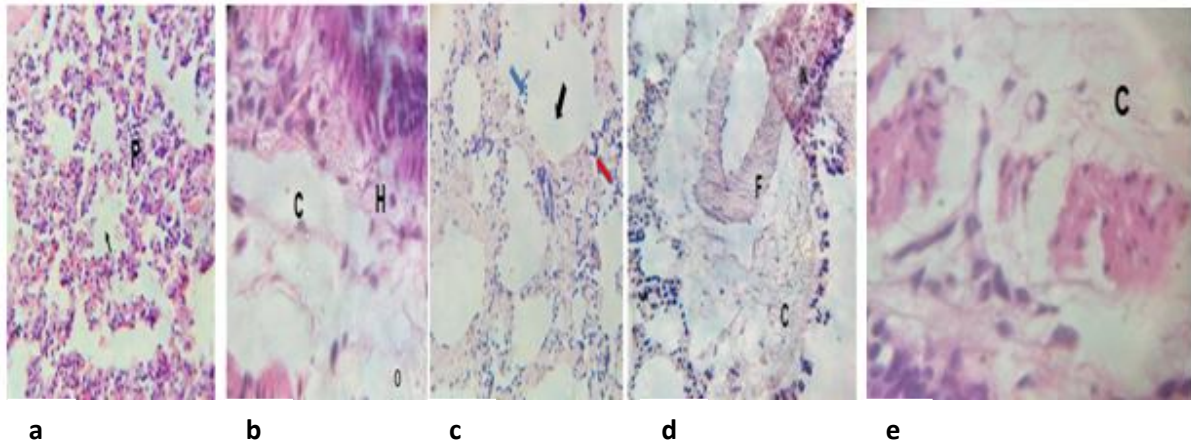
Plate 1 a Mag. X40 is a negative control liver section of *Norvegicus rattus* stained with H&E; The central vein (CE). Hepatocytes (black arrow) and the sinusoidal space SP (black arrow) are all well demonstrated and appeared normal. Plate 1b Mag. X40 is a liver section of same specie as in plate 1a on acute La casera tomtom mixture; section revealed ballooning (B) of hepatocyte as a manifestation of apoptosis (necrosis) and pink fibrin (IN) deposition occluding the sinusoidal space. The increase of serum AST and ALT observed also shown the level of hepatic necrosis seen.

Plates 1c and 1d. Liver sections of *Norvegicus rattus* on chronic administration of la casera tomtom mixtures

Plate 1c Mag. X40 is a liver section of *Norvegicus Rattus* on chronic oral administration of la casera tomtom mixture stained with H&E; walls of the portal triad shown hemorrhagic with dark stained deposition (A) and fibrotic tissues shown a great level of cirrhosis (F) with infiltrating polymorphs. Plate 1d Mag. X40 is a liver section of *Norvegicus Rattus* on chronic La casera tomtom mixture stained with periodic acid Schiff. The section shown congested with vacuolated cells (V) (necrosis) and the central vein are filled with red cells deposition and infiltrating neutrophils (N).

Plates 1e and f. Liver sections of *Norvegicus rattus* on chronic administration of la casera tomtom mixture and its control

Plate 1e Mag. X40 is a negative control liver section of *Norvegicus Rattus* stained with H & E, the central vein CE, sinusoidal space (Thin black arrow) and hepatocytes (Thick black arrow) are all well demonstrated and appeared normal. Plate 1f Mag. X40 is a liver section of *Norvegicus Rattus* on oral chronic administration of la casera tomtom mixture; the section shown moderately cirrhosis or fibrosis (F) of tissues and heavy infiltrating neutrophils (N). Necrotic dark appearance of hemorrhagic vessels (A) and cellular vacuolation are seen.



Plates 2a and b. Lungs sections of *Norvegicus rattus* on acute administration of la casera tomtom mixture and its control

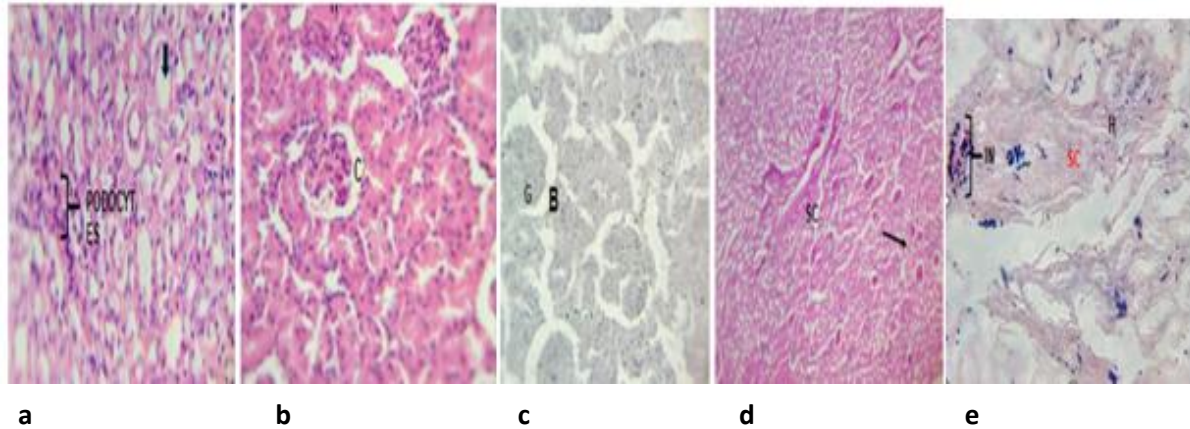
Plate 2a Mag.X10 is a negative control lung tissue section of *Norvegicus Rattus*; it shown the normal alveoli spaces and pneumocytes. Plate 2b Mag. X40 is lung section of *Norvegicus Rattus* on acute administration of la casera tomtom mixture; the section shown a collapsed congested alveoli wall (C), honeycombed appearance of distorted pneumocytes with edematous background (o).

Plates 2c and 2d. Lungs sections of *Norvegicus Rattus* on chronic administration of la casera tomtom mixture and its control

Plate 2c Mag. X10 is a negative control lung tissue section of *Norvegicus Rattus* stained with phosphotungstic acid hematoxylin; section shown the normal alveoli air spaces (black arrow), Type I pneumocytes (blue arrow), and type II pneumocytes (red arrow) all the histological cellular pattern appeared normal. Plate 2d Mag. X10 is a lung tissue section of *Norvegicus Rattus* on chronic administration of la casera tomtom mixture; the section shown a collapsed congested alveoli wall (C), honeycombed appearance of distorted pneumocytes with edematous background and fibrotic collagenous deposition (F) congesting the alveoli walls, seen also are inflammatory cells infiltrating the alveoli (IN).

Plate 2e. Lungs sections of *Norvegicus rattus* on chronic administration of la casera tomtom

Plate 2e Mag. X40 is a lung section of *Norvegicus rattus* on chronic oral administration of la casera tomtom mixture the section shown; collapse congested alveoli wall (C), honeycombed appearance of distorted pneumocytes with edematous background consistence with atypical respiratory distress.



Plates 3a and b. Kidney sections of *Norvegicus rattus* on acute administration of la casera tomtom mixture and its control

Plate 3a Mag. X40 is a negative control kidney section of a *Norvegicus Rattus* stained with H&E; section shown collecting ducts (black arrow) and podocytes and all appeared normal. Plate 3b is same specie as in plate 4.3a on acute oral administration of la casera tomtom mixture; section shown hyaline droplet in the glomerular tuft (H) with inflammatory cells, clear capsular spaces were seen.

Plates 3c and 3d. kidney sections of *Norvegicus Rattus* on chronic administration of la casera tomtom mixture and its control

Plate 3c Mag. X40 is a negative control kidney tissue section stained with methenamine silver stain; section revealed glomerular contents and capsular spaces that appeared normal. Plate 3d is a kidney section of *Norvegicus Rattus* on chronic La casera tomtom mixture administration stained with periodic acid Schiff, section shown extensive glomerular hyalinization with moderate renal sclerosis (SC), the numerous present of red blood cells (black arrow) is evidence of inflammatory lesion.

Plates 3e. Kidney section of *Norvegicus rattus* on chronic oral administration of la casera tomtom mixture stained with phosphotungstic acid hematoxylin

The plate 3e Mag. X40 is a kidney section of *Norvegicus Rattus* on chronic oral administration of la casera tomtom mixture stained with phosphotungstic acid hematoxylin. The section shown hyalinization of glomerular tuft (H), thick sclerosis of the glomerular capillaries (SC) and infiltrating neutrophils (IN) inflammatory cells.

Effects of lacasara-tomtomb mixture on oxidative stress markers in *Norvegicus rattus* liver:

Acute oral administration of La casera tomtomb mixture on *norvegicus rattus* significantly ($p < 0.05$) elevated the level of MDA and significantly ($p < 0.05$) reduced the activities of catalase, SOD, GPx and level of GSH in rat lung in time dependent manner.

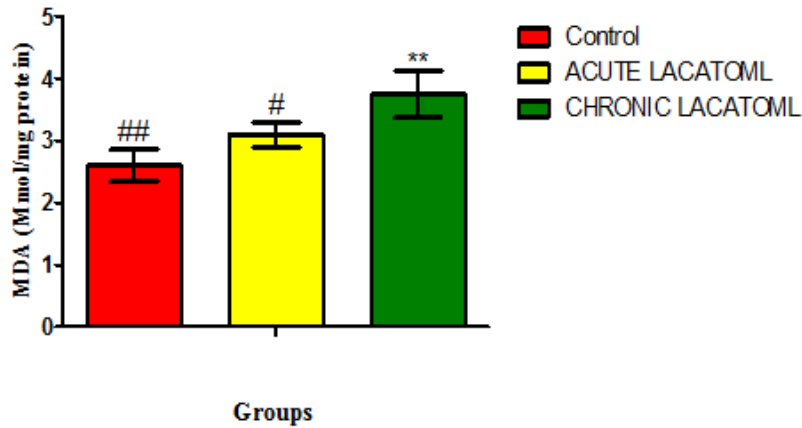


Fig. 1a. Effects of Lacasara-Tomtoto mixture on Liver Malondialdehyde Level in Rats. Mean values with different sign are significantly different at $P < 0.05$. Acute Lacasara-tomtoto Liver (ACUTE LACATOML and Chronic Lacasara-tomtoto liver (CHRONIC LACATOML)

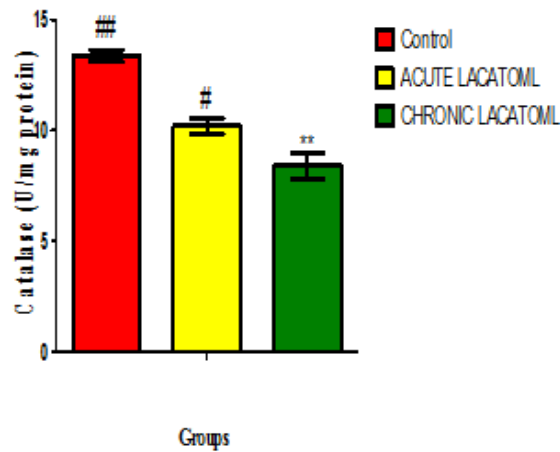


Fig.1b. Effects of Lacasara-Tomtoto mixture on Liver Catalase Activity in Rats. Mean values with different sign are significantly different at $P < 0.05$. Acute Lacasara-tomtoto Liver (ACUTE LACATOML and Chronic Lacasara-tomtoto liver (CHRONIC LACATOML)

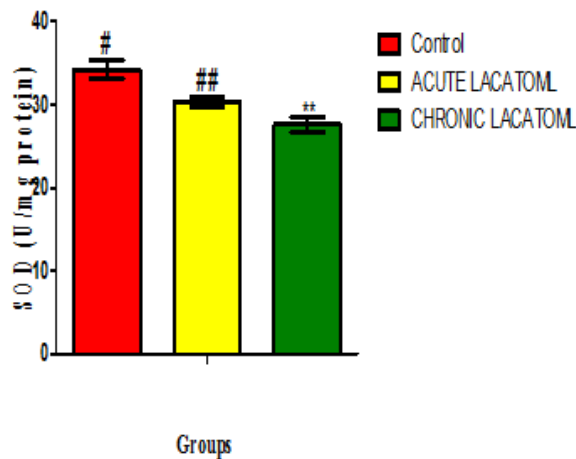


Fig. 1c. Effects of Lacasara-Tomtoto mixture on Liver Superoxidise dismutase Activity in Rats. Mean values with different sign are significantly different at $P < 0.05$. Acute Lacasara-tomtoto Liver (ACUTE LACATOML and Chronic Lacasara-tomtoto liver (CHRONIC LACATOML)

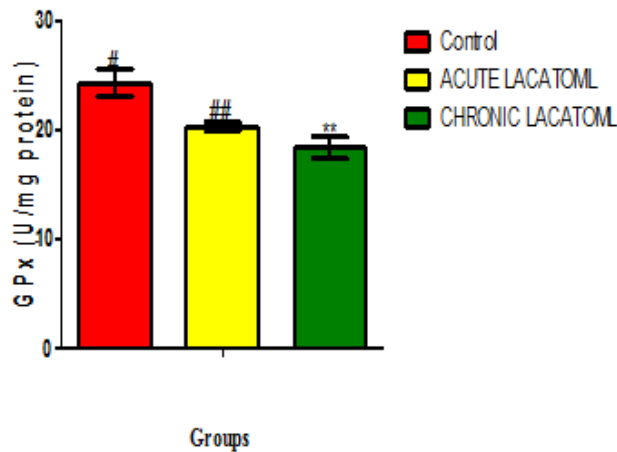


Fig. 1d. Effects of Lacasara-Tomtomb mixture on Liver Glutathione Peroxidase Activity in Rats. Mean values with different sign are significantly different at P<0.05. Acute Lacasara-tomtomb Liver (ACUTE LACATOML and Chronic Lacasara-tomtomb liver (CHRONIC LACATOML)

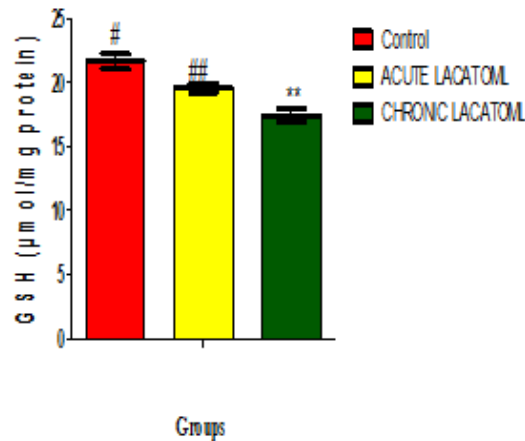


Fig. 1e. Effects of Lacasara-Tomtomb mixture on Liver Reduced Glutathione Level in Rats. Mean values with different sign are significantly different at P<0.05. Acute Lacasara-Tomtomb Liver (ACUTE LACATOML and Chronic Lacasara-Tomtomb liver (CHRONIC LACATOML)

Effects of lacasara-tomtomb mixture on oxidative stress markers in rat lung: Administration of Lacasara-Tomtomb mixture in *Norvegicus rattus* significantly ($p<0.05$) elevated the level of MDA and significantly ($p<0.05$) reduced the activities of catalase, SOD, GPx and level of GSH in rat lung in time dependent manner.

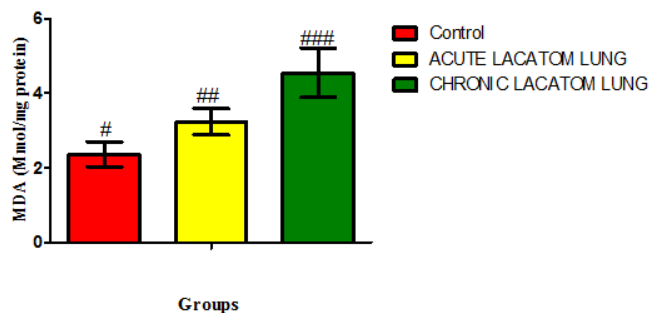


Fig. 2a. Effects of Lacasara-Tomtomb mixture on Lung MDA Level in Rats. Mean values with different sign are significantly different at P<0.05. Acute Lacasara-Tomtomb Lung (ACUTE LACATOM Lung and Chronic Lacasara-Tomtomb lung (CHRONIC LACATOM Lung)

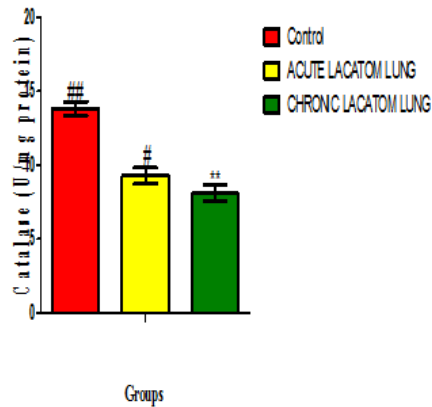


Fig. 2b. Effects of Lacasara-Tomtom mixture on Lung Catalase Activity in Rats. Mean values with different sign are significantly different at $P < 0.05$. Acute Lacasara-Tomtom Lung (ACUTE LACATOM Lung and Chronic Lacasara-Tomtom lung (CHRONIC LACATOM Lung)

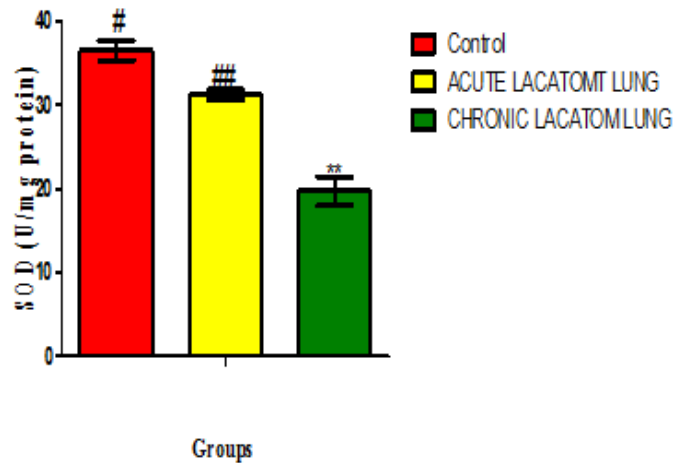


Fig. 2c. Effects of Lacasara-Tomtom mixture on Lung SOD Activity in Rats. Mean values with different sign are significantly different at $P < 0.05$. Acute Lacasara-Tomtom Lung (ACUTE LACATOM Lung and Chronic Lacasara-Tomtom lung (CHRONIC LACATOM Lung)

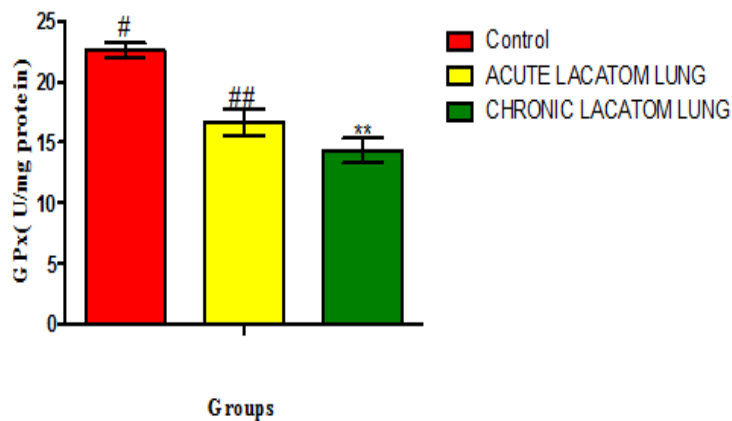


Fig. 2d. Effects of Lacasara-Tomtom mixture on lung GPx Activity in rats. Mean values with different sign are significantly different at $P < 0.05$. Acute Lacasara-Tomtom Lung (ACUTE LACATOM Lung and Chronic Lacasara-Tomtom lung (CHRONIC LACATOM Lung)

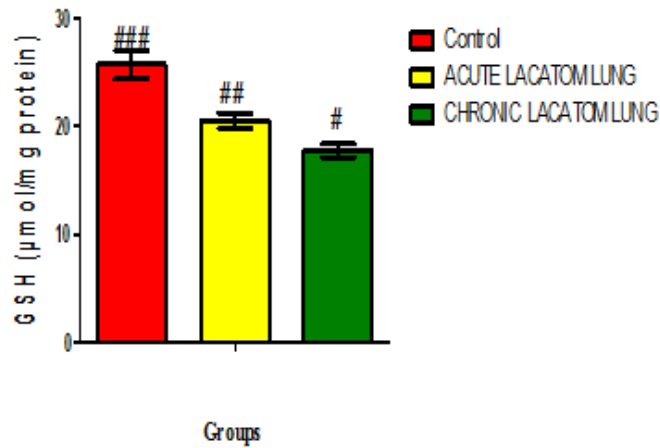


Fig. 2e. Effects of Lacasara-Tomtom mixture on lung GSH level in rats. Mean values with different sign are significantly different at P<0.05. Acute Lacasara-Tomtom Lung (ACUTE LACATOM Lung and Chronic Lacasara-Tomtom lung (CHRONIC LACATOM Lung)

Effects of lacasara-tomtom mixture on serum liver function indices in rat: Administration of Lacasara-Tomtom mixture in *norvegicus rattus* significantly ($p<0.05$) elevated the activities of ALP, AST, ALT, levels of total bilirubin and direct bilirubin. A significantly ($p<0.05$) reduction in the levels of albumin and total protein in time dependent manner was observed.

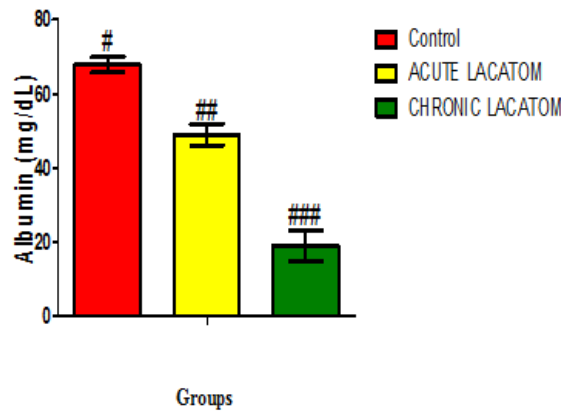


Fig. 3a. Effects of Lacasara-Tomtom mixture on albumin level in Rats. Mean values with different sign are significantly different at P<0.05. Acute Lacasara-Tomtom (ACUTE LACATOM) and Chronic Lacasara-Tomtom (CHRONIC LACATOM)

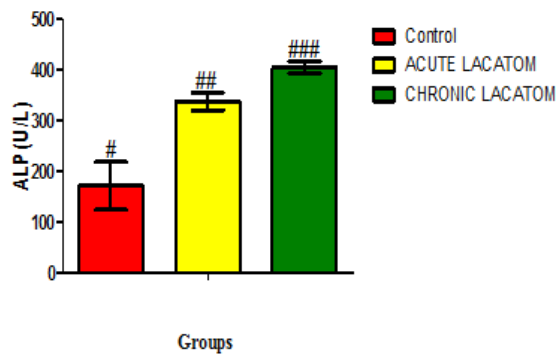


Fig. 3b. Effects of Lacasara-Tomtom mixture on ALP activity in Rats. Mean values with different sign are significantly different at P<0.05. Acute Lacasara-Tomtom (ACUTE LACATOM) and Chronic Lacasara-Tomtom (CHRONIC LACATOM)

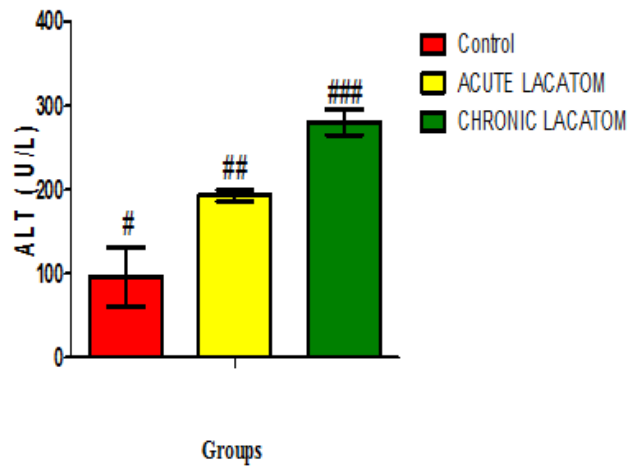


Fig. 3c. Effects of Lacasara-Tomtomb mixture on ALT activity in Rats. Mean values with different sign are significantly different at P<0.05. Acute Lacasara-Tomtomb (ACUTE LACATOM) and Chronic Lacasara-Tomtomb (CHRONIC LACATOM)

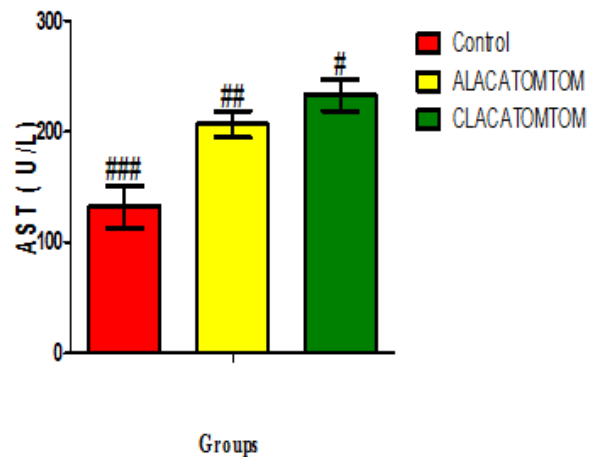


Fig. 3d. Effects of Lacasara-Tomtomb mixture on AST activity in Rats. Mean values with different sign are significantly different at P<0.05. Acute Lacasara-Tomtomb (ACUTE LACATOM) and Chronic Lacasara-Tomtomb (CHRONIC LACATOM)

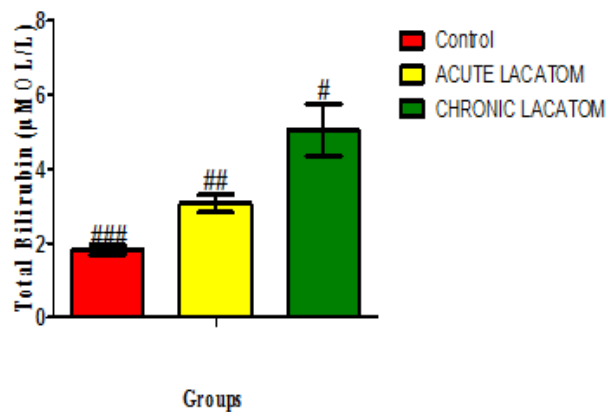


Fig. 3e. Effects of Lacasara-Tomtomb mixture on total bilirubin level in rats. Mean values with different sign are significantly different at P<0.05. Acute Lacasara-Tomtomb (ACUTE LACATOM) and Chronic Lacasara-Tomtomb (CHRONIC LACATOM)

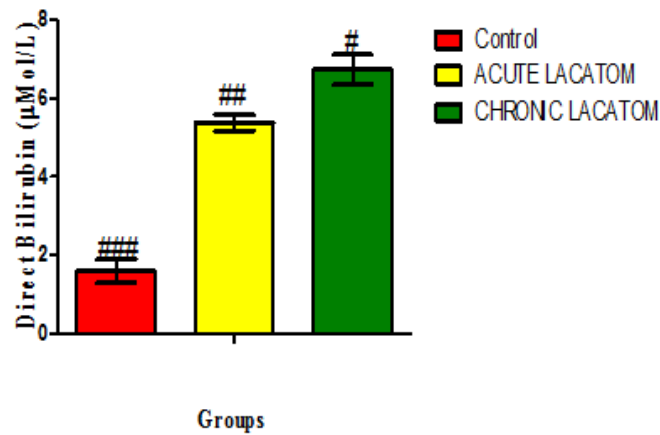


Fig. 3f. Effects of Lacasara-Tomtoto mixture on direct bilirubin level in rats. Mean values with different sign are significantly different at $P < 0.05$. Acute Lacasara-Tomtoto (ACUTE LACATOM) and Chronic Lacasara-Tomtoto (CHRONIC LACATOM)

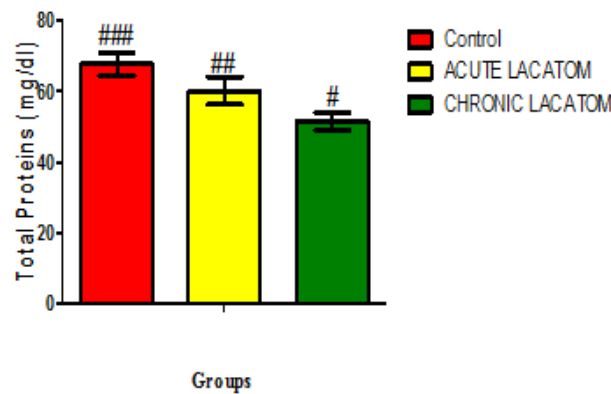


Fig. 3g. Effects of Lacasara-Tomtoto mixture on Total protein Level in Rats. Mean values with different sign are significantly different at $P < 0.05$. Acute Lacasara-Tomtoto (ACUTE LACATOM) and Chronic Lacasara-Tomtoto (CHRONIC LACATOM)

Effects of Lacasara-Tomtoto mixture on plasma kidney function indices in *Norvegicus rattus*: Administration of Lacasara-Tomtoto mixture in rats significantly ($p < 0.05$) elevated the levels of creatinine, urea, potassium, chloride and sodium levels in time dependent manner (Figs. 1-5).

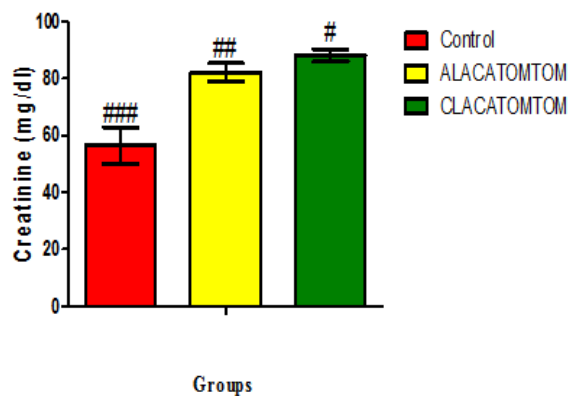


Fig. 4a. Effects of Lacasara-Tomtoto mixture on creatinie level in rats. Mean values with different sign are significantly different at $P < 0.05$. Acute Lacasara-Tomtoto (ACUTE LACATOM) and Chronic Lacasara-Tomtoto (CHRONIC LACATOM)

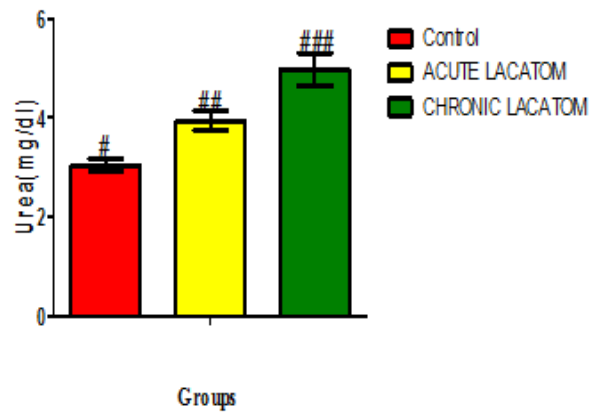


Fig. 4b. Effects of Lacasara-Tomtoto mixture on urea level in rats. Mean values with different sign are significantly different at $P < 0.05$. Acute Lacasara-Tomtoto (ACUTE LACATOM) and Chronic Lacasara-Tomtoto (CHRONIC LACATOM)

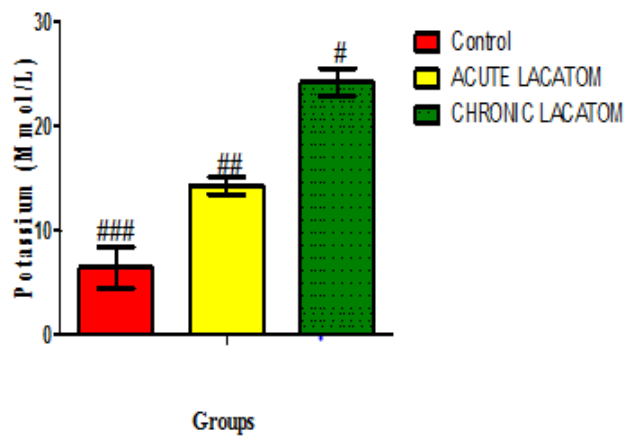


Fig. 4c. Effects of Lacasara-Tomtoto mixture on potassium level in rats. Mean values with different sign are significantly different at $P < 0.05$. Acute Lacasara-Tomtoto (ACUTE LACATOM) and Chronic Lacasara-Tomtoto (CHRONIC LACATOM)

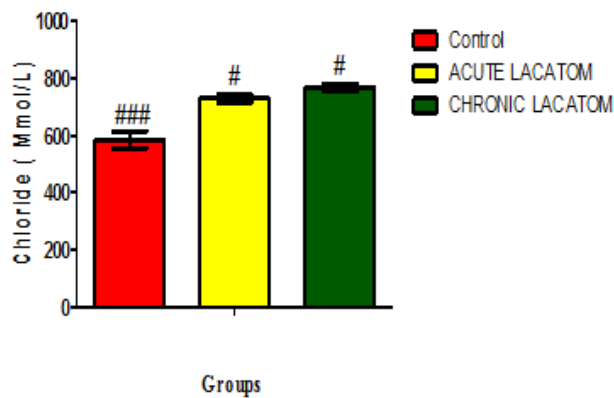


Fig. 4d. Effects of Lacasara-Tomtoto mixture on chloride level in rats. Mean values with different sign are significantly different at $P < 0.05$. Acute Lacasara-Tomtoto (ACUTE LACATOM) and Chronic Lacasara-Tomtoto (CHRONIC LACATOM)

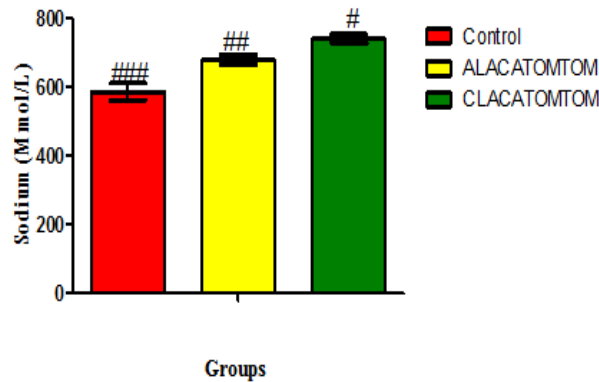


Fig. 4e. Effects of Lacasara-Tomtom mixture on sodium level in rats. Mean values with different sign are significantly different at $P < 0.05$. Acute Lacasara-Tomtom (ACUTE LACATOM) and Chronic Lacasara-Tomtom (CHRONIC LACATOM)

Effects of Lacasara-Tomtom mixture on body weight of *Norvegicus rattus*: Administration of Lacasara-Tomtom mixture in rats significantly ($p < 0.05$) reduced the body weight of the experimental rats.

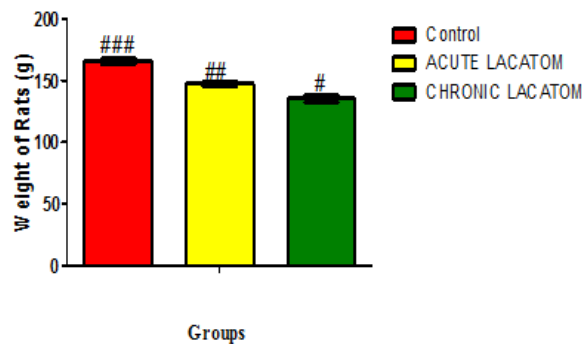


Fig. 5. Effects of Lacasara-Tomtom mixture on body weight of *Norvegicus rattus*

4. DISCUSSION

Plate 1 a Mag. X40 is a negative control liver section of *Norvegicus rattus* stained with H&E; The central vein (CE). Hepatocytes (black arrow) and the sinusoidal space SP (black arrow) are all well demonstrated and appeared normal. Plate 1b Mag. X40 is a liver section of same specie as in plate 1a on acute La casera tomtom mixture; section revealed ballooning (B) of hepatocyte as a manifestation of apoptosis (necrosis) and pink fibrin (IN) deposition occluding the sinusoidal space. Abusive substances and drugs are notable to cause liver diseases among which has been reported by Raj et al. [7]. The increase of serum AST and ALT observed also shown the level of hepatic necrosis seen. Plate 1c Mag. X40 is a liver section of *Norvegicus Rattus* on chronic oral administration of la casera tomtom mixture stained with H&E; walls of the portal triad shown hemorrhagic with dark stained deposition (A) and

fibrotic tissues shown a great level of cirrhosis (F) with infiltrating polymorphs. Plate 1d Mag. X40 is a liver section of *Norvegicus Rattus* on chronic La casera tomtom mixture stained with periodic acid Schiff. The section shown congested with vacuolated cells (V) (necrosis) and the central vein are filled with red cells deposition and infiltrating neutrophils (N). Plate 1e Mag. X40; negative control liver section of *Norvegicus Rattus* stained with H&E, the central vein CE, sinusoidal space (Thin black arrow) and hepatocytes (Thick black arrow) are all well demonstrated and appeared normal while Plate 1f Mag. X40 is a liver section of *Norvegicus Rattus* on oral chronic administration of la casera tomtom mixture; the section shown moderately cirrhosis or fibrosis (F) of tissues and heavy infiltrating neutrophils (N). These findings agreed with the findings obtained by Shaymaa, (2019) in which there was a significant increase in AST, ALT and ALP levels in the group of rats that were induced with oxidative

stress with lead acetate. The serial increase of the above liver enzymes that are known markers for hepatic damage is evidence that both acute and chronic administration of la casera tomtom mixture is toxic to the system and capable of causing systemic organ failure as seen during the administration a situation three experimental subjects died immediately at the point of given the mixture; the autopsied samples revealed systemic organ failure; total respiratory collapse seen in the lungs, severe liver cum kidney damage observed.

Consequently, there was also an increase in bilirubin levels both direct and total in both acute and chronic groups with the chronic group having higher levels this agreed with the findings of Stocker et al. [8] and Wu et al. [9]. This could in a bid to correct the oxidative stress imparted on the liver by the consumption of lacatomtom as Bilirubin has been recognized as a potent antioxidant. Bilirubin suppresses the oxidation of lipid in liposomes more than vitamin E, which is regarded as the best antioxidant of lipid peroxidation. Necrotic dark appearance of hemorrhagic vessels (A) and cellular vacuolations are seen and that agreed with the report of Wu et al. [9]. Plate 2b Mag. X40 is lung section of *Norvegicus Rattus* on acute administration of la casera tomtom mixture; the section shown a collapsed congested alveoli wall (C), honeycombed appearance of distorted pneumocytes with edematous background (o) unlike plate 4.2b which shown no pathological changes. Plate 2d Mag. X10 is a lung tissue section of *Norvegicus Rattus* on chronic administration of la casera tomtom mixture; the section shown a collapsed congested alveoli wall (C), honeycombed appearance of distorted pneumocytes with edematous background and fibrotic collagenous deposition (F) congesting the alveoli walls, seen also are inflammatory cells infiltrating the alveoli (IN). Plate 2e Mag. X40 is a lung section of *Norvegicus Rattus* on chronic oral administration of la casera tomtom mixture the section shown; collapse congested alveoli wall (C), honeycombed appearance of distorted pneumocytes with edematous background consistence with atypical respiratory distress. Plate 4a Mag. X40 is a negative control kidney section of a *Norvegicus Rattus* stained with H&E; section shown collecting ducts (black arrow) and podocytes and all appeared normal. Plate 4b is same specie as in plate 4.3a on acute oral administration of la casera tomtom mixture; section shown hyaline droplet in the glomerular

tuft (H) with inflammatory cells, clear capsular spaces were seen; Plate 4d is a kidney section of *Norvegicus Rattus* on chronic La casera tomtom mixture administration stained with periodic acid Schiff, section shown extensive glomerular hyalinization with moderate renal sclerosis (SC), the numerous present of red blood cells (black arrow) is evidence of inflammatory lesion. The evidence of systemic damage by the lacasera tomtom mixture cannot be taking for granted. The actually revealed same histologic pattern of the most damage caused by poisonous chemical agents and dangerous drugs; however, it should be noted that La casera is a well-known soft drink highly consumed by Nigerians though they have been a speculation and doubt concerning its safety following its ability to wash off stains better than some commercially sold detergent. No available reported evidence of lacasera allergy during this research same with tomtom candy sweet; basically, the two substance is known to be abusive when combined together, originally both substances are manufactured by different companies and were not made to be taken in combination; and this redefined abuse substance to be any two or more substances arbitrary combined and used without the permissions and safety grantee by the companies of the substances. It is worthy to note that when two or more substances produced by either same or different companies are combined a new product with entirely different biological effect will be produced.

Administration of Lacasara-Tomtom mixture in *Norvegicus rattus* significantly ($p<0.05$) elevated the level of MDA and significantly ($p<0.05$) reduced the activities of catalase, SOD, GPx and level of GSH in rat lung in time dependent manner. Administration of Lacasara-Tomtom mixture in *norvegicus rattus* significantly ($p<0.05$) elevated the activities of ALP, AST, ALT, levels of total bilirubin and direct bilirubin. A significantly ($p<0.05$) reduction in the levels of albumin and total protein in time dependent manner was observed. Administration of Lacasara-Tomtom mixture in rats significantly ($p<0.05$) elevated the levels of creatinine, urea, potassium, chloride and sodium levels in time dependent manner. Administration of Lacasara-Tomtom mixture (Lacatomtom) in rats significantly ($p<0.05$) reduced the body weight of the experimental rats. Increase MDA is a strong indication of free radical synthesis as revealed in both acute and chronic administration in time dependent manner.

5. CONCLUSION

The production of codeine-like substance and the subsequent consumption of such soft drinks mixed with tomtom candy 'Gigabyte' for the purpose to attain a euphoric feeling commonly called highness has led most youth to the mixture of tomtom candy in soft carbonated drink called lacasera to produce lacatomtom, the consumption of this drink has deleterious effects on both the liver, kidney and lung among others. This practiced was noticed more during the covid-19 lockdown in Nigeria, where movement were highly restricted. This study revealed that lacatomtom solution could lead to multi-systemic failure and sudden death as observed in two subjects used for this study whose autopsy examination revealed a total collapse of respiratory Centre upon initial administration of the solution. It is also worthy to note that high propensity to lacatomtom cocaine substitute is more among less engaged or unemployed youth and adults. It is a real challenge because the country has no law against anyone on excess or mixed consumption of soft drink and tomtom candy. Unfortunately, it is been observed to be consumed publicly without feeling of been prosecuted. The malnormal seen among the study subject relatively revealed the circumstances surrounding mysterious sudden death encounter by most persons already addicted to lacatomtom mixture.

CONSENT

It is not applicable.

ETHICAL APPROVAL

It is not applicable.

COMPETING INTERESTS

Authors have declared that no competing interests exist.

REFERENCES

1. Van Eygen I, Vannet BV, Wehrbein H. Influence of a soft drink with low pH on enamel surfaces: an in vitro study. *Am J Orthod Dentofac Orthop.* 2005;128(3):372-7.
2. Olley B. Is dried paw-paw leaf as a psychoactive substance? *Psychologia.* 2020;15(1):25-39.
3. Dumbili EW. Drug-related harms among young adults in Nigeria: implications for intervention. *J Hum Behav Soc.* 2020;30(8):1013-29.
4. Dumbili EW, Ezekwe E, Odeigah OW. From "codeine Diet" to "Gutter Water": polydrug use among Nigerian young adults. *Drugs Alcohol Today.* 2020;20(2):95-107.
5. Kazeem Y, Chutel L. The Wrong supply: Africa's desperate youth are getting high on opioids and anything they can get their hands on. *Adv Nutr.* 2018;7:48-50.
6. Okorie N. Basic histopathology instructional Manual for staff and students. Shibboleth prints Makudi Nigeria. ISBN: 978-978-978-6174; 2021.
7. Raj V, Ravi LN, Bell G, Lisa K. Oxidative stress in chronic liver disease: relationship between peripheral and hepatic measurements. *Am J Med.* 2011;342(4):314-7.
8. Stocker R, Yamamoto Y, McDonagh AF, Glazer AN, Ames BN. Bilirubin is an antioxidant of possible physiological importance. *Science.* 1987;235(4792): 1043-6.
9. Wu TW, Fung KP, Yang CC. Unconjugated bilirubin inhibits the oxidation of human low density lipoprotein better than Trolox. *Life Sci.* 1994;54(25):P477-81.

© 2022 Okorie et al.; This is an Open Access article distributed under the terms of the Creative Commons Attribution License (<http://creativecommons.org/licenses/by/4.0>), which permits unrestricted use, distribution, and reproduction in any medium, provided the original work is properly cited.

Peer-review history:
The peer review history for this paper can be accessed here:
<https://www.sdiarticle5.com/review-history/90436>