

Neonatal Rickets, Due to Maternal Vitamin D Deficiency, Complicated by Convulsion and Dilated Cardiomyopathy: Case Report

Nadia Mebrouk ^{a*}, Fatima Jabourik ^a, Bouchra Chkirat ^a, Loubna Chtouki ^a,
Thami Benouachane ^a, Hassan Ait Oamer ^a and Abdelali Bentahila ^a

^a Department of Pediatrics IV, Mohamed V University, Children's Hospital of Rabat, Morocco.

Authors' contributions

This work was carried out in collaboration among all authors. Authors NM and AB designed the study, performed the statistical analysis, wrote the protocol and wrote the first draft of the manuscript. Authors NM and AB managed the analyses of the study. Author NM managed the literature searches. All authors read and approved the final manuscript.

Article Information

DOI: 10.9734/AJPR/2022/v9i230260

Open Peer Review History:

This journal follows the Advanced Open Peer Review policy. Identity of the Reviewers, Editor(s) and additional Reviewers, peer review comments, different versions of the manuscript, comments of the editors, etc are available here: <https://www.sdiarticle5.com/review-history/89348>

Case Study

Received 08 May 2022
Accepted 13 July 2022
Published 19 July 2022

ABSTRACT

Deficiency rickets due to maternal hypovitaminosis D cause hypocalcaemia in infants, which may be complicated by dilated cardiomyopathy (DCM) with myocardial dysfunction. Calcium is central in myocardial contraction coupling, and hypocalcemia decreases myocardial contractility. However, dilated cardiomyopathy (DCM) due to hypocalcemia in infants has been rarely reported. Correction of hypocalcemia was associated with resolution of congestive heart failure and the left ventricular (LV) geometry and systolic function.

We report the case of an infant who presented deficiency rickets due to maternal hypovitaminosis D, complicated by convulsion and dilated cardiomyopathy, with good improvement under treatment with calcium and vitamin D.

Keywords: Rickets; hypovitaminosis D; hypocalcemia; dilated cardiomyopathy; DCM.

1. INTRODUCTION

Rickets is a potentially serious or even fatal systemic disease, with, particularly in severe

forms, neurological (convulsions, coma) and cardiac (dilated cardiomyopathy and myopathy) damage [1]. Lack of vitamin D greatly reduces the absorption of calcium and phosphorus at the

*Corresponding author: Email: nadia.mebrouk@hotmail.com;

digestive level. The causes of severe and early forms of rickets are multifactorial, often stemming from maternal factors, from calcium and/or vitamin D deficiency. The development and mineralization of the fetal skeleton require large and constant supplies of calcium and phosphorus during the 3rd trimester of pregnancy. Vitamin D has no direct role in placental calcium transport, but is necessary to maintain maternal calcium stores. At birth, an infant's 25(OH)D level is proportional to that of its mother [1]. In the absence of adequate vitamin D supplementation, a neonate born to a deficient mother has a lowered 25(OH)D value. It is vulnerable to an insufficient intake of calcium favored, in particular, by exclusive breastfeeding. Deficiency rickets due to maternal hypovitaminosis D causes hypocalcemia in infants, which may be complicated by dilated cardiomyopathy (DCM) with reversible myocardial dysfunction after oral treatment with oral treatment calcium and vitamin D [3,4]. We report the case of an infant who presented deficiency rickets due to maternal hypovitaminosis D, complicated by convulsion and dilated cardiomyopathy, with good improvement under treatment with calcium and vitamin D.

2. CASE REPORT

The patient is a 4-month-old infant from consanguineous parents, the third of three siblings. He was born vaginally, with good adaptation to extrauterine life, birth weight of 3300 g, exclusively breastfed, good psychomotor development, and current vaccination according to the national immunization program. Since birth, the patient presented fatigue during feedings with the notion of gaze fixity complicated by respiratory discomfort with convulsion. On admission to our department, the

clinical examination found a conscious, toned and reactive infant; his weight was 6 kg, head circumference was 42 cm. Height 54 cm, temperature 37°C, and normal blood sugar. The patient is in respiratory distress with signs of heart failure. During the clinical examination, the patient had a convulsive seizure and was put in condition with an intra-rectal valium injection. After the convulsion, we assessed: the brain imaging was normal; the chest X-ray showed cardiomegaly (Fig. 1) with bone demineralization. Echocardiography revealed a dilated cardiomyopathy with an ejection fraction of 30% (Fig. 2), and an electrocardiogram showed repolarization disorders in V4 and V6. The complete blood count was normal. The infection profile is normal.

The dosage of electrolytes revealed hypocalcemia at $Ca^{+}=46mg/l$ with a corrected Calcium=62 mg/l and normal phosphorus at 62 mg/l. Before this clinical and paraclinical picture. We thought of rickets by a deficit in Vit D, the corrected calciuria decreased, and the 25 OH Vit D decreased by seven ng/ml, parathormone increased by 120 pg. Increased alkaline phosphatase of 821 U/l. The wrist x-ray showed bony signs of rickets (Fig. 3). The vitamin D dosage in the mother is less than eight ng/ml. The diagnosis of deficiency rickets secondary to maternal vitamin D hypovitaminosis was retained. The patient was treated with calcitherapy in combination with the treatment of heart failure. Once the serum calcium normalized, the patient was put on vitamin D3. The evolution was favourable, and marked by the improvement of the size of the heart chambers, the normalization of the left ventricular ejection fraction (Fig. 4), and the improvement of the radiological signs (Fig. 5). The control PAL dosage showed 256 ui/l.

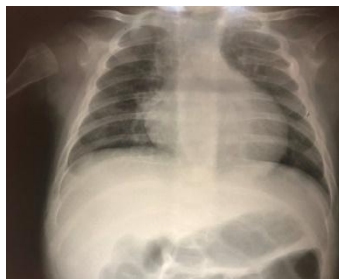

Fig. 1. Chest X-ray

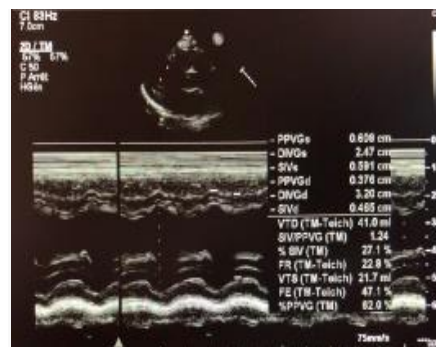


Fig. 2. Echocardiography before treatment

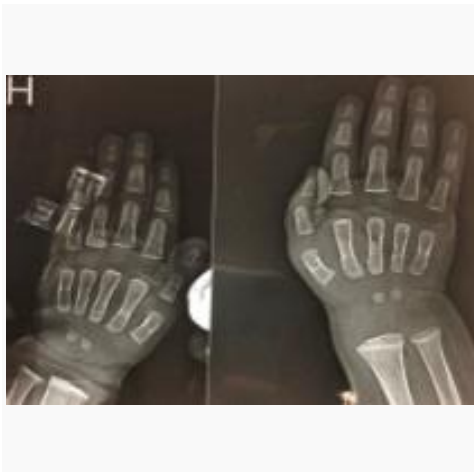

Fig. 3. Radiography before treatment

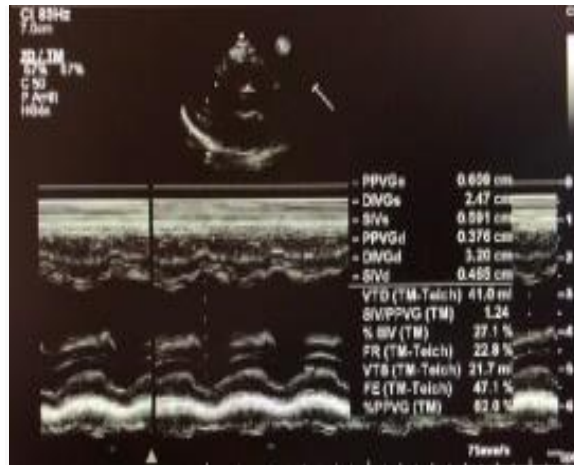


Fig. 4. Echocardiography after treatment

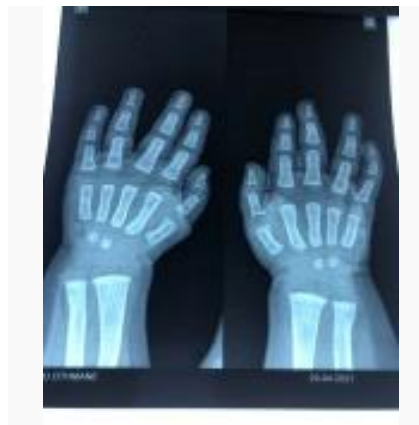

Fig. 5. Radiography after treatment

3. DISCUSSION

Chez les nouveau-nés et les jeunes enfants, la grave carence en vitD peut nuire à la minéralisation des tissus osseux (ostéomalacie) et à la formation des plaques de croissance (rachitisme); elle peut aussi être responsable de convulsions, de myocardopathie et de manifestations plus discrètes. [2] “Maternal vitamin D deficiency during pregnancy can cause infantile rickets. Prevention involves providing vitamin D during pregnancy and breastfeeding. Vitamin D has been experiencing a spectacular resurgence of interest for some time due to its “classic” bone effects but also extra-osseous” [5, 6]. “80–90% of vitamin D comes from skin biosynthesis under the effect of ultraviolet radiation. Only 10–20% of vitamin D comes from an exogenous source via the absorption of vitamin D-rich foods. Exogenous intake depends on the type of diet but also on regional habits” [7]. “Until recently, the minimum satisfactory

concentration of vitamin D was defined as that which would prevent the onset of deficiency rickets in children and osteomalacia in adults, i.e., approximately 8 ng/ml (20 nmol/l)” [8]. “In 2010, most international experts agreed to set the limit values for adults. A level between 20 and 30 ng/ml (50 and 75 nmol/ml) is considered an “insufficiency”; a level between 10 and 20 ng/ml (25 and 50 nmol/l) a “deficiency”; and less than or equal to 10 ng/ml (≤ 25 nmol/ml) in vitamin D as the “deficiency” threshold below which the risk of short-term bone pathological consequences is significant. For children, there is no consensus, and it is considered that a minimum serum concentration of 20 ng/ml is necessary” [9]. “In the newborn, the vitamin status depends entirely on the mother’s. Maternal vitamin D stores can sustain infant requirements for the first 6 weeks of life only if maternal vitamin D status is sufficient at the end of pregnancy, which is often not the case. A vitamin D deficiency has been well demonstrated

in pregnant women at the end of their pregnancy. Studies have shown a relationship between this poor vitamin D status and the frequency of late or even early neonatal hypocalcemia accidents” [10, 11]. In a 2001 study, Bassir et al. found “in a population of Iranian pregnant women very low or zero circulating levels of plasma 25(OH)D in 80% of the population studied (57 women). Newborns had low or undetectable levels with biological signs of osteomalacia (raised circulating PTH and alkaline phosphatase), as is the case of our patient. Moreover, the neonatal adaptation of calcium metabolism is disturbed with severe and lasting neonatal hypocalcemia” [12].

“Hypocalcemia caused by vitamin D deficiency leads to extra-osseous complications, particularly dilated cardiomyopathy and congestive heart failure. Calcium directly affects the myocardium's force of contraction by excitation-contraction coupling. Hypocalcemia reduces myocardial contractility, but the incidence of congestive heart failure and cardiomyopathy due to hypocalcemia is very rare” [13]. “Hypocalcemic cardiomyopathy is generally refractory to conventional treatments for heart failure but responds favorably to restoration of normocalcemia. Our patient's case had severe hypocalcemia due to vitamin D deficiency and responded dramatically to calcium and vitamin D correction. Maiya, et al. reported 16 cases of cardiomyopathy due to hypocalcemia in children associated with vitamin D deficiency” [14]. Another study found “four exclusively breastfed African American infants with congestive heart failure and dilated cardiomyopathy due to hypocalcemia, whose heart function returned to normal within months of treatment with vitamin D and calcium” [15]. An Indian study found “hypocalcemia in 16% of infants with severe left ventricular dysfunction; vitamin D deficiency was identified as the main cause of hypocalcemia. These children improved after vitamin D and calcium supplementation” [16].

“Vitamin D deficiency in developing countries is primarily nutritional, particularly in exclusively breastfed infants whose mothers have low vitamin D stores” [17].

Due to the link between maternal and infant Vit D levels, prevention of maternal vit D deficiency is an important strategy to reduce symptomatic vit D deficiency in the infant, including congenital rickets in neonates. In pregnant women, the

recommended dietary intake of vitamin D is 600 IU/day.

4. CONCLUSION

Maternal CvitD can cause congenital rickets, defined as a disease that manifests within the first 30 days of life [2]. Neonatal and maternal hypovitaminosis D should be considered in the event of neonatal hypocalcemia. Systematic supplementation should be implemented in the third trimester of pregnancy to maintain adequate maternal vitamin and optimal fetal status.

CONSENT

As per international standard, parental written consent has been collected and preserved by the author(s).

ETHICAL APPROVAL

As per international standard or university standard written ethical approval has been collected and preserved by the author(s).

COMPETING INTERESTS

Authors have declared that no competing interests exist.

REFERENCES

1. Edouard T, Linglart A, Salles JP. Vitamine D et rachitisme: débats, consensus et utilisation pratique. *Perfectionnement en Pédiatrie*. 2018 ;1.1: 40-47.
2. Irvine, James, Leanne M. Ward. "La prévention de la carence en vitamine D symptomatique et du rachitisme chez les nourrissons et les enfants autochtones du Canada." *Paediatrics & Child Health*. 2022; 27.2:128-128.
3. Levine SN, Rheams CN. Hypocalcemic heart failure. *Am J Med*. 1985; 78:1033–5. [PubMed] [Google Scholar]
4. Gurtoo A, Goswami R, Singh B, Rehan S, Meena HS. ypocalcemia-induced reversible hemodynamic dysfunction. *Int J Cardiol*. 1994;43:91-3.
5. Audran M, Briot K. Analyse critique du déficit en vitamine D. *Revue du Rhumatisme*. 2010;77:139–143.
6. Bacchetta J, Ranchin B, Dubourg L, Cochat Pl. Vitamine D : un acteur majeur en santé ? *Arch Pédiatr*. 2010;17:1687-1695.

7. Amstutz V, Cornuz J, Krieg M-A, Favrat B. Vitamine D : actualité et recommandations. *Revue Médicale Suisse* .
8. St Arnaud R, Demay MB. Vitamin D biology. In: Glorieux FH, editor. *Pediatric bone, biology and diseases*. London: Elsevier Science. 2003 :193–215.
9. Adams JS, Hewison M. Update in vitamin D. *J Clin Endocrinol Metab*. 2010;95: 471–8.
10. Oki J, Takedatsu M, Itoh J et al. Hypocalcémie focal seizures in a one-month-old infant of a mother with a low circulating level of vitamin D. *Brain & Dee*. 199h13:132- 4
11. Oki J, Takedatsu M, Itoh J et al. Hypocalcémie focal seizures in a one-month-old infant of a mother with a low circulating level of vitamin D. *Brain & Dee*. 199h13:132- 4
12. Bassir M, Laborie S, Lapillonne A et al. Vitamin D deficiency in Iranian mothers and their neonates: A pilot study. *Acta Paediatr* 2001; 90: 567- 570
13. Available :<https://doi.org/10.1016/j.revmed.2015.03.205>
14. Benzarouel D, Hasni K, Ashab H, El Hattou M. Une cause réversible de la cardiomyopathie dilatée : l'hypocalcémie. *Ann Cardiol Angeiol*. 2014;63:102–6.
15. Douban S, Brodsky MA, Whang DD, Whang R. Significance of magnesium in congestive heart failure. *Am Heart J*. 1996;132:664–71.
16. TOMAR, Munesh, RADHAKRISHNAN, Sitaraman, et SHRIVASTAVA, Savitri. Myocardial dysfunction due to hypocalcemia. *Indian Pediatrics*. 2010; 47(9):781-783.
17. Dawodu A, and CL, Wagner. Prevention of vitamin D deficiency in mothers and infants worldwide—a paradigm shift. *Paediatrics and International Child Health*. 2012;32.1: 3-13.

© 2022 Mebrouk et al.; This is an Open Access article distributed under the terms of the Creative Commons Attribution License (<http://creativecommons.org/licenses/by/4.0>), which permits unrestricted use, distribution, and reproduction in any medium, provided the original work is properly cited.

Peer-review history:
The peer review history for this paper can be accessed here:
<https://www.sdiarticle5.com/review-history/89348>