

Type 2 Autoimmune Hepatitis Triggered by Hepatitis A Virus: A Case Report

Ghita Hachim ^{a*}, Abdelhakim Ourrai ^a, Abdelilah Radi ^a, Najat Lamalmi ^a,
Rachid Abilkassem ^a, Rihane El Mohtarim ^a, Amal Hassani ^a
and Aomar Agadr ^a

^a Department of Pediatrics, Mohammed V Military Instruction Hospital, Rabat, Morocco.

Authors' contributions

This work was carried out in collaboration among all authors. All authors read and approved the final manuscript.

Article Information

DOI: 10.9734/AJPR/2022/v9i230264

Open Peer Review History:

This journal follows the Advanced Open Peer Review policy. Identity of the Reviewers, Editor(s) and additional Reviewers, peer review comments, different versions of the manuscript, comments of the editors, etc are available here: <https://www.sdiarticle5.com/review-history/90102>

Case Report

Received 27 May 2022
Accepted 04 August 2022
Published 06 August 2022

ABSTRACT

Autoimmune Hepatitis (AIH) pathogenesis is still unknown. However, among patients who have a genetic susceptibility, some viral infections appear to be triggers for AIH. We report a case of a child who developed type 2 autoimmune hepatitis as a result of HEPATITIS A Virus (HAV) infection. An 8-year-old female who was diagnosed with hepatitis A three years ago and was cured after three months. She developed jaundice and epistaxis a few years later. Complementary tests revealed polyclonal hypergammaglobulinemia, antinuclear and anti-LC1 antibodies, and hepatocyte necrotico-inflammatory lesions in a liver biopsy. The diagnosis of type 2 autoimmune hepatitis was kept. A remission was obtained under corticosteroid and azathioprine treatment. In cases of persistent HAV infection, AIH should be investigated so that therapy can start earlier. To prevent more serious complications, AIH patients should also receive the Hepatitis B Virus (HBV) and HAV vaccines.

Keywords: Autoimmune hepatitis; hepatitis A; antibodies.

1. INTRODUCTION

AIH is a chronic inflammatory liver disease defined by positive circulating auto antibodies

and inflammatory liver histology, which includes lymphocytic, infiltrates and interface hepatitis. Females with a genetic susceptibility are more likely to be affected [1].

*Corresponding author: Email: ghita717@gmail.com;

The cause of AIH is uncertain. Numerous viruses, especially hepatitis viruses, could be responsible for inducing AIH in a genetically predisposed person [2].

In this study, we describe a case of a child with type 2 AIH caused by hepatitis A that has never been reported in Morocco.

2. CASE PRESENTATION

An 8-year-old female patient has a history of hepatitis A virus infection at the age of 5 years old, which healed spontaneously after 3 months. Three years later, she showed up with hypogastric pains, jaundice, and bilateral epistaxis. After being treated for three days at a nearby hospital where she received vitamin K injections, the child was transferred to the pediatric unit of the military hospital in Rabat for further investigations and treatments. Her physical examination revealed jaundice without hepatomegaly. Her laboratory results were as follows:

Hemoglobin of 9.7 g/dL, MCV of 80.3 fL, MCHC of 33.4 g/dl, MCH of 26.8 pg, platelets of 241000/mm³, WBC of 8800/mm³. Total bilirubin was 64 mg/L, with aspartate aminotransferase (AST) of 614 U/L, alanine aminotransferase (ALT) of 515 U/L, alkaline phosphatase (ALP) of 488 U/L, gamma-glutamyl transferase (γGT) of 160 U/L. The prothrombin time (PT) was low at 56%, as was albumin at 29 g/l and Factor V at 48%. The capillary blood glucose was 0.81g/l.

The results of blood tests related to hepatitis viral infection were negative.

Protein electrophoresis showed a polyclonal hypergammaglobulinemia at 35 g/l.

In addition to a positive Coombs test, Anti-Nuclear Antibody (ANA) and anti-liver cytosol antibody (anti LC1) were both positive at 1/320 and 78 UA, respectively. She tested negative for anti-liver kidney microsomal antibody (LKM), Anti-Smooth Muscle Antibody (SMA), and Anti-Mitochondrial Antibody (AMA).

An abdominal ultrasound and scanner, as well as magnetic resonance cholangiopancreatography, were normal.

A liver biopsy was performed and showed: Cholangitis lesions with lymphoplasmacytic infiltration in the portal tract (Fig. 1), moderate interface hepatitis (Fig. 2), and mild to moderate lobular necrosis (Figs. 3 and 4) with moderate portal fibrosis. All of these signs indicate an autoimmune hepatitis.

According to the International Autoimmune Hepatitis Group's scoring system (IAIHG), the patient had a score of 17. As a result, the diagnosis of autoimmune hepatitis was retained.

She was given prednisolone (2 mg/kg/day) and azathioprine (1.5 mg/kg/day). At the end of the first month of treatment, the results of liver aminotransferase and prothrombine time were normal: ALT of 38 U/L, AST of 58 UI/L, and TP of 78%. She has been followed up in remission for 6 months without a relapse, and we started to decrease the dose of prednisone to 1,5 mg/kg/day.

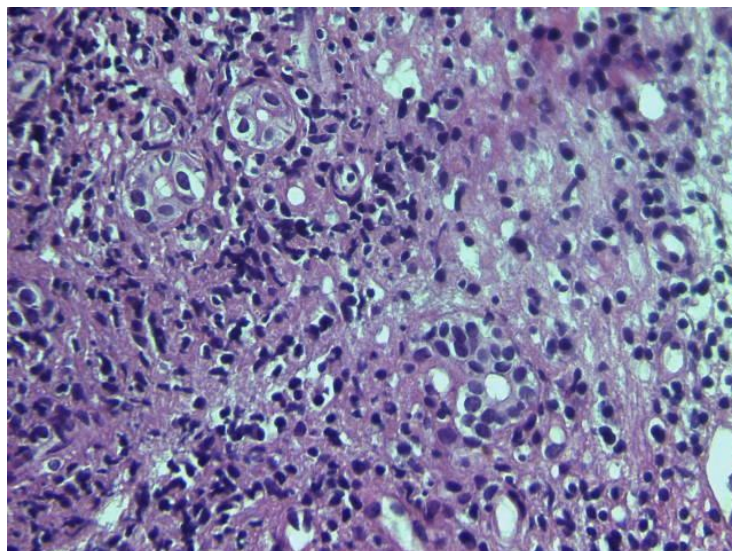


Fig. 1. Cholangitis lesions with lymphocytic infiltration in the portal tract

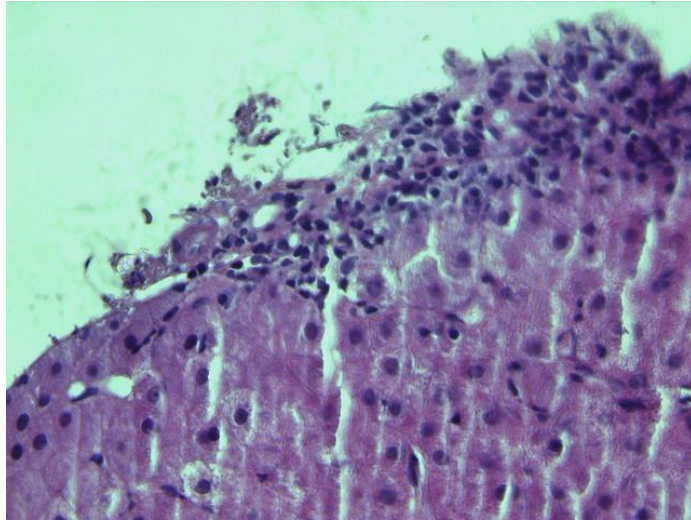


Fig. 2. Moderate interface hepatitis with necrosis lesions

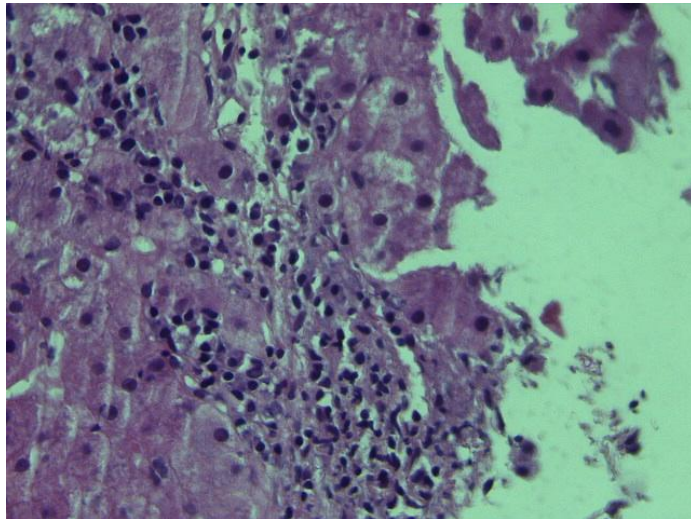


Fig. 3. Intralobular necrotic foci (x 40)

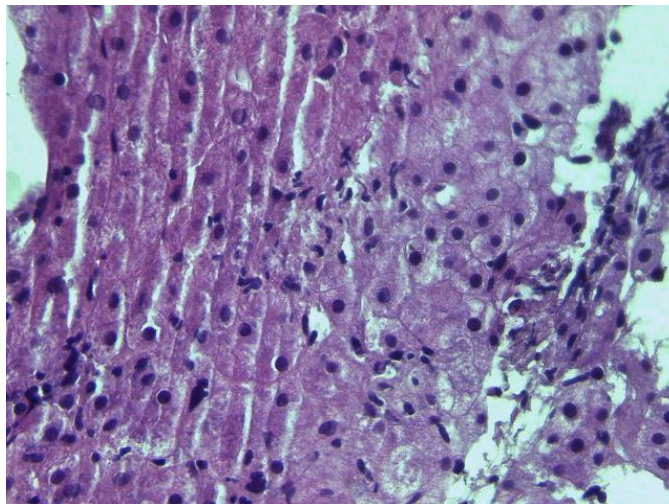


Fig. 4. Intralobular microgranulomas with hepatocellular necrosis (x 40)

3. DISCUSSION

AIH is a chronic inflammatory disease of the liver caused by an immune response that is characterized by hepatic cytolysis, hypergammaglobulinemia, serum autoantibodies, and a compatible histological lesion. It is a rare disease that affects 0.25 out of every 100,000 children. It is more common in women, with a male-to-female ratio of 1:7 [3,4].

In our case, AIH was retained on a score of 17 based on the IAIHG criteria. The International HAI Group established this diagnostic score in 1993, with a revision in 1999, allowing the diagnosis of AIH to be classified from probable to certain [5].

AIH is classified into two types: Type 1 and type 2. Adults and teenagers frequently have type 1, while children frequently have type 2. This categorization is based on circulating antibody seropositivity: Antinuclear and/or smooth muscle antibodies (SMA) in type 1 AIH, LKM1 and/or hepatic cytosol (LC1) in type 2 [6].

Anti-nuclear antibodies are most often found in AIH type 1 but are non-specific; we also find them in lupus, sclerosing cholangitis, and juvenile idiopathic arthritis. However, in the presence of anti-LC1 antibodies, which are more specific even if LKM1 antibodies are lacking, we can say that our patient has AIH type 2 [7].

Hepatitis A Virus (HAV) is classified as a hepatovirus in the Picornaviridae family. It is feco-orally transmitted between people who are in close proximity to one another.

Hepatitis A is an acute liver infection that is usually asymptomatic in children and worsens with age. Although the infection heals completely in the majority of patients, a minority may experience a protracted or relapsing course, or even a fulminant type. Sanitation measures are crucial in order to avoid HAV infections. This includes, but is not limited to, paying close attention to hygiene, especially in the food service sector [8,9].

It has been reported that hepatitis A, B, C, D, and E viruses, cytomegalovirus, Epstein–Barr virus, measles virus, varicella-zoster virus, and human immunodeficiency viruses may cause AIH. In particular, the hepatitis A virus and Epstein–Barr virus are known to be closely related to AIH type 1. Viral infection may alter or release cell

antigens and may be the initial stage of an autoimmune process. HAV could induce the appearance of anti-LKM1 antibodies by modification or release of proteins, or by molecular mimicry between HAV proteins and cytochrome P450 proteins.

This phenomenon of cross-recognition between autoantigens and viral proteins would explain why a viral infection can trigger an AIH in people who have a genetic susceptibility to it [10,11].

One of the risk factors for the disease is the presence of specific HLA class II antigens on the surface of hepatocytes. However, other predisposing factors are involved, in particular the sex and age of the patients. Type 1 HAI is associated with HLA A1, B8, DR3 and DR4 haplotypes, and HLA haplotype DR3 (DRB1*0301 allele), which is found in 70% of patients and represents a main risk factor for type 1 HAI. For type 2 HAI, a susceptibility allele was located at the DQB1 locus (DRB1*07 allele) which is associated with the presence of anti-LKM1 antibody [12,13].

As our case illustrates, hepatitis A virus infection seems to trigger HAI type 2 in a genetically predisposed child. However, HLA typing on this patient could not be performed due to a lack of financial means.

The HAV vaccine is strongly advised for individuals with chronic liver disease in order to avoid decompensation caused by HAV superinfection. In addition to that, in HCV-infected patients with well-compensated liver disease, combined vaccination against hepatitis A/B is both safe and highly immunogenic against HAV and HBV. Patients with AIH are also at a higher risk of illness aggravation or relapsing hepatitis A or B. Thus, it is important to vaccinate this population in order to protect them from both HAV and HBV [14].

4. CONCLUSION

Our patient appears to be an example in which hepatitis due to HAV might lead to AIH. Hence, we suggest that in cases of persistent liver disease following HAV contamination, AIH should be sought systematically in order to start treatment early. From another perspective, patients with AIH should also be vaccinated against both hepatitis viruses, HBV and HAV, to prevent serious progression.

ETHICAL APPROVAL

As per international standard or university standard written ethical approval has been collected and preserved by the author(s).

CONSENT

As per international standard or university standard, Parentals' written consent has been collected and preserved by the author(s).

COMPETING INTERESTS

Authors have declared that no competing interests exist.

REFERENCES

1. Lohse AW, Mieli-Vergani G. Autoimmune hepatitis. *J Hepatol.* 2011;55(1):171-82.
2. Vento S, Cainelli F. Is there a role for viruses in triggering autoimmune hepatitis? *Autoimmun Rev.* 2004;3(1):61-9.
3. Ducazu O, Degroote H, Geerts A, Hoorens A, Schouten J, Van Vlierberghe H, et al. Diagnostic and prognostic scoring systems for autoimmune hepatitis: a review. *Acta Gastroenterol Belg.* 2021; 84(3):487-95.
4. Jiménez-Rivera C, Ling SC, Ahmed N, Yap J, Aglipay M, Barrowman N, et al. Incidence and characteristics of autoimmune hepatitis. *Pediatrics.* 2015; 136(5):e1237-48.
5. Alvarez F, Berg PA, Bianchi FB, Bianchi L, Burroughs AK, Cancado EL, et al. International Autoimmune Hepatitis Group Report: review of criteria for diagnosis of autoimmune hepatitis. *J Hepatol.* 1999; 31(5):929-38.
6. Krawitt EL. Autoimmune hepatitis. *N Engl J Med.* 2006;354(1):54-66.
7. Mieli-Vergani G, Vergani D, Baumann U, Czubkowski P, Debray D, Dezsofi A et al. Diagnosis and management of pediatric autoimmune liver disease: ESPGHAN hepatology committee position statement. *J Pediatr Gastroenterol Nutr.* 2018;66(2): 345-60.
8. Feinstone SM. History of the discovery of hepatitis A virus. *Cold Spring Harb Perspect Med.* May 1. 2019;9(5):a031740.
9. Randazzo W, Sánchez G. Hepatitis A infections from food. *J Appl Microbiol.* 2020;129(5):1120-32.
10. Mack CL, Adams D, Assis DN, Kerkar N, Manns MP, et al. Diagnosis and management of autoimmune hepatitis in adults and children. Practice guidance and guidelines from the American Association for the Study of Liver Diseases; 2019.
11. Pintó RM, Pérez-Rodríguez F-J, Costafreda M-I, Chavarria-Miró G, Guix S, Ribes E, et al. Pathogenicity and virulence of hepatitis A virus. *Virulence.* 2021; 12(1):1174-85.
12. Béland K, Lapierre P, Alvarez F. Influence of genes, sex, age and environment on the onset of autoimmune hepatitis. *World J Gastroenterol.* 2009;15(9):1025-34.
13. Manns MP, Krüger M. Immunogenetics of chronic liver diseases. *Gastroenterology.* 1994;106(6):1676-97.
14. Abutaleb A, Kottilil S. Hepatitis A: epidemiology, natural history, unusual clinical manifestations, and prevention. *Gastroenterol Clin North Am.* 2020;49(2): 191-9.

© 2022 Hachim et al.; This is an Open Access article distributed under the terms of the Creative Commons Attribution License (<http://creativecommons.org/licenses/by/4.0>), which permits unrestricted use, distribution, and reproduction in any medium, provided the original work is properly cited.

Peer-review history:

The peer review history for this paper can be accessed here:
<https://www.sdiarticle5.com/review-history/90102>