



Normal Values of Optic Nerve Sheath Diameter on Computed Tomography and effect of Raised Intracranial Pressure on Head Injury Patients in North Central Nigeria

Ukamaka Dorothy Itanyi^{1*}, Adebukola Morenike Leslie¹,
and James Nwabueze Chukwuego¹

¹Department of Radiology, University of Abuja Teaching Hospital, Gwagwalada Abuja, Nigeria.

Authors' contributions

This work was carried out in collaboration among all authors. Author UDI designed the study and wrote the protocol and first draft of the manuscript. Authors AML and JNC collected and analyzed data, did the literature search. All authors read and approved the final manuscript.

Article Information

DOI: 10.9734/JAMMR/2021/v33i1430966

Editor(s):

(1) Dr. Barbara Giambene, Al Emadi Hospital, Qatar.

Reviewers:

(1) Ravi Teja Athukuri, Kaloji Narayana Rao University, India.

(2) Atanas Hilendarov, MU-Plovdiv, Bulgaria.

Complete Peer review History: <http://www.sdiarticle4.com/review-history/68446>

Original Research Article

Received 01 April 2021

Accepted 07 June 2021

Published 18 June 2021

ABSTRACT

Aim: To establish a local nomogram of Computed Tomographic measurement of Optic Nerve Sheath Diameter and determine the values that can objectively predict raised intracranial pressure.

Study design: observational retrospective study

Place and duration of study: Department of Radiology of University of Abuja teaching hospital, Abuja from March 2016 to February 2020.

Methodology: We included images of 356 patients referred to the Radiology department for brain CT. Data was grouped into three: (A) 200 non head injury patients as control, (B) head injury patients without radioclinical signs of raised ICP, (C) head injury patients with at least one radiologic sign of raised ICP. ONSD obtained in axial scans at 3mm retrobulbar region at constant window width and level of 250/50 were analysed using SAS software version 9.3 and statistical level of significance set at 0.05.

Result: Mean ONSD of 200 normal patients was 4.4mm± 0.5 with no significant correlation with

*Corresponding author: E-mail: ukamaka.dorothy@uniabuja.edu.ng;

age and side. Mean ONSD of 118 head injury patients with CT signs of raised ICP was $6.0\text{mm}\pm 0.7$ while mean ONSD of 38 head injury patients without CT signs of raised ICP was $4.3\text{mm}\pm 0.7$. ONSD was slightly higher in patients with significant midline shift compared with patients without shift but no correlation with degree of shift. The ONSD value above which raised ICP can be predicted with the highest sensitivity and specificity was $>5.2\text{mm}$ with Receiver Operating Characteristic curve (ROC) demonstrating an area under the curve of 0.9796 ($p\text{-value} < 0.0001$) with specificity of 93.5% and sensitivity of 90.7%.

Conclusion: There is a positive correlation between ONSD measurement on CT and intracranial pressure. This measurement is therefore recommended as an additional indirect radiological marker of raised ICP. Normal mean ONSD in a North-Central Nigerian population is $4.4\text{mm}\pm 0.5$ with 5.2mm proposed as the upper limit of normal.

Keywords: Optic Nerve Sheath Diameter; computed tomography; intracranial pressure; head injury; nomogram.

1. INTRODUCTION

The basis of Intracranial Pressure (ICP) monitoring by means of measuring changes in the Optic Nerve Sheath Diameter (ONSD) became practical in the 1990s with different studies showing a correlation between the two indices [1,2,3].

The gold standard for determining raised ICP is the invasive method which involves insertion of intraventricular catheters and continuous monitoring with the attendant risks of intracranial hemorrhage, infections and catheter dysfunction [4]. Invasive ICP monitoring is not available at most referral hospitals in Nigeria and its use not feasible.

Traumatic Brain injury (TBI) is a major etiology of intracranial hypertension in Nigeria with road traffic accidents a major contributor in the productive age group [5].

Neuroimaging of the head is routinely performed in the management of TBI and therefore offers an alternative indirect method of predicting raised ICP by estimation of the ONSD. It can also be used as an additional criterion when deciding if there is need for invasive ICP monitoring. The ONSD is assessed radiologically by Sonography, CT and Magnetic resonance imaging (MRI) with studies showing significant correlation between the measurements in terms of accuracy, sensitivity, specificity and positive predictive value [6,7].

Although Ultrasonography has been successfully used as a point of care modality for the evaluation and monitoring of head injured patients with raised ICP, it is limited in the assessment of the related intracranial

pathologies especially in adults because of the poor ultrasonic window, poor reproducibility and operator dependence while MRI has limitations of time constraints in critically ill subjects [8,9].

CT on the other hand is the imaging modality of choice in acute care settings with ability to evaluate both pathology and effect of brain injury.[9] The concurrent estimation of ONSD whilst carrying out routine evaluation can inform clinical decisions that may avert secondary brain injury.

In order to prevent the deleterious effect of raised ICP on brain parenchyma, there is urgent need for early detection of this condition by a simple, quick, reliable and easily reproducible, noninvasive method which is offered by Computed Tomography.

Radiologic findings that suggest raised ICP have been documented with an earlier study showing that a normal initial CT scan in patients with closed head injury does not preclude increased ICP [10]. This further validates the need for additional predictors of raised ICP.

Considering that this is the most used neuroimaging technique in acute head trauma with potential for accurately detecting the intracranial causes of raised ICP and assisting in deciding the precise intervention needed, there is further need for the validation of the ONSD measurement on CT as a radiological parameter of raised ICP in our locality. Since cranial CT scans also contain optic nerve size data, the purpose of this study was to utilize existing retrospective CT scan data to establish the normative values in our environment, evaluate the relationship between the ONSD and raised ICP and to determine the measurements that can objectively predict raised ICP.

2. METHODOLOGY

This observational retrospective study was conducted using retrieved data from the Picture Archiving and Communication System (PACS) of 356 patients who had cranial CT scan at the Radiology department of University of Abuja Teaching Hospital in North Central Nigeria from 1st March 2016 to 28th February 2020. The sample Volume was estimated from a related study undertaken in Nigeria [11]. The study groups included 158 patients referred for cranial CT examination on account of TBI and 200 patients with relatively normal brain findings and non- ophthalmic clinical indications. All studies were performed with a Hispeed Toshiba 16 slice CT scanner using 5 mm slice thickness at interval of 3 mm. Use of intravenous contrast for controls was determined by the clinical indications but not used for TBI patients. Axial images were viewed at constant window level and width settings of 50 and 250 H respectively [12], by two experienced radiologists with more than 5 years' experience each, using the established protocols. ONSD was measured at 3mm retrobulbar region on axial CT images in a plane parallel to the optic nerve sheath complex using the electronic caliper in the work station. Vertical lines were placed on the outer margins

of the dural sheath while the ONSD was placed as the horizontal distance between the 2 vertical lines (Fig. 1).

The data was grouped into three; A: Patients without head injury, B: head injury patients without clinicoradiologic evidence of raised ICP and C: Head injury patients with at least one CT sign of raised ICP.

Main exclusion from the data were asymmetric scans and clinicoradiologic evidence of orbital pathology including facial and orbital trauma.

2.1 Data Analysis

Descriptive statistics methods for analysis were mean, median, minimum, maximum and standard deviation. Student's t test and Analysis of variance (ANOVA) test were used accordingly to test significant difference between various levels of variables under study. Receiver Operator characteristic curve (ROC) was drawn to establish the optimal cut-off value of ONSD and Pearson correlation were used to evaluate relationship between variables which included age, gender, left and right sides with level of significance set at 0.05.

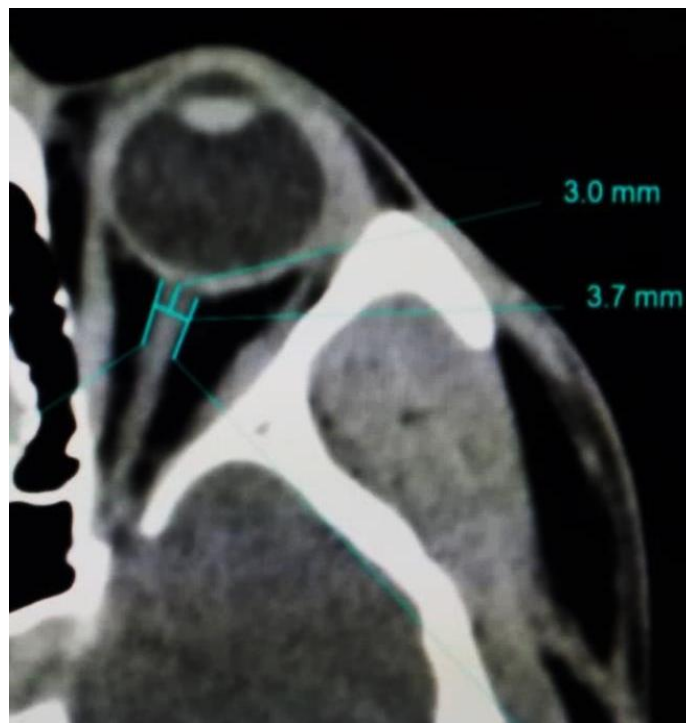


Fig. 1. ONSD at 3mm retrobulbar, axial CT scan

3. RESULTS

Age range of 200 patients with normal brain findings (Group A) was 1 – 90years (mean 40± 19.6.) with male: female ratio of 1.4:1. Mean binocular ONSD was 4.4mm±0.5 (range3-5.6mm) with no difference between the right and left sides. Mean ONSD for females was 4.3mm ±0.5 (range 3.4- 5.6) while males were 4.5±0.5, (range 3.0- 5.6). Result of student's t test depict a significant difference ($P=0.006$) between the mean ONSD of the genders especially the right ONSD of the genders with higher values in males. (Table 1).

Comparison of optic nerve sheath diameter by age group shows no significant difference ($P=0.43$) for both left and right optic nerves at 0.05 level of significance. (Table 2).

Analysis of 156 patients with head injury showed that 118 (74.7%) had CT signs of raised ICP (Group C) while 38(24,3%) had none (Group B). Mean age of the 118 patients with CT signs of raised intracranial pressure was 35.3±16 (range1 – 79), with male: female ratio of 4.4:1. Mean binocular ONSD was 6.0mm±0.7 (range 4.3-8.5mm) with no significant difference between the genders ($P=0.76$) or left and right optic nerves ($P=0.89$). Comparison of ONSD in the

patients with CT signs of significant midline shift (, MLS) (56.8%) and those with generalized edema without shift (43.2%) showed higher values in patients with MLS with significant difference noted on the left optic nerve($P=0.021$). Patients with MLS were also significantly older ($P=0.003$). (Table 2, Fig. 2).

Mean ONSD of 38 head injury patients without CT signs of raised ICP was 4.3±0.5mm.

Comparison of the mean ONSD of the three groups of analyzed data showed no statistically significant difference ($P=0.68$) between group A and B but a significant difference ($p<0.0001$) with patients that had additional CT signs of raised ICP (group C). (Table 3)

There was also a significant difference ($P=0.017$). in mean age between patients with head Injury (35.3±16.1 years) and those without head Injury (40.3±20.1 years). A ROC curve for elevated ICP was drawn to establish the optimal cut-off value of ONSD which demonstrated an area under the curve (AUC) of 0.979 (95%C. I 0.968- 0.991) with a Chi-square $P = 0.0001$. Mean binocular cut-off value of 5.2mm yielded the best test characteristics and accurately predicted raised ICP with sensitivity of 90.7% and specificity of 93.5% (Table 4, Fig. 2).

Table 1. Characteristics of ONSD in normal non head injury patients

Characteristics	Overall	Females	Males
	200 (62.9%)	82(41%)	118(59%)
(mean±SD, range)	40± 19.6(1-90)	40.5±18.2(1- 80)	40.1±21.4, (1-90)
ONSD, mm(mean±SD)	4.4±0.5	4.3±0.5	4.5±0.5†
Right ONSD, mm(mean±SD)	4.4±0.5‡	4.3±0.5	4.5±0.6†
Left ONSD, mm(mean±SD)	4.4±0.6‡	4.3±0.6	4.4±0.6

†significant difference between mean binocular and right ONSD of genders($P=0.006$). ‡ No significant difference between mean ONSD of left and right sides ($P=0.21$)

Table 2. Characteristics of patients without head injury by age group

Characteristics	1-15years	16-19years	≥40years	P value
Number (%)	26(12%)	66(33%)	108(54%)	
Age, years (Mean±SD)	7.0±4.7	28.3±7.4	55.6±10.9	
ONSD, mm (Mean±SD)	4.3±0.5	4.4±0.5	4.4±0.5	0.43
Right optic nerve, mm (Mean±SD)	4.3±0.5	4.4±0.5	4.4±0.6	
Left optic nerve, mm (Mean±SD)	4.3±0.6	4.4±0.5	4.4±0.6	

Table 3. Characteristics of ONSD in head injury patients with CT signs of raised ICP

[†] Characteristic	Overall	Male	Female	Generalized edema	Midline shift
Age (mean±SD)	118 35.3±16	96(81.4%) 33.4±15.2	22(18.6%) 43.6±17.6	51(43.2%) 30.4±14.6) †	67(56.8%) 38.8±16) †
Mean Binocular ONSD	5.9±0.7	6.0±0.7	5.9±0.7	5.8±0.6	6.0±0.7
Right ONSD (mean±SD) ‡	6.0±0.7	5.9±0.7	5.8±0.7,	5.8±0.7	5.9±0.7
Left ONSD (mean±SD) ‡	6.0±0.7	6.0±0.7	5.9±0.8	5.8±0.6†	6.1±0.8†

[†]significant difference between mean ONSD of generalized and MLS($P=0.021$), and age, ($P=0.003$), ‡ No significant difference between mean ONSD of right and left optic nerves($P=0.89$) and genders($P=0.76$)

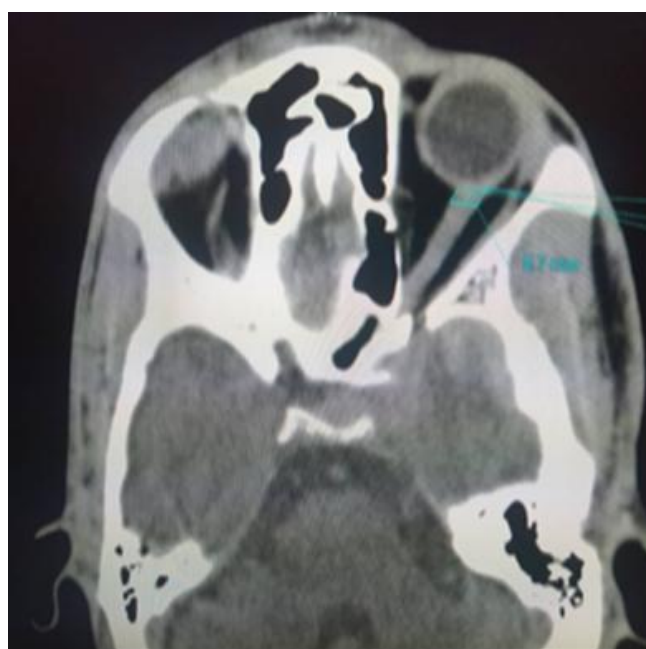

Fig. 2. Axial CT of left temporal lobe contusion with increased ONSD

Table 4. Comparison between normal ONSD and Intracranial Hypertension (ICH)

Characteristics	Normal(A)	TBI without raised ICP(B)	TBI with raised ICP(C)	P value
Mean(mm)	4.4±0.5†	4.3±0.7	6.0±0.7†	0.0001
95%CI	4.3-4.47	4.07-4.5	5.87-6.13	
Minimum(mm)	3.0	2.4	4.6	
Maximum(mm)	5.6	5.9	8.5	
count	200	38	118	

Table 5. AUC, sensitivity and specificity of optimal mean ONSD

AUC	95% CI	Cut-off (≥)	Sensitivity (%)	Specificity (%)	NPV (%)	PPV (%)
0.9796	0.9679-0.9913	5.20002	90.68	93.5	94.4	89.2

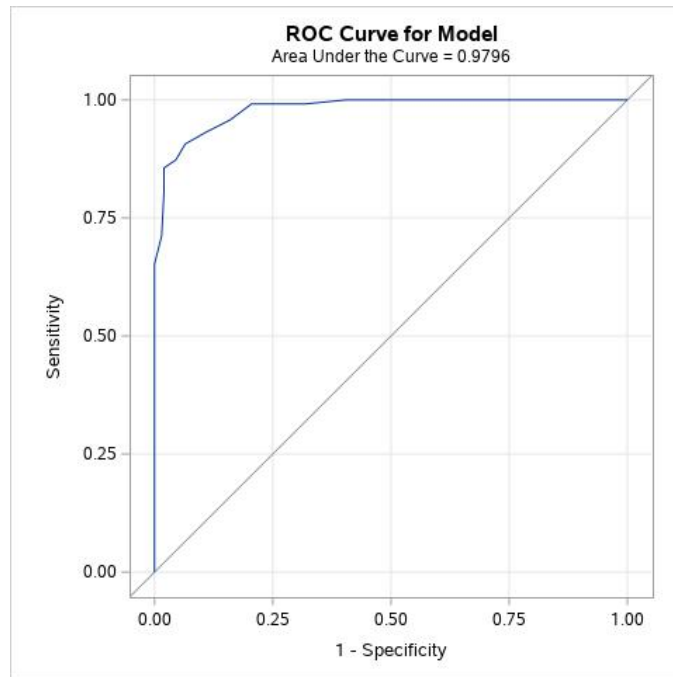


Fig. 3. Receiver operating characteristic curve for optimal ONSD

DISCUSSION

In 1996 Helmke and Hansen [13] demonstrated that, the ONSD increased by up to 60% at a distance of 3 mm behind the globe compared with only 35% at 10 mm thus confirming Liu and Kahn’s observations and forming the basis for the measurement of ONSD at 3mm behind the globe since the ICP changes are maximally reflected at this point.

Earlier studies have shown that ONSD measurement by CT is a much stronger predictor of ICP compared to other CT features, with the risk of in-hospital mortality doubling with each 1 mm increase in ONSD. [14,15] Another study reported a strong association between increased ONSD on CT and patient mortality was shown to be related to raised ICP occurring very early after trauma [16].

Similar studies using CT imaging modalities have however shown slight variations in the obtained measurements with wide thresholds and cut off values of the ONSD. Review of existing literature showed that this heterogeneity is most likely due to the different techniques of measurement used by the different researchers.

Of the 200 controls in the index study, the mean ONSD diameter of 4.4mm±0.5 (range 3-5.6mm)

is similar to that of Ozgen et al [12] who also got comparable ONSD of 4.4 mm (estimated normal range of 3.2–5.6 mm). This marked similarity is most likely due to the fact that the technique (window level and width (50/250) of both studies are the same.

Differences in ONSD value with window setting and location is reflected by Lee et al [17] in a study of Korean patients, using window level of 10–15 and width settings of 300 and 330 HU at waist region and Majeed et al. [18] using mediastinal window at 3mm retrobulbar. They recorded mean ONSD as 4.1 mm and 5.73mm respectively confirming the finding that changes made in the window level and width settings on CT scanning results in different values with respect to the intraocular contents.[12] The different studies are however in agreement in the sense that no correlation was found between ONSD and age or side. Unlike the above-mentioned studies however, we recorded significantly higher ONSD in males.

Despite the importance of assessment of ICP in acute settings, there has been no consensus on the optimal cut-off value of abnormal ONSD to indicate elevated ICP with values varying with method of measurement with a range of 5.3mm-6 mm [17-20].

Our study shows an overall binocular mean ONSD $6\text{mm} \pm 0.7$ with cut off value at 5.2mm in patients with other radiologic signs of raised ICP. This showed a marked similarity with a Nigerian study which compared both ultrasonography and CT ONSD and reported a mean normal binocular ONSD of $4.5 \pm 0.22\text{mm}$, raised ICP mean ONSD $5.7 \pm 0.59\text{mm}$ and cut-off value that best predicts raised ICP as evidenced by at least a sign on cranial CT as 5.2mm . [11] The similarity in study population could account for this.

Vaiman et al. [19] noted that the presence of ONSD greater than a threshold of 5.5mm is significantly predictive of invasively measured elevated ICP, similar to the study of Tae Kyoo Lim [20] which shows that ONSD of $>5.5\text{mm}$, measured on CT, is a good indicator of ICP elevation. It however should be noted that though measurement were taken 3mm retrobulbar, the window setting is different from the index study.

Luyt et al. [21] in their study showed that ONSD measurement of $\geq 4.8\text{mm}$ yielded the highest combined accuracy for indicating elevated Lumbar Puncture opening pressures $>20\text{cmH}_2\text{O}$. Raising the ONSD cut-off to $\geq 5.0\text{mm}$ decreased sensitivity to 85.7% but increased specificity to 100% for raised LP opening pressure. This measurement was taken at the less distensible 'waist' region of the optic nerve sheath and can therefore be adduced as a reason for the disparity.

ICP has also been strongly correlated with ONSD in other studies, regardless of the imaging modality used. Mean sonographic optic nerve sheath diameter obtained in the same institution as the index study was $4.20 \pm 0.38\text{mm}$ (range $3.91\text{--}5.20$) [22].

A retrospective study of 38 patients who required both invasive ICP monitoring and MRI, noted that the best single retro-orbital ONSD cut-off value was 5.82mm . [23] They however increased their sensitivity for detecting raised ICP to 100% by lowering the cut-off to 5.3mm which is similar to the values obtained by the index study with a sensitivity of 90.7% for a cut of 5.2mm .

MLS has prognostic value in the assessment of patients with traumatic brain injury. Das et al [24] showed that higher ONSD was observed in patients with moderate and severe TBI and good correlation with occurrence of diffuse cerebral edema, presence of subdural and extradural hematoma but no statistical significance when taken in isolation. Our study is in agreement in that it shows slightly higher measurements in

patients with significant MLS ($>5\text{mm}$) compared those without MLS. However, the degree of the MLS or side of herniation did not affect the measurement of ONSD.

We recorded mean ONSD of $4.3 \pm 0.7\text{mm}$ in clinically stable head injury patients without other clinoradiologic signs of intracranial hypertension. There is no significant difference with the general population but a statistically significant difference in patients with radiologic signs of raised ICP. This finding further validates the additional inclusion of ONSD as a measure of ICP. The optimal cut-off value of $\geq 5.2\text{mm}$ which demonstrated an area under the curve of 0.979 (95% CI $0.968\text{--}0.991$) with a Chi-square p-value < 0.0001 yielded the best test characteristics and predicted raised ICP with sensitivity of 90.7% and specificity of 93.5% .

Our study is limited by its retrospective nature making it difficult to indicate the duration of the head injury which may invariably affect the values. Further correlation with intracranial monitoring may be recommended as the gold standard.

CONCLUSION

There is a positive correlation between ONSD measurement on CT and intracranial pressure. This measurement is therefore recommended as an additional indirect radiological marker of raised ICP. Normal mean ONSD in a North-Central Nigerian population is $4.4\text{mm} \pm 0.5$ with 5.2mm proposed as the upper limit of normal.

CONSENT

As per international standard or university standard, patients' written consent has been collected and preserved by the author(s).

ACKNOWLEDGMENT

We acknowledge the contribution of staff of Radiology department.

ETHICAL APPROVAL

This study was approved by the Human research and ethical committee of the Hospital (Approval number: UATH/HREC/PR/2020/010/008) The data was anonymized for this purpose.

COMPETING INTERESTS

Authors have declared that no competing interests exist.

REFERENCES

1. Vaiman M, Gottlieb P, Bekerman I. Quantitative relations between the eyeball, the optic nerve, and the optic canal important for intracranial pressure monitoring. *Head & face med.* 2014; 10(1):32.
2. Liu D, Kahn M. Measurement and relationship of subarachnoid pressure of the optic nerve to intracranial pressures in fresh cadavers. *Am J Ophthalmol.* 1993; 116(5):548–556. [PubMed]
3. Hansen HC, Helmke K. Validation of the optic nerve sheath response to changing cerebrospinal fluid pressure: ultrasound findings during intrathecal infusion tests. *J Neurosurg.* 1997;87(1):34–40.
4. Messerer M, Berhouma M, Messerer R, Dubourg J. Interest of Ultrasound Optic Nerve Envelope Diameter for the Noninvasive Detection of Intracranial Hypertension. *Neurochirurgie.* 2013; 02(001): 55-59.
5. Itanyi DU, Kolade-Yunusa HO. Computerized tomography imaging features of head injury in Abuja, Nigeria's Capital. *JAMMR.* 2017 ;20(6):1-9.
6. Kalantari H, Jaiswal R, Bruck I, Matari H, Ghobadi F, Weedon J, et al. Correlation of optic nerve sheath diameter measurements by computed tomography and magnetic resonance imaging. *Am J Emerg Med.* 2013;31(11):1595-1597.
7. Shirodkar CG, Munta K, Rao SM, Mahesh MU. Correlation of measurement of optic nerve sheath diameter using ultrasound with magnetic resonance imaging. *Indian J Crit Care Med.* 2015;19(8):466-470.
8. Merceron S, Geeraerts T. Ocular sonography for the detection of raised intracranial pressure. *Expert Review of Ophthalmology.* 2008;3(5):497-500.
9. Wintermark M, Sanelli PC, Anzai Y, Tsiouris AJ, Whitlow CT, Druzgal TJ, Gean AD, Lui YW, Norbash AM, Raji C, Wright DW. Imaging evidence and recommendations for traumatic brain injury: conventional neuroimaging techniques. *Journal of the American College of Radiology.* 2015;12(2):e1-4.
10. Holliday PO, Kelly DL Jr, Ball M. Normal computed tomograms in acute head injury: correlation of intracranial pressure, ventricular size, and outcome. *Neurosurgery.* 1982;10:25–28.
11. Aduayi OS, Asaleye CM, Adetiloye VA, Komolafe EO, Aduayi VA. Optic nerve sonography: A noninvasive means of detecting raised intracranial pressure in a resource-limited setting. *J Neurosci Rural Pract.* 2015;6(1):563-567.
12. Ozgen A, Ariyurek M. Normative measurements of orbital structures using CT. *AJR Am J Roentgenol.* 1998; 170(4):1093-6.
13. Helmke K, Hansen HC. Fundamentals of transorbital sonographic evaluation of optic nerve sheath expansion under intracranial hypertension II. Patient study. *Pediatr Radiol.* 1996;26(10):706-10.
14. Sekhon MS, Griesdale DE, Robba C, McGlashan N, Needham E, Walland K, et al. Optic nerve sheath diameter on computed tomography is correlated with simultaneously measured intracranial pressure in patients with severe traumatic brain injury. *Intensive Care Med.* 2014; 40(9):1267-1274.
15. Sahu S, Swain A. Optic nerve sheath diameter: A novel way to monitor the brain. *J Neuroanaesthesiol Crit Care.* 2017; 4(s1):S13-18.
16. Masquère P, Bonneville F, Geeraerts T. Optic nerve sheath diameter on initial brain CT, raised intracranial pressure and mortality after severe TBI: an interesting link needing confirmation. *Crit Care.* 2015; 17(151): 1-2.
17. Lee HC, Lee WJ, Dho YS, Cho WS, Kim YH, Park HP. Optic nerve sheath diameter based on preoperative brain computed tomography and intracranial pressure are positively correlated in adults with hydrocephalus. *Clin Neurol Neurosurg.* 2018;167:31-35.
18. Majeed G, Kashyap S, Menoni R, Miulli D, Sweiss R. A noninvasive method for the estimation of increased intracranial pressure in patients with severe traumatic brain injury using optic nerve sheath diameter measured on computed tomography head. *Surg Neur International.* 2019;10.
19. Vaiman M, Sigal T, Kimiagar I, Bekerman I. Noninvasive assessment of the intracranial pressure in non-traumatic intracranial hemorrhage. *J Clin Neurosci.* 2016;34:177-181. DOI: 10.1016/j.jocn.2016.06.008. Epub 2016 Sep 6.
20. Lim TK, Yu BC, Ma DS, Lee GJ, Lee MA, Hyun SY, Jeon YB, Choi KK. Correlation

- between optic nerve sheath diameter measured by computed tomography and elevated intracranial pressure in patients with traumatic brain injury. *J Trauma*. 2017;30(4):140-4.
21. Luyt D, Hurter D, Joubert G. The relationship between computed tomography measurement of the optic nerve sheath diameter and elevated intracranial pressure in non-trauma patients. *S Afr J Rad*. 2016;20(1):1-4.
22. Kolade -Yunusa HO, Itanyi DU. Ultrasonographic Measurement of Optic Nerve Sheath Diameter in Normal Adults. *Ann Int Med Den Res*. 2017;3(2).
- DOI: 10.21276/aimdr.2017.3.2.RD9
23. Geeraerts T, Newcombe VF, Coles JP, Abate MG, Perkes IE, Hutchinson PJ, et al Outtrim JG, Chatfield DA, Menon DK. Use of T2-weighted magnetic resonance imaging of the optic nerve sheath to detect raised intracranial pressure. *Critical care*. 2008;12(5):1-7.
24. Das KS, Shetty SP, Sen KK. A Novel Triage Tool: Optic Nerve Sheath Diameter in Traumatic Brain Injury and its Correlation to Rotterdam Computed Tomography (CT) Scoring. *Pol J Radiol*. 2017;82: 240-243.

© 2021 Itanyi et al.; This is an Open Access article distributed under the terms of the Creative Commons Attribution License (<http://creativecommons.org/licenses/by/4.0>), which permits unrestricted use, distribution, and reproduction in any medium, provided the original work is properly cited.

Peer-review history:

The peer review history for this paper can be accessed here:
<http://www.sdiarticle4.com/review-history/68446>