



Kaposi's Sarcoma of Tonsils

**B. Abdulhakeem^a, F. El Mourabit^{a*}, N. Hmamed^a,
Y. Oukessou^a, S. Rouadi^a, R. Abada^a, M. Roubal^a,
M. Mahtar^a and F. Z. Badi^b**

^a *Department of Otolaryngology, Head and Neck Surgery, University Hospital Ibn Rochd, Casablanca, Morocco.*

^b *Department of Radiology, University Hospital Ibn Rochd, Casablanca, Morocco.*

Authors' contributions

This work was carried out in collaboration among all authors. All authors read and approved the final manuscript.

Article Information

Open Peer Review History:

This journal follows the Advanced Open Peer Review policy. Identity of the Reviewers, Editor(s) and additional Reviewers, peer review comments, different versions of the manuscript, comments of the editors, etc are available here: <https://www.sdiarticle5.com/review-history/112309>

Case Study

Received: 02/12/2023

Accepted: 07/02/2024

Published: 10/02/2024

ABSTRACT

Introduction: Kaposi's sarcoma is a common malignancy in HIV patients. The ENT manifestation of Kaposi's sarcoma is rare and constitutes a factor of poor prognosis. It is a mesenchymal proliferative process of cells of the blood and lymphatic systems, which is induced by viral growth factors, human herpes virus type 8 (HHV8). It is a common tumour in HIV immunocompromised patients.

Case Presentation: Tonsil localization is rare, reporting to us the case of a patient for Behcet's disease undergoing immunosuppressive treatment presenting with a tonsillar manifestation of Kaposi's sarcoma unrelated to HIV immunosuppressive treatment is associated with an increased risk of Kaposi's sarcoma management of these tumours is difficult insofar as immunosuppression must be continued to prevent the occurrence of rejection.

Clinical Discussion: The KS incidence in the general population is 1 case per 100,000 inhabitants. Localization of Kaposi's sarcoma is rare in, Only 4 cases are reported in the literature. Treatment for Kaposi's sarcomas is based on radiotherapy, chemotherapy, surgery and interferons. Surgery is the reference treatment in the case of a small tumour, in a single location, within the same organ, without lymph node involvement.

*Corresponding author: E-mail: fadouaelmourabit1993@gmail.com;

Conclusion: Isolated Kaposi's sarcoma of the tonsil is very rare and can simulate benign or malignant lesions, by data from the literature Symptoms vary according to the seat and volume of the lesion.

Keywords: Tonsillar lodge; kaposi sarcoma.

1. INTRODUCTION

This work has been reported in line with the scare criteria [1]. Kaposi's sarcoma (KS) described at the end of the 19th century by a Hungarian dermatologist practising in Vienna (Austria), Moritz Kaposi, was a rare condition; it experienced a resurgence with the advent of the HIV/AIDS infection pandemic. It is a malignant tumour of endothelial origin linked to infection with the human herpes virus 8 (HHV8) belonging to the Gammaherpesviridae family. It is the most common malignancy in human immunodeficiency virus (HIV) seropositive subjects [1]. "It is a multifocal proliferative condition that can be subdivided into 4 clinical presentations: classic KS, endemic KS (African), iatrogenic KS (associated with immunosuppression/transplantation) and epidemic KS (HIV-related), The location of the Kaposi's sarcoma is rare in the oropharynx and cases affecting only the palatine tonsil are exceptional and generally found in HIV-infected patients" [2]. We report the case of a 43-year-old

woman with tonsillar kaposi sarcoma not associated with HIV.

2. PRESENTATION OF CASE

A 43-year-old patient, with only a pathological history of Behcet's disease, for which the patient has been followed in the internal medicine department for 8 years, treated with several courses of corticosteroid therapy and immunosuppressants, and who consulted for discomfort pharyngeal lateralized especially on the left, evolving for 3 years without improvement under medical treatment, she presented neither odynophagia nor reflex otalgia, the general state was preserved with stable weight. The clinical examination revealed a suspicious-looking ulcers-budding mass in the left tonsillar compartment; magnetic resonance imaging of the tonsillar was requested, objectifying the presence of a well-circumscribed, lobulated, budding mass limited to the left palatine tonsil, massively gaining contrast during injection times, adjacent muscles.

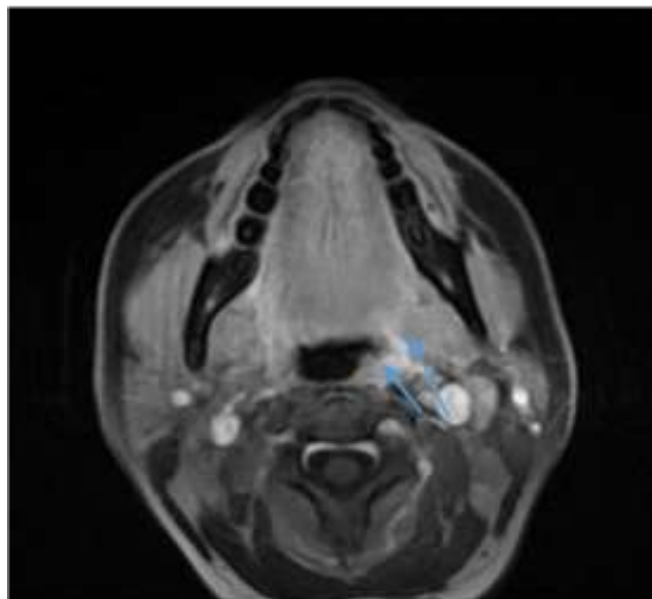


Fig. 1. MRI in axial sections with sequences T2 turbo-spin-echo sequence with fat saturation. Showing a well-circumscribed, lobulated budding mass, limited to the left palatine tonsil (arrow), massively gaining contrast during injection times, without invasion of the adjacent muscle structures

A biopsy was performed under local anaesthesia which could not characterize the atypical cells found on histological examination, another biopsy was performed under general anaesthesia avoiding ulcerated areas with the histological examination; found a densely cellular subepithelial tumour consisting of spindle cells with numerous slit-like spaces containing erythrocytes; some ectatic vessels are present at the edge of the lesion (Fig. 2A). Spindle-shaped tumour cells (400 × H&E) with mild cytological atypia form slit-shaped vascular spaces filled with erythrocytes; some tumour cells contain intracytoplasmic eosinophilic hyaline globules (arrow) characteristic of KS (Fig. 2B), aspect compatible with an amygdala localization of isolated Kaposi's sarcoma, without other associated secondary localization after a meticulous ENT examination, and without

associated satellite adenopathies, a locoregional and remote extension assessment was carried out. The computed tomography examination of the facial bone did not show any tumoral infiltration of the surrounding soft structures or underlying bone lysis or condensation. The general extension assessment was negative. The blood test for anti-HIV 1 and anti-HIV 2 antibodies was negative. Tumour infiltration of surrounding soft structures or underlying bone lysis or condensation. The general extension assessment was negative. The blood test for anti-HIV 1 and anti-HIV 2 antibodies was negative. Tumour infiltration of surrounding soft structures or underlying bone lysis or condensation. The general extension assessment was negative and the tumor was classified as T2N0M0. The blood test for anti-HIV 1 and anti-HIV 2 antibodies was negative.

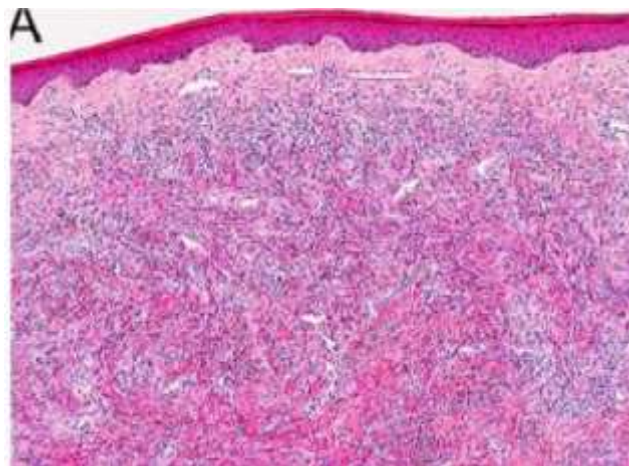


Fig. 2A. Spindle cells with many slit-like spaces containing erythrocytes, with some ectatic vessels

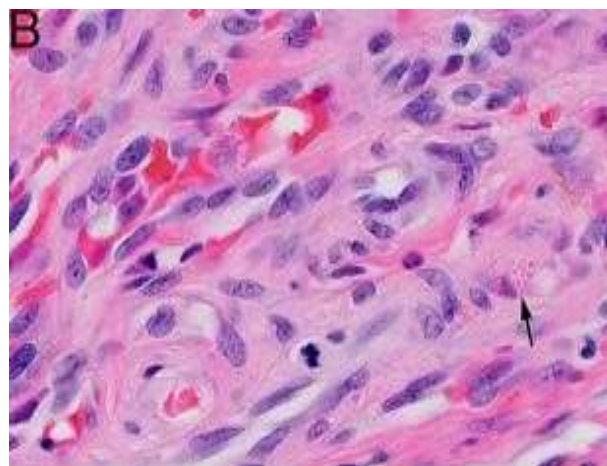


Fig. 2B. Spindle cell proliferation (400 × H&E) with the presence of some tumor cells contain intracytoplasmic eosinophilic hyaline globules (arrow); characteristic of kaposi syndrome

As soon as the diagnosis has been known, a protocol for substitution of treatment with an immunosuppressant with little nephrotoxicity and which above all has an anti-tumor and anti-proliferative action. The patient was presented at the multidisciplinary oncology consultation meeting, and it was decided to perform a tonsillectomy with radiotherapy. The evolution was favorable with no signs of clinical or scannographic recurrence or the appearance of other tumor localizations, the patient was considered in remission.

3. DISCUSSION

“Kaposi's sarcoma is a malignant tumour commonly associated with HIV infection. With an incidence estimated at 1/100,000 in the HIV - population, against 1/20 in the HIV+ population. Localization of Kaposi's sarcoma is rare in the oropharynx and cases only affecting the palatine tonsil are exceptional in HIV- patients. Only 4 cases are reported in the literature” [3,4]. “In 2011, Ozbudak et al. reported the case of an HIV patient with micro-invasive carcinoma and Kaposi's sarcoma in the tonsillar associated with another location of Kaposi's sarcoma in the lower third of the oesophagus” [5]. “In all reported cases, Herpes virus 8 was found in large quantities by immunostaining. This virus is also found in large quantities in certain types of lymphoma and rare tumours such as Castelman's disease. The presence of HHV8 can be detected by PCR or immunolabeling method” [6]. “Human herpes virus 8 (HHV8) was discovered. It belongs to the family Herpesviridae, the subfamily Gammaherpesvirinae and the genus Rhadinovirus. It is considered the causative agent of all forms of Kaposi's sarcoma: classic, endemic, iatrogenic and epidemic” [7]. Indeed, HHV8 codes for different genes likely to lead to a deregulation of the cell cycle, stimulate angiogenesis and inhibit apoptosis potentially involved in the pathophysiology of KS [8]. SKPT may be due to the reactivation of HHV8 in a patient already infected with the virus before starting immunosuppressive therapy. Reactivation of HHV8 appears to be the predominant mechanism in the development of SKPT. Several risk factors have been reported such as ethnic origin, HHV8 seroprevalence rate in the subject's geographic area of origin, sex, age, viral or bacterial co-infections (especially tuberculosis), and finally the type and degree of immunosuppression [9,10,11]. Thus, the incidence of SKPT is higher in countries or ethnic

groups for which the seroprevalence of HHV8 is high. Extracutaneous lesions in KS have become more common since the advent of HIV [12,13,3,4-6,14,15]. The ENT lesions of KD are classically located in the buccal, pharyngeal and laryngeal mucous membranes [16-19,7-10]. They are rarely isolated [18,19] and may however precede the characteristic skin lesion. The most common suggestive skin lesions are represented by plaques. They are associated with nodules in 40% of cases.

“Faced with any unilateral hypertrophy of a palatine tonsil, the diagnoses to be considered are: squamous cell cancer, lymphoma, an infectious pathology, and hypertrophy in the context of a systemic disease” [14]. “It can also be observed in the case of bacillary angioma which is only diagnosed in HIV+ patients” [15]. [14].

“Treatment for Kaposi's sarcomas is based on radiotherapy, chemotherapy, surgery and interferons. Surgery is the reference treatment in the case of a small tumour, in a single location, within the same organ, without lymph node involvement. Chemotherapy can be administered locally (intra-tumour injection) or systemically. Drugs that can be injected locally are Bleomycin, Cisplatin, and Vinblastine. Different drugs like Vincristine, Vinblastine, Etoposide, Bleomycin, Docetaxel and Paclitaxel can be used systemically. These treatments are reserved for locally developed and/or multiple forms of Kaposi's sarcoma” [1]. In our case, the patient underwent a tonsillectomy with several radiotherapy sessions (20 sessions) with a favourable evolution, in particular no signs of recurrence or extension or appearance of other secondary localization [20-23].

4. CONCLUSION

Kaposi's disease mainly affects HIV-positive subjects are exceptional cutaneous localization is frequent but ENT localizations are exceptionally diverse and non-specific, by data from the literature Symptoms vary according to the seat and volume of the lesion.

HIGHLIGHTS

- describe and study the case of a rare location of Kaposi's sarcoma.
- highlight the role of the MRI in the assessment of the extension and the histological study to make the diagnosis.

- the management varies according to the size of the tumor and the staging assessment.

CONSENT

As per international standards or university standards, patient(s) written consent has been collected and preserved by the author(s).

ETHICAL APPROVAL

As per international standards or university standards written ethical approval has been collected and preserved by the author(s).

COMPETING INTERESTS

Authors have declared that no competing interests exist.

REFERENCES

- Hoffmann C, Sabranski M, Esser S. HIV-associated kaposi's sarcoma. *Oncology Research and Treatment*. 2017;40(3):94-8. PubMed | Google Scholar
- Barry B, Matherson S, Gehanno P. ENT manifestations observed during HIV infection. *Encycl Med Chir ENT*, 20-A-10. Paris: Elsevier. 1996;6.
- Keles E, Türker C, Artas G, Karlıdag T. Tonsillar kaposi sarcoma in an HIV-Negative patient: A case report. *Turk Arch Otorhinolaryngol*. 2019;57:46-9.
- Sikora AG, Shnayder Y, Yee H, Delacure MD. Oropharyngeal Kaposi sarcoma in related persons negative for human immunodeficiency virus. *Ann Otol Rhinol Laryngol*. 2008; 117: 172-6.
- Ozbudak IH, Guney K, Mutlu D, Gelen T, Ozbilim G. Bilateral tonsillar and eosophageal kaposi sarcoma in an HIV-negative patient. *Ear Nose Throat J* 2011; 90:23-6.
- Cesarman E, Chang Y, Moore PS, Sald JW, Knowles DM. Kaposi's sarcoma-associated herpes virus-like DNA sequences in AIDS-related body-cavity-based lymphomas. *N Engl J Med*. 1995;332:1186-91.
- Plancoulaine S, Gssaisin A. Epidemiological aspects of human herpesvirus 8 (HHV-8) and Kaposi's sarcoma. *Medicine and Infectious Diseases*. 2005;35(5):314-21. PubMed | Google Scholar
- Wendling J, Francès C, Thervet E, Agbalika F, Morinet F, Bedrossian J, Morel P, Legendre Ch, Lebbè C. Kaposi's disease post-kidney transplantation. *Courier Transplant*. 2001;1:78-81.
- Marcelin A-G. HHV8, Kaposi's disease and organ transplantation: Should we be screening. *Virology*. 2007;11:279-88.
- HAS. Outpatient follow-up of adult kidney transplant recipients beyond 3 months after transplantation. Available: http://www.hassante.fr/portail/upload/docs/application/pdf/suivi_du_transplante_renal_-_recommandations.pdf. (page consulted on 12/12/2012).
- Berber I, Altaca G, Aydin C, Dural A, Kara VM, Yigit B, Turkmen A, Titiz MI. Kaposi's sarcoma in renal transplant patients: Predisposing factors and prognosis. *Transplant Proc*. 2005;37:967-8.
- Abbaszadeh S, Taheri S. Kaposi's sarcoma after renal transplantation. *Saudi J Kidney Dis Transpl*. 2009;20: 775-8.
- Darling M, Thompson I, Meer M. Oral Kaposi's sarcoma in a renal transplant patient: Case report and literature review. *J Can Dent Assoc*. 2004;70:617-20.
- Rubin F, Chartier S, Badoual C, Laccourreye O. Large ulcerated tonsil and bilateral cervical polyadenopathy. *Eur Ann Otorhinolaryngol Head Neck Dis*. 2020;137:83.
- Webster GF, Cockerell CJ, Friedman-Kien AE. The clinical spectrum of bacillary angiomatosis. *Br J Dermatol*. 1992;126:535-41.
- Adjoua RP, Kouassi B, Boguifo J et al. Seropositivity in AIDS tests and chronically progressive ENT conditions (about 30 cases collected in the ENT departments of Abidjan, Ivory Coast). *Pub Med Afr*. 1989;22(100):109-15.
- Olmo A, Vilaseca I, Moraga M, et al. The laryngeal involvement in Kaposi's sarcoma in the acquired immunodeficiency syndrome. *An Otorrinolaringol Ibero Am*. 1993;20(6):589-97.
- Lafeuillade A, Poizot-Martin I, Boulat O, Allegre T, De Jaureguiberry JP. Kaposi's sarcoma of extracutaneous presentation

- during AIDS: apropos of 24 observations. Med Mal Inf. 1994;24:92-5.
19. Koffi-Aka V, Gbery IP, Koffi EK, Hondé M, Ehouo F. Kaposi's disease: About an isolated lymph node location in an adult with unknown HIV. Science and Technology. 2001;24(2):59-61.
 20. Ndjolo A, Njock R, Ngowe NM, et al. Inaugural otolaryngological manifestations of HIV/AIDS infection. Analysis of 76 cases observed in an African environment. Rev Laryngol Otol Rhinol. 2004;125(1):39-43.
 21. Keles E, Türker C, Artas G, Karlidag T. Tonsillar kaposi sarcoma in an HIV negative patient: A case report. Turk Arch Otorhinolaryngol. 2019;57:46-9.
 22. Webster GF, Cockerell CJ, Friedman-Kien AE. The clinical spectrum of bacillary angiomatosis. Br J Dermatol. 1992; 126:535-41.
 23. Keles E, Türker C, Artas G, Karlidag T. Tonsillar kaposi sarcoma in an HIV-negative patient: A case report. Turk Arch Otorhinolaryngol. 2019; 57:46-9.

© 2024 Abdulhakeem et al.; This is an Open Access article distributed under the terms of the Creative Commons Attribution License (<http://creativecommons.org/licenses/by/4.0>), which permits unrestricted use, distribution, and reproduction in any medium, provided the original work is properly cited.

Peer-review history:

The peer review history for this paper can be accessed here:
<https://www.sdiarticle5.com/review-history/112309>