



Virulence of *Fusarium oxysporum* on Kidney Organ Using *In vivo* Mice Model

I. P. Udoh^{1*} and C. I. Eleazar¹

¹Department of Medical Microbiology, University of Nigeria, Enugu Campus, Nigeria.

Authors' contributions

This work was carried out in collaboration between the two authors. Author IPU designed the study, wrote the protocol, and wrote the first draft of the manuscript and managed literature searches. Author CIE performed the statistical analysis and managed the literature searches. Both authors read and approved the final manuscript.

Article Information

DOI: 10.9734/BMRJ/2015/18012

Editor(s):

(1) Gyanendra Singh, Gene Therapy & Louisiana Vaccine Center, School of Medicine, LSU Health Sciences Center, Louisiana, USA.

Reviewers:

(1) Anonymous, Kwame Nkrumah University of Science and Technology, Ghana.
(2) Anonymous, National Institute of Health Research and Development, Indonesia.
Complete Peer review History: <http://www.sciencedomain.org/review-history.php?iid=1092&id=8&aid=9496>

Original Research Article

Received 31st March 2015
Accepted 13th May 2015
Published 29th May 2015

ABSTRACT

Aim: To determine the virulence of *Fusarium oxysporum* on mice kidney organ.

Study Design: Study was carried out using experimental design.

Place and Duration: The study was carried out at University of Nigeria, Enugu Campus. From May 2012–August 2014.

Methodology: Isolates from human infections were obtained from 2000 patients with apparent signs of fungal infections (mycotic keratitis). Plant isolates were obtained from symptomatic plants (decaying or rotting plant substrate) from five different markets and farm lands in Enugu state, Nigeria. A total of 3000 plants were used. Cultures were carried out on Sabouraud Dextrose Agar slants according to modified methods and identifications made. *In vivo* virulence studies in mice were carried out with each individual strain. Histopathology of the kidney organ was performed. Mean survival time (MST) was estimated by the Kaplan-Meier method.

Results: *In vivo* virulence studies of *Fusarium oxysporum* on mice kidney organ resulted in disseminated infection and death of the animals. Histopathological analysis revealed infected kidney with evidence of intense inflammation involving the glomeruli and severe, extensive as well as severe diffuse inflammatory cell infiltration in the interstitium of the cortex. Kidney of control mice

*Corresponding author: E-mail: lilyphils2004@yahoo.com;

showed no pathological features.

Conclusion: The various pathological manifestations and physical signs of infection in the injected mice were indications that *Fusarium oxysporum* isolated were virulent proving the hypothesis that a single strain of *Fusarium oxysporum* can produce disease both in plant and human hosts.

Keywords: *Fusarium oxysporum*; kidney; virulence; *In vivo*.

1. INTRODUCTION

Fusarium infection is life threatening, causing serious morbidity and mortality, and is frequently fatal in immunocompromised host. Invasive mycoses are major cause of death in rapidly increasing population of patients undergoing immunosuppressive therapy in association with cancer and organ / tissue transplantation. The ability of animal and plant isolates to cause infection in mice model requires studies for improving the understanding of evolutionary distant hosts.

In recent years, there has been a marked increase in the incidence of fungal infections due to four factors, namely: more aggressive treatment for other conditions (use of immunosuppressants, transplantations and the use and abuse of antibiotics); the increased incidence of leukemia, lymphoma and AIDS; greater knowledge of clinical mycology; and the greater accuracy of diagnostic techniques [1-3].

F. oxysporum frequently cause infection in the kidney especially in renal transplant recipient [4]. Some fungi cause disease on a single host species, while others have extremely broad host ranges. There is specific virulence factor in a single fungal strain playing distinct functional roles in plant and animal pathogenesis. The molecular mechanisms that determine fungal host range specificity are not fully understood. A number of virulence determinants are clearly host specific [5], therefore evidence for the existence of universal virulence mechanisms shared by fungal pathogens with highly diverse host ranges should be interpreted with care [6,7]. Fortunately, common patterns of host defense also are found in evolutionary diverse groups such as plants, insects and mammals [8]. Evolutionary ancient mechanisms of fungal virulence and host defense might coexist with high virulence and resistance traits that have arisen during later stages of pathogen [9].

The clinical manifestations of invasive fusariosis are often nonspecific, and the host status plays a crucial role in determining the severity, type and

chronicity of the infection [10,11]. In contrast with *Fusarium* infection in normal hosts, which are typically localized and frequently do not require systemic therapy, fusariosis in profoundly immunocompromised patients manifests in four major patterns namely: refractory fever of unknown origin, sinopulmonary infection or pneumonia, disseminated infection, and a variety of focal single organ infection [12,13].

Fusarium species are therefore increasingly implicated as the causative agents of human mycoses particularly in the immunocompromised patient populations, as well as important plant pathogens [14]. Hence certain groups of *Fusarium* also exhibit a predilection toward human and plant diseases, a unique characteristic among the fungi [15].

The epidemiological pattern of corneal ulceration varies significantly from country to country and even from region to region. *Fusarium* species (47.1%) and *Aspergillus* species (16.1%) are the most common aetiological agents of corneal ulceration in India [16]. *Fusarium* species are probably the most toxin producing fungi. The mycotoxins produced include trichothecenes, fumonisins, fusaric acid and moniliformin [17]. Multilocus phylogenetic analyses indicate that diverse isolates within each complex are associated with human infections, with certain specific clones and lineages showing the greatest association. The objective of the present study was to determine the virulence of the isolated *Fusarium oxysporum* using mice model

2. MATERIALS AND METHODS

2.1 Collection of Samples

The mycological specimens used in this study were collected from both humans and plants. Clinical isolates of *Fusarium oxysporum* from humans were isolated from different mycological clinical specimens of 2000 patients seen at different hospitals within Enugu State, while the *Fusarium oxysporum*s from plants were isolated from 3000 various plants within Enugu State. Ethical approval for the study was obtained from

the Ethical Committee of the Department of Pharmaceutics, University of Nigeria, Nsukka. Isolates from human infections were obtained from patients with apparent signs of fungal infections (mycotic keratitis) such as ocular infections (corneal ulcer), skin and nail infections. Plant isolates were obtained from symptomatic plants (decaying or rotting plant substrate) such *Lycopersicum esculentus* (tomatoes), *Elaeis guineensis* (palm fruit), *Ipomoea batatas* (sweet potato), *Solanum tuberosum* (Irish potato), *Musa sapientum* (banana), *Daucus carota* (carrot), *Musa paradisiaca* (plantain), *Carica papaya* (pawpaw), *Persea americana* (Avocado pear), *Citrullus lanatus* (water-melon) and *Capsicum chinense* (fresh red pepper)

2.2 Fungal Isolation and Identification

Culture of the samples was carried out according to the modified method of Ran et al. [14] and further characteristics for identification was made using standard methods of Gupta et al. [18]. Conidial morphology and ontogeny were examined microscopically after 3-10 days of incubation at 28°C. Identification was made according to the overall micro and macroscopic appearance, including the typical appearance and morphology of colonies.

Preliminary microscopic examinations of the fungal specimens were also carried out, using 10% potassium hydroxide except for nail clippings, where 40% was used. A drop of 10% potassium hydroxide solution was placed on a slide. A small portion of the specimen was transferred to the drop with the aid of sterilized cooled moistened wire loop. The preparation was covered with a cover slip and the slide placed in a Petri dish together with a damp piece of filter paper to prevent the preparation from drying out. The preparation was allowed for 20-30 minutes for digestion to take place. The specimen was examined microscopically using x10 and x40 objective lens for fungal elements (hyphae and spores). This was according to the modified method of Prajna Lalitha et al. [19].

Pure cultures obtained were examined for the following: colour seen on the surface of the medium, texture, topography (colony appearance) and pigment production on the reverse of the medium.

Two or three drops of lactophenol cotton blue were placed on a clean slide. A small portion of the fungal growth was collected by digging into the agar with the aid of a sterilized straight

needle. The collected material was transferred to the drop of the lactophenol cotton blue on the slide. A second sterilized straight needle was used to hold the material in position and the other straight wire was used to tease out the material into smaller fragments. The preparation was covered with a cover slip and was examined using x 10 and x 40 objective lenses [20].

2.3 Animal Studies

Virulence studies were determined according to the modified method of Ortoneda et al. [21]. The turbidity standards (McFarland Nephelometry) were prepared. This was used for standardizing the inocula of the fungal isolates. Verification was by plating dilutions of the suspension on SDA plates.

One hundred and sixty test mice and 8 controls (94 males and 74 females, including six pregnant mice); with a weight range of 30-32 g obtained from the laboratory animal centre of the College of Medicine, University of Nigeria, Enugu Campus, Enugu, upon certifying their health conditions and approval by the committee for animal experiments of our institute were housed (eight per cage) in aluminum cages, with corncob bedding and free access to food and water, under standard conditions. Six pregnant mice were included so as to study the effect of the *Fusarium oxysporum* on them. Rules for the protection and care of animals were strictly adhered to following the guiding principles for the Care and Use of Animals in the field of Physiological Sciences [22].

2.4 In vivo Virulence Studies in Mice

Suspensions (0.2 ml of 10^6 conidia / ml) of each of the 20 randomly selected fusarial strains were injected intravenously via the lateral tail vein into groups of eight mice per cage. Mortality was recorded daily for 30 days. Virulence study with each individual strain was performed in 3-6 replicates [21].

2.5 Tissue Burden and Histopathology

Randomly chosen surviving mice (one from each cage) were sacrificed 30 days after inoculation with overdose of halothane using International Standard Procedure. Kidneys of the experimental mice were aseptically removed, and one-half of each was weighed and homogenized in 1 ml of sterile saline. Tenfold serial dilutions of this homogenate were made with sterile saline and

spread onto SDA plates which were then incubated at 28°C. Colonies were counted after 3 days, and the numbers of colony forming units (CFU) per gram of organs were calculated. The remaining half of each organ studied was fixed in 10% neutral buffered formaldehyde for 10 days embedded in paraffin wax and automatically processed. Sections (3 µm in thickness) of the embedded tissues were stained with hematoxylin-eosin, periodic acid-Schiff, and methenamine silver (Grocott) for light microscopy observations. This was according to the modified method of Ortoneda et al. [21].

2.6 Staining Procedures for Histopathological Studies

2.6.1 Mayer's acid –Alum Haematoxylin and Eosin stain

The method used was the modified method of Godwin and Nassar et al. [23,24].

Sections and control slide were de-waxed, hydrated and stained in solution 1 for 10- 30 minutes and were washed thoroughly in running tap water. They were differentiated in solution 2 until only the cell nuclei retain the stain, blued in solution 3 for 1-2 minutes, followed by running tap water for 5-10 minutes. Sections and control slide were counter-stained in solution 4 for 1- 2 minutes and was washed with running tap water until the excess eosin was removed. They were finally dehydrated, cleared and mounted in neutral balsam.

2.6.2 Grocott's Methenamine- silver nitrates

Modified method of Carson and Hladik [25] was used. Sections and control slide were brought to water after dewaxing and hydration. They were oxidized in solution 1 for 60 minutes and were washed in running tap water. Sections and control slide were transferred to solution 2 for 1 minute to remove residual chromic acid and were washed in running tap water for 5-10 minutes. They were then rinsed in several changes of distilled water and impregnated with solution 3 for 30-60 minutes at 58°C. The control slide was examined under the microscope to check for adequate impregnation. They were rinsed in several changes of distilled water, toned in solution 4 for 2-5 minutes and rinsed in distilled water. Sections and control slide were fixed in solution 5 for 2-5 minutes and were washed in tap water. They were stained with solution 6 for 30-45 seconds, dehydrated, cleared and mounted in neutral balsam.

2.6.3 Periodic acid-schiff Stain

Sections and control slide were de-waxed and hydrated. Stained in solution 1 for 5 minutes and were rinsed thoroughly in tap water and in distilled water. The slides were placed in Schiff's reagent (solution 2) for 5 minutes and were placed in 3 baths of solution 3 for 2 minutes in each bath. The slides were rinsed in tap water and were stained in solution 4 for 30 seconds, blued in tap water, dehydrated, cleared and mounted in neutral balsam. This was according method of Nelson et al. [26].

2.7 Statistical Analysis

Data were collected, computed and analyzed statistically using SPSS, version 15.0. Analysis of variance (ANOVA) formulas by Post Hoc Test using Tukey HSD and Games - Howell comparisons were used for multiple value comparisons, while Chi-square tests by cross tabulations were used for Correlations. The correlation tests were also carried out to determine the Pearson coefficient (r) value. Students T-test was used for frequency calculations. Fungal colony counts were converted to log₁₀ values and compared by using the analysis of variance test. Mean survival time (MST) was estimated by the Kaplan-Meier method. Colony count (colony forming unit) in different organs per cages was compared by the log-rank test.

The Probability values were determined by, .05 and .01 significance level, at 95% and 99% confidence limits respectively.

3. RESULTS

Culturally, colonies of the various *Fusarium oxysporum* grew easily and rapidly within three to five days on Sabouraud Dextrose Agar, beginning as a white patch which quickly developed into pale or brightly coloured patches, with some having cottony aerial mycelium. The colour of the *Fusarium oxysporum* isolated was lilac (purple) shade and showed no pigment production. The macroscopic appearance showed the usual loose cottony texture. The total positive fusarium organisms isolated from samples obtained from various body sites of human subjects were 1265 (63.3%) where *F. oxysporum* was 544 (43.0%) while a total of 2,140 (71.3%) plant samples were positive and 1177 (55.0%) was *F. oxysporum*.

The result of the slide cultural technique further confirmed the loose cottony texture of the *Fusarium oxysporum* macroscopically and pattern of arrangement and shape of the macroconidia and microconidia microscopically. Direct microscopy based on potassium hydroxide mount revealed fungal elements (hyaline septated hyphae and spores) from which *F. oxysporum* were subcultured.

Microscopic features and arrangement of macroconidia were usually hyaline, multiseptate, and fusiform to sickle-shaped, mostly with an elongated apical cell and pedicellate basal cell. The microconidia on the other hand were 1-2 celled and curved.

Generally, the mice inoculated with *Fusarium oxysporum* conidia from humans and plants were very dull, malnourished, and could not feed well, for three days, after which, they picked up again. The mice developed various signs of infections such as purplish ring-like lesions on the upper/undersurfaces of their bodies, towards the waist in some of the mice and on the tails in some others. Some of the mice developed lesion on the foot spreading to the toes along with hair loss (Fig. 1).

Generally, the mice inoculated with *Fusarium oxysporum* conidia from humans and plants were very dull, malnourished, and could not feed well, for three days, after which, they picked up again. The mice developed various signs of infections such as purplish ring-like lesions on the upper / undersurfaces of their bodies, towards the waist in some of the mice and on the tails in some others. Some of the mice developed lesion on the foot spreading to the toes along with hair loss.

Development of granuloma was also seen in the mice. The six pregnant mice also infected with the *F. oxysporum* delivered safely after the third inoculation. Two weeks later, the pinkies (litters) also developed similar signs of infection leading to the death. There was no inflammation seen in the control mice while the kidney of most of the sacrificed mice showed intense inflammations. *Fusarium oxysporum* inoculated into the different mice were recovered again from the kidney organ of the sacrificed mice.

Photomicrograph of control kidney showed no inflammation (Fig. 2). Generally there were damages caused by various strains of *Fusarium oxysporum* to the kidney tissues of the mice. Kidneys infected with conidia of *Fusarium*

oxysporum (H1) showed background haemorrhage focally, prominent mononuclear cell infiltrates in the cortical interstitial areas with oedema of the tubules although the micrograph showed no glomerulus (they were preserved).

H127 strain showed infected kidney with much more intense inflammation now involving the glomerulus. The straight arrow, points to the glomerulus and the other curved arrow to the interstitium. This strain is more toxic than that of H1 strain (Fig. 3).

There was severe extensive and severe diffuse inflammatory cell infiltration in the interstitium of the cortex in between the tubules (Interstitial nephritis) with P189.

The kidney infected with conidia of *Fusarium oxysporum* (P191) showed interstitial nephritis with swelling and destruction of the tubules. The tubular lumen was widened. Photomicrograph of kidney infected with conidia of *Fusarium oxysporum* (H131) showed diffuse toxic tubular damage. The kidney organ infected with conidia of P6 strain showed moderate pyelonephritis.

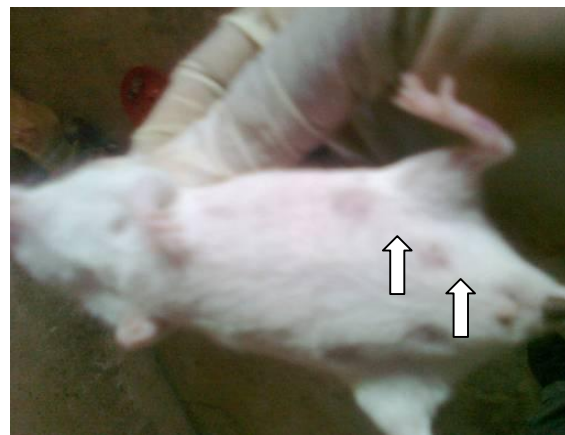

Fig. 1. Mouse injected with *Fusarium oxysporum* (P6) showing signs of infection

4. DISCUSSION

In this study mice model was used to investigate fusarium infection in mammals. The findings showed that the disease symptoms observed in mice are significantly similar to those reported in human fusariosis. Similar findings have also been reported [27,28]. The high incidence of the *Fusarium oxysporum* from human and plant samples in this study showed that *fusarium* has a

predilection towards both human and plants. This et al. [15] who discovered that certain groups of *fusarium* did exhibit a predilection toward human and plant diseases, a unique characteristic among the fungi. Looking at the incidence of the *Fusarium oxysporum* among male and female subjects, this study recorded higher rate of fusarial infection in females than males. There

result is in conformity with the work of O' Donnell was a statistically significant difference ($P = .001$) between males and females in the incidence of infections by *Fusarium* species. There was also a significant association between the variables, gender and site of isolation of samples (cornea, skin and nail), as shown by the p- value .001.

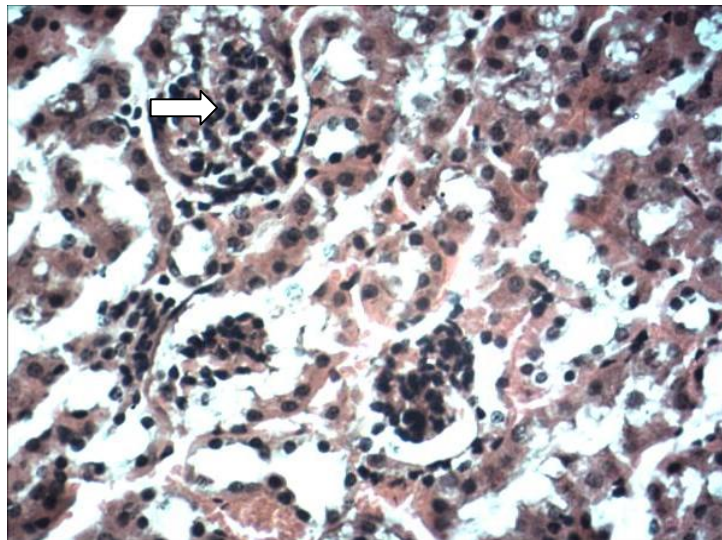


Fig. 2. Photomicrograph of normal kidney (control). Arrow shows a normal glomerulus. The rest background shows tubules cut in both transverse and longitudinal sections

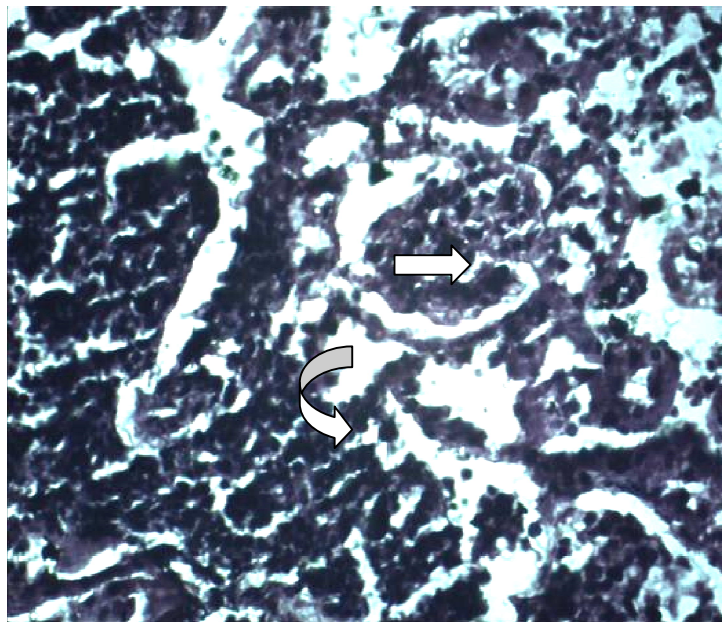


Fig. 3. Photomicrograph of kidney infected with conidia of *Fusarium oxysporum* (H127) showing much more intense inflammation involving the glomerulus. The straight arrow, points to the glomerulus and the other curved arrow to the interstitium

The various pathological manifestations and physical signs of infection in the injected mice were indications that the various species of *F. oxysporum* isolated were virulent. This is in line with the work of Ortoneda et al. [21] who also had similar result when microconidia of tomato pathogenic isolate was injected into the lateral tail vein of immunodepressed mice in order to prove the hypothesis that a single strain of *Fusarium oxysporum* can produce disease both in plant and human hosts.

In this study the human and plants fusarial isolates caused various physical disease signs and pathological features. Skin lesions and development of granuloma was also seen in the mice. This is in line with the work of Schafer et al. [29] who recorded the appearance of macroscopic symptoms in the tail, including necrosis of the skin, swellings and wounds and even loss of the tail tip in immunocompromised mice. The ability of the human and plant fusarial isolates to survive and reproduce in mice, colonize multiple organs and finally lead to the death of the host suggests that some of the strains contain the basic pathogenicity determinants required to cause disease in mammalian hosts.

Histopathological analysis of the kidney tissue of these animals further supports this hypothesis; infected kidney showed much more Intense inflammation involving the glomerulus and showing diffuse toxic tubular damage, indicating that the organism is very toxic. Severe extensive and severe diffuse inflammatory cell infiltration in the interstitium of the cortex in between the tubules (Interstitial nephritis) was also noticed. Kidney infected with conidia of *Fusarium oxysporum* showed interstitial nephritis with swelling and destruction of the tubules leading to widening of the tubular lumen. This confirms that there was invasive growth of *F. oxysporum* in the mice kidney which is evidence that the microconidia germination in the kidney. This is also consistent with the findings of Schafer et al. [29] who also reported invasive growth of the organism in mice and germination of significant number of microconidia in the heart and kidney of the mice.

Fusarium species have a propensity for vascular invasion, resulting in thrombosis and tissue necrosis [30]. It has been speculated that the toxins produced by *Fusarium oxysporum* may enhance the breakdown of tissues and facilitate entry of *Fusaria* into the systemic circulation [30].

The present studies showed that after the *F. oxysporum* had been inoculated, the toxins produced by this pathogen enhanced the breakdown of tissues and consequently facilitate entry of fusaria into the vascular structures and then dissemination.

5. CONCLUSION

This study expresses high occurrence of *Fusarium oxysporum* in both human and plant samples and several isolated strains caused serious damages to the kidney of various mice.

ETHICAL APPROVAL

All authors hereby declare that "Principles of laboratory animal care" (NIH publication No. 85-23, revised 1985) were followed, as well as specific national laws where applicable. All experiments have been examined and approved by the appropriate ethics committee.

COMPETING INTERESTS

Authors have declared that no competing interests exist.

REFERENCES

1. Pasqualotto AC, Denning DW. Diagnosis of invasive fungal infections - current limitations of classical and new diagnostic methods. *Eur Oncol Rev.* 2005;4:1-5.
2. Alexander BD. Diagnosis of fungal infection: New technologies for the mycology laboratory. *Transpt Infect Dis.* 2002;3:32-37.
3. Larocco MT, Burgert SJ. Fungal infections in the transplant recipient and laboratory methods for diagnosis. *Rev Iberoam Micol.* 1997;4:143-146.
4. Benji JS, Singh CJ. Cutaneous fusarium infection in renal transplant recipient; 2011. Available:<http://www.jmedicalcasereports.com/content/s/1/205>
5. Wolpert TJ, Dunkle LD, Ciuffetti LM. Host-selective toxins and avirulence determinants: What's in a name? *Annu. Rev. Phytopatholol.* 2002;40:251-285.
6. Idnurm A, Howlett BJ. Isocitrate lyase is essential for pathogenicity of fungus *Leptosphaeria maculans* to canola (*Brassica napus*). *Eukaryot. Cell.* 2002; 719-724.

7. Lorenz ME, Fink GR. The glyoxylate cycle is required for fungal virulence. *Nature*. 2001;412.
8. Nurnberger T, Brunner F. Innate immunity in plants and animals: Emerging parallels between the recognition of general elicitors and pathogen-associated molecular patterns. *Curr. Opin. Plant. Biol.* 2002;5: 318-324.
9. Sweigard JA, Ebbole PT. Functional analysis of pathogenicity genes in a genomics world. *Curr. Opin Microbiol.* 2001;4:387-392.
10. Boutati EI, Anaissie EJ. *Fusarium*, a significant emerging pathogen in patients with hematologic malignancy: Ten years' experience at a cancer center and implications for management. *Blood*. 1997; 90:999-1008.
11. Torres HA, Bodey GP, Rolston KV, Kantarjian HM, Raad II, Kontoyiannis DP. Infections in patients with aplastic anemia experience at a tertiary care cancer center. *Cancer*. 2003;98:86- 93.
12. Musa MO, AL Eisa A, Halim M. The spectrum of *Fusarium* infection in immunocompromised patients with haematological malignancies and in non-immunocompromised patient: A single institution experience over 10 years. *Br. J. Haematol.* 2000;108:544-548
13. Rabodonirina M, Piens MA, Monier MF, Gueho E, Fiere D, Mojon M. *Fusarium* infections in immunocompromised patients: case reports and literature review. *Eur J Clin Microbiol Infect Dis.* 1994;13: 152- 61.
14. Ran N, Jacob S, Mervyn S, Nathan K, Anna G, Oded Y, Collin B, Htzhack P. Clinical and epidemiological aspects of infections caused by *Fusarium species*: A collaborative study from Israel. *Journal of Clinical Microbiology.* 2004;42:3456-3461.
15. O' Donnell K, Sutton DA, Rinaldi MG, Magnon CK, Cox AP, Ravankar GS, Sanche S, et al. Genetic diversity of human pathogenic members of the *Fusarium oxysporum* complex inferred from multilocus DNA sequence data and amplified fragment length polymorphism analyses: Evidence for the recent dispersion of a geographically widespread clonal lineage and nosocomial origin *Journal of Clinical Microbiology.* 2004;42: 5109-5120.
16. Srinivasan M, Gonzales CA, George C, Cevallos V, Marcarenhus JM, Asokau B. Epidemiology and aetiological diagnosis of corneal ulceration in Madurai, South India. *Br J Ophthalmol.* 1997;81:965-71.
17. Girardi M, Glusac EJ, Imaeda S. Subcutaneous *Fusarium* foot abscess in a renal transplant patient. *Cutis.* 1999;63: 267-270.
18. Gupta AK, Baran R, Summerbell RC. *Fusarium* infection of the skin. *Curr. Opin. Infect. Dis.* 2000;13:121-128.
19. Prajna Lalitha MD, Brett L, Shapiro BL, et al. Antimicrobial susceptibility of *Fusarium*, *Aspergillus* and other filamentous fungi isolated from keratitis. *Arch Ophthalmol.* 2007;125:789-793.
20. Cheersbrough M. *District Laboratory Practice in Tropical Countries Part 2*, Cambridge University Press. 2006;62-246.
21. Ortoneda M, Joseph G, Marta PM, Zaira C, Isabel R, Emilio M, Antonio D. *Fusarium oxysporum* as a multihost model for the genetic dissection of fungal virulence in plants and mammals. *Infection and immunity.* 2004;72:1760-1766.
22. Institute for Animal Research and National Research Council). *Guide for the care and use of laboratory animals.* National Academic Press, Washington D.C. 2011. 27-30.
23. Godwin A. Histochemical uses of haematoxylin - A review. *JPCS.* 2011;1: 24-34.
24. Nassar A, Zapata M, Little JV, Siddiqui MT. Utility of reflex gomori methenamine silver staining for *Pneumocystis jirovecii* on bronchoalveolar lavage cytologic specimens: A review. *Diagn. Cytopathol.* 2006;34:719–23.
25. Carson FL, Hladik C. *Histotechnology: A Self-Instructional Text* (3 ed.). Hong Kong: American Society for Clinical Pathology Press. 2009;137–139. ISBN 978-0-89189-581-7.
26. Nelson PE, Dignani MC, Anaissies EJ. Taxonomy, biology, and clinical aspects of *Fusarium* species. *Clinical Microbiology Review.* 1994;7:479- 04.
27. Dignani MC, Anaissie E. Human fusariosis. *Clin. Microbiol. Infec.* 2004;10(Suppl 1): 67-75.

28. Nucci M, Anaissie E. Fusarium infections in immunocompromised patient. Clin. Microbiol. Rev. 2007;20:695-704.
29. Schafer K, Pietro AD, Gow NAR, MacCllum D. Murine model for *Fusarium oxysporum* invasive fusariosis reveals organ-specific structures for dissemination and long term persistence. PLoS one. 2014;9(2):e89920.
30. Lopes Bezerra LM, Filler SG. Interactions of *Aspergillus fumigatus* with endothelial cells: Internalization, injury, and stimulation of tissue factor activity. Blood. 2004;103: 143–2,149.

© 2015 Udoh and Eleazar; This is an Open Access article distributed under the terms of the Creative Commons Attribution License (<http://creativecommons.org/licenses/by/4.0>), which permits unrestricted use, distribution, and reproduction in any medium, provided the original work is properly cited.

Peer-review history:

The peer review history for this paper can be accessed here:
<http://www.sciencedomain.org/review-history.php?iid=1092&id=8&aid=9496>