



## **Comparative Effect of Ginger (*Zingiber officinale*) Supplement on Hepato-renal Damages Induced by Acetaminophen Toxicity in Wistar Rats**

**Chukwunyere Ogechi Abaekwume<sup>1\*</sup> and Hope Delesi Kagbo<sup>2</sup>**

<sup>1</sup>*Department of Animal and Environmental Biology, Faculty of Sciences, University of Port Harcourt, Nigeria.*

<sup>2</sup>*Department of Pharmacology, Faculty of Health Science, University of Port Harcourt, Nigeria.*

### **Authors' contributions**

*This work was carried out in collaboration between both authors. Author COA designed the study, performed the statistical analysis, wrote the protocol and wrote the first draft of the manuscript. Authors HDK and Author COA managed the analyses of the study. Authors COA and HDK managed the literature searches. Both authors read and approved the final manuscript.*

### **Article Information**

DOI: 10.9734/AJRIMPS/2021/v10i130153

#### Editor(s):

(1) Prof. Lokendra Bahadur Sapkota, Chitwan Medical College, Nepal.

#### Reviewers:

(1) Patrick Yvan Tchebegna, University of Yaounde I, Cameroon.

(2) Nermine Ahmed Ehsan, Menoufia University, Egypt.

(3) Ana Lúcia Hoefel, FSG Centro Universitário, Brazil.

Complete Peer review History: <http://www.sdiarticle4.com/review-history/63885>

**Original Research Article**

**Received 15 October 2020**  
**Accepted 22 December 2020**  
**Published 13 January 2021**

### **ABSTRACT**

**Background:** Acetaminophen toxicity is one of the widespread causes of both planned and unplanned health related issues in the world today. It is a familiar cause of liver and kidney damage particularly in adolescents and children.

**Aims:** With the growing focus in the mitigating and therapeutic roles of herbal drugs in toxicity studies, it is perceptible to investigate the comparative, prophylactic and curative effect of the ginger supplement on acetaminophen-induced liver and kidney damage using wistar rats as model.

**Methodology:**

**Study Design:** Twenty (20) adult male wistar rats weighing 185 g-220 g was obtained from animal house of the department of Pharmacology University of Port Harcourt were divided into four groups having five rats each.

\*Corresponding author: E-mail: [chuogeson@yahoo.com](mailto:chuogeson@yahoo.com);

**Methodology:** Twenty adult wistar rats were divided into four (4) groups of five animals each and treated orally as follows: Group A (normal control) received distilled water (7days), group B received 1000mg/kg acetaminophen (APAP) (2 days). Group C Ginger (GINE+APAP) received ginger supplements 500mg/kg respectively one hour before administration of APAP for 7 days, whereas group D received APAP (2 days) followed by 500mg/kg Ginger for 5 days (APAP+GINE). At the end of the experiment, animals from different groups were anaesthetized, blood samples collected, liver and kidney tissues dissected and subjected to different biochemical, antioxidants, and histopathological test.

**Statistical:** Analysis was done using One Way Anova and Tukey's Post-hoc Test.

**Results:** APAP caused significant ( $P<0.05$ ) decrease in creatinine with significant ( $P<0.01$ ) increase and decrease in liver enzymes and hepatic catalase levels respectively in relation to normal control. Treatment of rats with the ginger supplements attenuated the elevated liver and kidney biochemistry, histopathological alterations by APAP treatment.

**Conclusively:** The extracts demonstrated therapeutic ability and the herbal drugs may be more effective when use prophylactically than curatively. Further research work is needed to validate the finding.

*Keywords: Acetaminophen; toxicity; wistar rats; ginger supplement.*

## ABBREVIATIONS

*NORC (Normal control), APAP (Acetaminophen), GINE (Ginger).*

## 1. INTRODUCTION

N-Acetyl-p-Aminophenol (APAP), also known as acetaminophen, is the most commonly used over-the counter analgesic and antipyretic medication. However, its overdose could leads to both liver and kidney damage. APAP-induced toxicity is considered as one of the primary causes of acute liver failure; numerous scientific reports have focused majorly on APAP hepatotoxicity and nephrotoxicity [1].

Ginger (*Zingiber officinale*) is a plant of the zingiberaceae family, and is from the same family with turmeric. It originated in Malaysia and India and is estimated to have been used for about 5000 years. It is very rich in minerals and vitamins B1, B2, B3, and C but once it is dried, the vitamin is lost entirely [2]. Studies shows that it protects the liver, it acts as a powerful anti-inflammatory agent, protects health and proper functioning of the body, it acts as an appetizer, it reduces intestinal pain, reduces gas and bloating, vomiting, nausea, motion sickness, help to prevent cancer of the colon intestine and reduces the toxicity of certain food. It contains Gingerol, shogaol and zingerones which reduces muscle pain and soreness protect against Alzheimer disease, active ingredient in Ginger helps to fight infections [3,4].

Because of all these basic functions the kidneys perform and the toxins they encounter the kidney

are prone to various problems. Subsequently reliance on medicinal plants is progressively rising in developing countries [5,6]. Their roles as curing or preventing ailment are something no one can neglect, since it is necessary in ethnomedicine. The question is what are these herbal drugs? At what extents were they able to mitigate the hepato-renal toxicity? Are there comparative reports on the most effective method of drugs administrations?

Regularly taking of certain over the counter medication such as no steroidal anti-inflammatory drugs, can cause liver and kidney damage over time [7].

Ginger as a medicinal/ herbal plant possesses various physiological and pharmacologic activities such as anti-inflammatory, anti-ulcer, antifungal, antioxidant and antitoxic as shown in various studies. Generally, it has been extensively used orthodoxically to cure virtually most of the ailments in the world by the traditional herbal users.

Additionally, in the absence of reliable kidney and liver protective and curative drugs in modern medicine; herbal drugs play a major role in the treatment of hepatic and renal disorders. Moreover, scientific literatures have prescribed various medicinal plants/herbs for the cure of hepatic and renal disorders which have curative properties due to the presence of various

complex chemical substances possessing hepato-nephroprotective activities. There is dearth of literature on the comparative, prophylactic and curative effects of this herbal drug on acetaminophen-induced liver and kidney damage.

Therefore, this study was designed to ascertain the comparative prophylactic and curative effect of ginger supplement on acetaminophen induced liver and kidney damage.

## 2. MATERIALS AND METHODS

### 2.1 Procurement of Animals

Twenty (20) healthy adult wistar rats weighing 185-220 g were obtained from the animal house of the Department of Pharmacology of the University of Port Harcourt.

The rats were maintained under 12 hour's light-dark cycle. Rats' were housed in polypropylene cages and fed with finishers' marsh. They were allowed free access to regular tap water *ad libitum*.

Rats were acclimatized for one week before the start of the study. Handling of experimental animals was in accordance with the National Institute of Health Guide for care and use of Laboratory Animals [8].

### 2.2 Experimental Design

The prophylactic studies were done according to the method described previously by (Daszeasah, 2013) in Kumasi Ghana, with slight modifications. The modification is that in our work, the test drugs was given one hour before administration of acetaminophen whereas in the work of [9], the toxin was administered few minutes before toxins administrations. This is where the animals were administered with the test drugs for a period of time before the administration of the toxin. Twenty (20) adult wistar rats were divided into six groups having 5 rats each (n=5). The powder supplements of the herbal drug were dissolved in distilled water.

The animals were fasted for twenty-four hours, prior to the experiment under standard laboratory condition, but were allowed free access to water *ad libitum*. After 24 hours, group A which serves as normal control (NORC) received distilled water (0.5 ml/kg) orally from the 1<sup>st</sup> day of the experiment to the seventh day. Acetaminophen (APAP) group which serves as negative control group received a single dose of acetaminophen

(APAP) (1000 mg/kg) dissolved in 5 ml of distilled water orally for two days. Ginger (GINE+APAP) group, were given powdered ginger powder supplement dissolved in distilled water (500 mg/kg) orally, Acetaminophen capsule dissolved in distilled water was given one hour after administering powder supplement orally for seven days (Prophylactic group).

APAP+GINE which served as curative group were administered with Acetaminophen only on day 1 and 2 and the drug supplement from day 3 to day 7 according to the method described by (Matthew et al., 2011) with slight modification. Mathew et al., 2011, treated with acetaminophen from day 1-7 and extracts day 3-7 but in our work, acetaminophen was only administered for 2 days and ginger supplement administered from day 3-7 without acetaminophen administrations.

The weight of the animals was measured on the first, fourth, and seventh day of drugs and extracts administration respectively and dosage administrations adjusted according to changes in body weight.

Twenty-four hours after drugs administrations the animals in each group were anaesthetized. Blood samples were collected. After blood samples collection, animals were sacrificed, liver and kidney tissues removed for histopathological tests [10,11].

### 2.3 Biochemical Evaluation

All the rats were fasted for 12 hours at the end of the treatment period. The blood was collected by cardiac puncture using sterile disposable syringes under mild chloroform anesthesia. Sera were separated out by centrifuging at 3000rpm for 10 minutes to get serum for Biochemical parameters study. The animals were then sacrificed by cervical and homogenized for histopathological studies.

### 2.4 Liver and Kidney Enzymes Assessment

Using the standard liver enzymes Kidney biochemical assessment method, the serum collected was assayed. Liver enzymes assayed are; Alanine Aminotransferase (ALT), Alkaline Phosphatase (ALP) and Aspartate Aminotransferase (AST), Bilirubin, Total Protein, and Albumin levels. Kidney enzyme assessments like Creatinine, Blood Urea Nitrogen (BUN), and cholesterol. Blood

Electrolyte such as sodium, potassium, chlorides were measured using the Hitachi 902, Automatic Chemical Analyzer.

## **2.5 Histopathology**

The liver tissue was dissected out and fixed in the 10% formalin, dehydrated in gradual ethanol cleared in Xylene and embedded in paraffin wax sectioned (50  $\mu$ m) with a rotary microtome and were stained with Hemotoxylin and eosin (H&E).

The liver sections were evaluated histologically with light microscope with camera attached to it. The liver sections were scored and evaluated to the severity of the hepatic injury.

The kidney was freed from connective tissue coverings and gently removed, weighed and examined microscopically 3-5 mm<sup>2</sup> thick pieces were excised from the organ and fixed in 10% formations solutions, dehydration in ascending grades of alcohol (ethanol), cleared in xylene and embedded in paraffin. 50  $\mu$ m thick sections were obtained and subsequently stained with eosin and hematoxylin and PAS and examined under light microscope [5].

## **2.6 Antioxidant Studies/ Biomarkers**

Hepatic and Renal Antioxidant: GSH (Glutathione), SOD (Superoxide Dismutase), MDA (Malondialdehyde) and Catalase (CATA) were determined using method described by Subramaya S, et al. [12].

## **2.7 Statistical Analysis**

Statistical Analysis was conducted using Statistical package for Social Sciences (SPSS) version 16.0 (Chicago IL, USA) The mean value of data collected was represented as means, and standard error of mean (S.E.M). The data were analyzed using one-way analysis of Variance (ANOVA) and the difference between the groups was determined using Tukey's Post Hoc test. The level of significance was set at 5%.

## **3. RESULTS AND DISCUSSION**

### **3.1 Effects of Extracts on Biochemical Parameters**

#### **3.1.1 Effect on the liver enzymes**

The effect of the drugs on serum enzymes of APAP intoxicated rats is shown in Table 1.

GINE +APAP treatments, significantly ( $P < 0.01$ ) increase the levels of AST, ALP, ALT. AST compared to normal control but no significant decreased the levels of AST, ALP, ALT. AST= (98.20-88.40), ALP (58.40-55.80), ALT (48.60-43.40) compared to negative control.

#### **3.2 Effect on the Kidney Biochemistry**

Table 2 showed that, there was significant (98.40-130.00) elevation in creatinine level on the kidney biomarkers of the group administered with APAP compared to normal control.

In (GINE+APAP) group, there was significant ( $P < 0.05$ ) reduction in creatinine level (130.00-115.20) compared to negative control.

#### **3.3 Effects of Different Extracts on the Liver Anti-oxidant Parameter**

Prophylactically, administration of drugs in all treated groups caused a significant ( $P < 0.01$ ) differences in hepatic CAT and GSH in the liver antioxidant parameters in comparison with normal control but curatively there was significant increase (0.43-1.80) catalase in comparison to APAP. As illustrated in Table 3.

#### **3.4 Effect on Renal Antioxidant Biomarkers**

Table 4 shows the effects of drugs administration on renal antioxidant.

Treatments in all the groups showed significant ( $P < 0.01$ ) reduction in the level of renal CAT and renal GSH compared to normal control group.

#### **3.5 Effects on Initial and Final Effects on the Mean Body Weight of Rats**

Though there was weight gain but there were no significant ( $P > 0.05$ ) changes in the body weight of the treated rats in all the groups rather there appear to be general increase in weight of the rats as compared to group A and B. As shown in Table 5.

#### **3.6 Effects on Hepatic Histology**

The hepatic tissues of the experimental animals are illustrated histologically in the photomicrographs presented in plates (1-4). Plates 1 illustrated histologically normal liver showing: hepatocytes (H) that are histologically normal. There was present of central vein (CV) containing blood cells, hepatic sinusoids; that are histologically normal as shown in Plate 1.

**Table 1. Effects of the supplements on the liver function**

Groups	AST (U/L)	ALP (U/L)	ALT (U/L)	TP(g/L)	ALB (g/L)	TB (g/L)	CB (µmol/l)
NORC(A)	57.20±3.99	37.00±2.07	27.00±2.03	63.40±3.54	38.40±0.98	5.34±0.25	4.36±0.42
APAP (B)	98.20±5.77**	58.40±2.38**	48.60±2.82**	65.40±2.52	37.80±0.86	7.60±0.57	3.98±0.42
GINE+APAP(C)	88.40±4.80**	55.80±3.97**	43.40±2.42*	61.00±0.45	39.40±1.36	6.98±0.38	3.86±0.33
APAP+GINE(D)	90.80±3.64**	36.00±1.95	48.80±2.63**	57.60±0.87	30.80±3.40	8.94±0.49**	5.32±0.23

Values are given as mean ± SD for 5 rats in each group; experimental groups are compared with Group A. \*p<0.05, \*\*p<0.01 vs Group B. P: statistical level of significance as determined by one-way Analysis of Variance (ANOVA) followed by Tukey's post-hoc test

**Table 2. Effect on Kidney biochemistry parameter**

Groups	Sodium	Potassium	Urea	Creatinine	Cholesterol	Chloride
NORC(A)	113.80±4.5	5.42±0.27	2.74±0.3	98.40±4.70	42.00±2.78	26.20±3.1
APAP (B)	142.20±88	7.58±10.4	4.68±0.2	130.00±6.1*	49.20±1.24	26.80±1.2
GINE+APAP(C)	140.60±84	6.70±0.89	3.68±0.6	115.20±9.92	52.20±1.6*	26.80±1.6
APAP+GINE(D)	117.00±20	4.26±0.20	4.50±0.9	127.80±9.53*	39.20±2.18	26.80±1.36

Values are given as mean ± SD for 5 rats in each group; experimental groups are compared with Group A. \*p<0.05, \*\*p<0.01 vs Group B.

**Table 3. Effect of the supplement extract on liver biomarkers**

Groups	CATA	SOD	MDA	GSH
NORC (A)	1.83±0.53	0.56±0.12	0.39±0.09	1.46±0.09
APAP ( B)	0.43±0.08**	0.57±0.05	0.34±0.05	0.29±0.03**
GINE+APAP(C)	0.31±0.02**	0.49±0.05	0.51±0.05	0.37±0.02**
APAP+GINE (D)	1.80±0.29	0.92±0.02*	0.27±0.03	0.39±0.03**

Values are given as mean ± SD for 5 rats in each group; experimental groups are compared with Group A. \*p<0.05, \*\*p<0.01 vs Group B. P: statistical level of significance as determined by one-way Analysis of Variance (ANOVA) followed by Tukey's post-hoc test

**Table 4. Effect on renal antioxidant biomarkers**

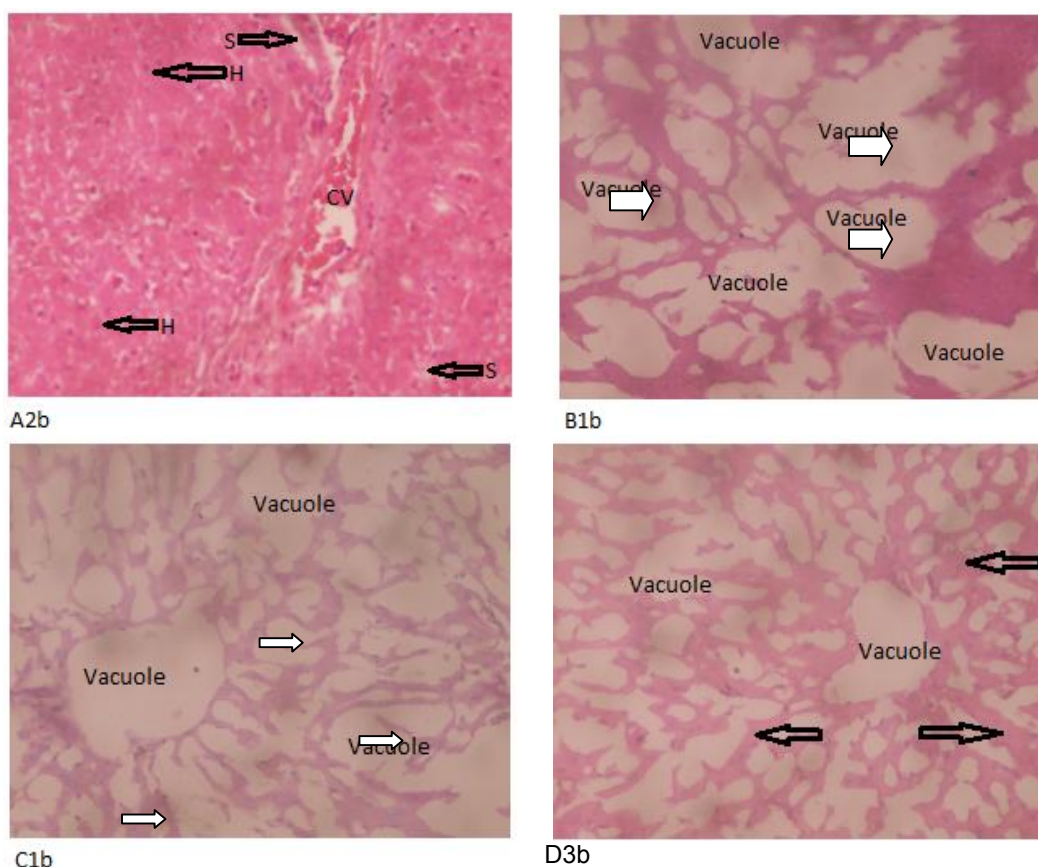
Groups	CATA	SOD	MDA	GSH
NORC (A)	1.32±0.11	0.31±0.05	0.70±0.05	1.11±0.06
APAP ( B)	0.64±0.09**	0.37±0.07	0.57±0.08	0.39±0.01**
GINE+APAP(C)	0.48±0.10**	0.35±0.06	0.60±0.05	0.38±0.01**
APAP+GINE (D)	0.38±0.07**	0.33±0.04	0.71±0.03	0.46±0.03**

Values are given as mean ± SD for 5 rats in each group; experimental groups are compared with Group A. \*p<0.05, \*\*p<0.01 vs Group B. P: statistical level of significance as determined by one-way Analysis of Variance (ANOVA) followed by Tukey's post-hoc test

**Table 5. Effects of the extracts on the mean body weight of rats**

Groups	Initial body weight	Final body weight
NORC (A)	133.60±6.61	139.00±9.34
APAP ( B)	105.00±4.28	128.00±4.62
GINE+APAP(C)	96.20±6.39	114.80±5.95
APAP+GINE (D)	116.00±5.74	123.20±3.26

Values are given as mean ± SD for 5 rats in each group; experimental groups are compared with Group A. No significant difference compared to Group A at p<0.05. P: statistical level of significance as determined by one-way Analysis of Variance (ANOVA) followed by Tukey's post-hoc test



**Plate 1-4. Histopathological photomicrographs of liver tissues of rats treated with acetaminophen after different extracts treatment (\*400). (A1b) normal control, (B1b) acetaminophen (negative control), (C2b) ginger (prophylactic) (G3b) ginger (curative)**



APAP treated rats' groups as illustrated in Plate 2 (B1b) indicated visible severe necrotic areas with centrilobular vein, congestion, dense, polymorphonuclear infiltrate, and vacuolization of hepatocytes and deteriorated cords of hepatocytes as illustrated by white arrow.

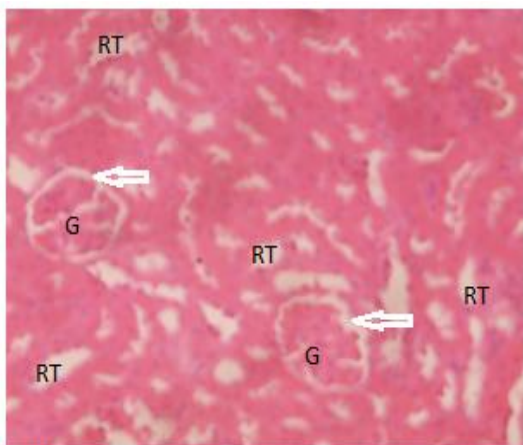
GINE+ APAP treated rats' group as illustrated in Plate 3 (C1b) indicated poorly infiltrated cells and severe injury in the centrilobular region, generalized vacuolation replacing the entire histology of the liver

The liver tissue of group (APAP +GINE) treated rats group as illustrated in Plate 4 (G3b) showed distorted liver tissue with generalized vacuolations with narrow lines of normal hepatocytes.

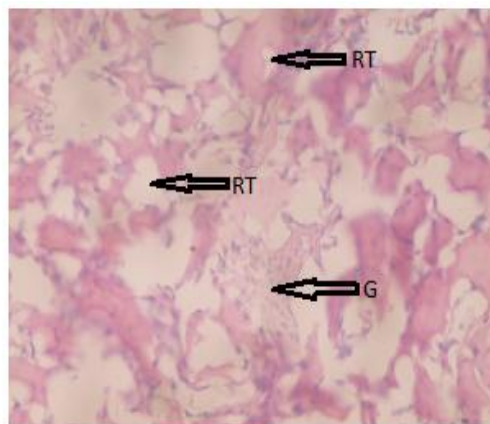
The kidney section of the control group in Plate 5 (NORC), showed histologically normal renal tubules.

Kidney section of APAP group in Plate 6 (B1b) showed kidney sections with severe distortion of the renal tubules, and shrinkage of glomeruli and fatty change as illustrated by black arrow.

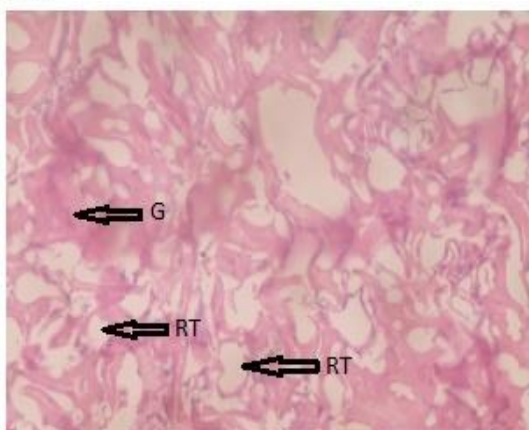
Kidney sections of the rats in GINE+APAP group as shown in Plate 7 (C2b) showed distorted renal tubules that have basis features of renal tubules, distorted glomeruli, and glomerular tufts are not clearly seen, with obliterated bowman corpuscles. Kidney sections of APAP+GINE groups in (Plate 8 (D3b) indicated distorted kidney renal tubules (RT) with some preserved features and distorted glomeruli (G) with sparsely distributed preserved glomeruli.



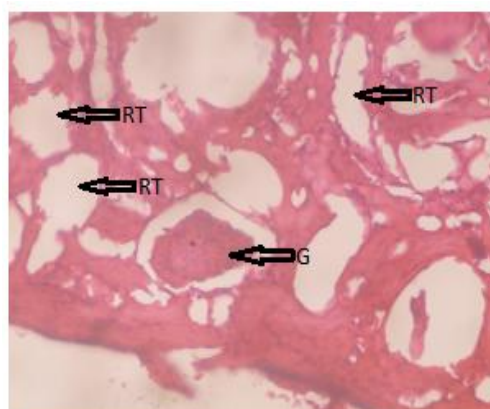
A1b



B1b



C2b



G1b

**Plates 5-8. Histopathological photomicrographs of Kidney tissues of rats treated with acetaminophen after Ginger extract supplement treatment (x400). (A1b) normal control, (B1b) acetaminophen (negative control), (G1b) ginger (prophylactic), (G1b) ginger (curative)**

### **3.7 Discussion**

#### **3.7.1 Prophylactic studies**

Abused of Acetaminophen, cause large amount of APAP to generate cytochrome P450 enzymes Cyp2e1 in rats leading in the formation of reactive metabolite N-acetyl P-benzoquinoneimine (NAPQI), thereby resulting to the saturation of the hepatic glucuronide and sulphate then increase the P450 sulphate conjugation pathway triggering the oxidation pathway [13,14,15]

Damage to or effect on target organs often results in increase in clinical chemistry parameters. Such as ALP, AST, ALT (liver) Urea and creatinine (kidney) increase in levels of the serum creatinine and urea had been considered as index of assessing nephrotoxicity. Severity of the kidney damage is caused by the paracetamol [16]. In the present study, the ability of Ginger supplement to protect or cure drug- induced hepato-renal toxicity was assessed.

The rise in the levels of alanine amino transferase (ALT), aspartate aminotransferase (AST) and alkaline phosphatase (ALP) activities in the serum were used to measure liver damage while rise in the blood urea nitrogen and creatinine were used to measure the level of damage to the kidney. Therefore, serum hepatic biomarkers analysis is important for identification of liver damage [17].

In this work, high level of AST and ALT was shown which indicated that AST and ALT were released into circulation indicating liver damage. Rise in AST and ALT (is a more specific marker of liver damage) showing cellular leakage and loss of functional cohesion of parenchyma cell in the liver.

Acetaminophen overdose or abuse results in permanent obliteration of liver cells in turn resulting in alarming and absolute high elevation in serum level of enzymes ALT, ALP, and AST [18]. This is in agreement with [19,12] who reported that paracetamol intoxication produced a significant increase in AST, ALT ALP. In our work, APAP administration (1000mg/kg) caused acute liver injury in rats, characterized by an increase in serum activity of transaminase and phosphatases (AST, ALT and ALP).

This is also similar to Masoud [20]; Mingzhi [21] who reported that acetaminophen administration produced a significant rise in liver enzymes and

this leakage of enzymes is due to hepatotoxicity which caused the alteration of the activity of the liver function.

When there is damage of cell, cytoplasmic transaminase will be released thereby leading to the damage of the liver structure binding, because these are normally located on the cytoplasm, mitochondrial and microsome released into the circulation after cellular damage [2] or due to the alteration to the cell membrane permeability, increase anabolism and reduction in breaking down of amino transferase. This is also in agreement with [22] who found out that serum levels of both ALT and AST were elevated almost four folds in acetaminophen treated group in relation to control. Decrease in serum, plasma level of total protein, albumin is also the evidence of chronic liver damage.

Similar to our work, Abdel-Azeem AS, et al. [23] reported that acute acetaminophen toxicity induced remarkable elevation on plasma ALT, AST and ALP action and significantly decline in plasma level of total protein and albumin of rats. It is also in agreement with Lebda MA, et al. [24] who revealed that acetaminophen induced toxic injury on the liver of rats as seen by significant decrease in albumin level. This indicated the decrease in capacity of hepatic to synthesize protein and consequently liver weight.

The present study also revealed that administration of GINE+APAP. Ginger caused no significant decrease in serum levels of liver enzymes in prophylactic group relative to APAP group showing the near normal restoration of damaged liver enzymes decrease in the liver enzymes levels triggered by APAP administration.

This result slightly disagreed with Lebda MA, et al. [24] who reported that administration of ginger 100 mg/kg to paracetamol (1000 mg/kg) intoxicated rats showed decrease in serum albumin as compared to paracetamol group. The different in our result can be as a result of different in dosage of ginger. Prophylactically, ginger could not protect against APAP toxic effects on the liver. This is in tune with Ibrahim T, et al. [25] who reported that ginger failed to restore the damaged liver cell and reduced serum albumin indicating severe liver damage. This may be due to the ability of the ginger to increase gastrointestinal absorption of APAP because some active compounds of ginger were reported to stimulate digestion, absorption,



relieved constipation and flatulence by increasing muscular activity in the digestive tract. Also [23] reversibly reported lowered hepatic marker enzymes and restoration of the level of protein. This may also be due to differences in doses concentration of GINE+APAP, time dependant and different route of exposure. This may also be due to different drugs interactions.

Administration of APAP to the rats in our result reviewed that acetaminophen caused elevation in serum blood urea nitrogen and serum creatinine level indicating kidney damage. Our findings were in line with an earlier reported work of [26,16] that sera levels of creatinine and urea in kidney diseases will rise because the rate of production exceeds the rate of clearance due to the defect in kidney function and these elevated state of urea and creatinine had been considered as guide of assessing nephrotoxicity, supporting to this, the disturbance of the renal functions was further reflected on its faulty re-absorptive power of albumin and protein in plasma levels, which led to their facade in high quantities in the urine and thus decreased in sera levels [20].

In addition, attenuation of total protein and albumin associated with improved serum urea and creatinine was a further indication of kidney glomerular damage after APAP injection [27]. Thus, significant rise in creatinine level in the present study confirmed renal damage in rats following APAP overdose. A previous study shows that elevations in the urea and creatinine plasma levels have been demonstrated to the cause of renal disease in a range of animal models and man [16].

Ginger extract supplement exerts its antioxidant effect by quenching free radicals due to the effect of polyphenol compounds (6 Gingerols and its derivatives).

In the APAP treated group, the liver tissue as illustrated in Plates 2 showed distorted and destroyed liver with vacuolation. This is in consistent with Mannem P, et al. [28] who reported ballooning and degeneration as well as sinusoidal congestion of the liver 24 hours after APAP administration. This also agreed with Masoud RE. [20] who reported that in paracetamol treated group, there was distortion of liver architecture, there were also vacuolation of hepatocytes, infiltration with inflammatory cells, Cellular protein after covalent bonding of acetaminophen and its metabolites might trigger some series of events which resulted to liver

damage. This is in line with our result which showed vacuolated hepatocytes, distorted liver and sinusoidal.

Liver architecture of the rats treated with Ginger (GINE+APAP) after acetaminophen administration as shown in Plates 3, in prophylactic use also indicated distorted liver tissue and vacuolation. The prophylactic effects may be due to swift absorption of both acetaminophen and Ginger in the liver tissue. This is similar to Hamed MA, et al. [29] who used lead as toxicant, when treated with Ginger showed regenerated nucleated hepatocytes arranged in cord with obvious sinusoidal arrays, minimal fat vacuoles and minimal inflammatory lymphocytic infiltrations.

The photomicrographs of the renal tissues of the experimental animals when illustrated histologically in plate 5-8. The kidney of the control groups shows glomerular surrounded with bowman capsules and renal tubules of control groups.

Hence, in kidney sections APAP as illustrated in plate 6 caused severe changes in renal cells, distorted renal tubules and glomerular. This is similar to Gulnaz H, et al. [10] who reported toxic effects of APAP on the kidney. This report also agreed with Badwi El SM, Al Tayib OA. [14] who reported that kidney sections of APAP treated group caused severe alterations in renal cells. [13] also reported disorganized glomerulus, dilated and inflammatory tubules. Kidney tissue of the rats treated with Ginger in prophylactic use (GINE+ APAP) as illustrated in plate.3 (C1b) showed indistinct glomerular.

This was in disagreement with earlier report by Eugenio-Perez, [30] that aqueous extract of Ginger has therapeutic potential against APAP induced renal injury in rats by ameliorating the kidney histopathological structure and thus improved the kidney function. This may be due the fact that Ginger and acetaminophen are easily absorbed by the body thus their rapid absorption.

### **3.7.2 Curative studies**

There was also significant increase in ALT and AST levels indicating liver damage and also insignificant decrease in ALP level in curative group indicating the near normal restoration of liver enzymes. The insignificant effect in the activities of ALT and AST is dissimilar to Ibrahim T and Murad S, et al. [25,31] which reported that

administration of Ginger and paracetamol significantly decrease serum ALT and AST as compared to paracetamol. Ginger powder supplement unleashes their antioxidant effect by scavenging free radicals due to its antioxidant called 6- Gingerols and derivatives free radicals (Gingerol, flavonoids, flavones, glycosides and rutin).

In our work, administration of Ginger after acetaminophen administration causes reduction in liver enzymes, Total protein and Albumin compared to B as observed curatively. This is also in consonant with the work of Murad S, et al. [31] who reported that APAP +GINE oral administration were able to decrease the level of ALP. There was also significant decreased in cholesterol levels compared to APAP group. This is in agreement with Murad S, et al. [31] who reported that Ginger can lower cholesterol level.

In the kidney function test, treatment of rats with Ginger insignificantly reduced the elevated level of creatinine caused by Acetaminophen. Ginger might possess the antioxidant characteristics which might have reduce or slow down the spread of the rate of nephrotoxic thereby delaying the on-set of renal damage or stop the effects entirely.

The serum level of total protein, albumin and total bilirubin was also measured. There was significant increase in serum total bilirubin in relation to APAP. In contrast with Abdel-Azeem AS, et al. [23] who reported restoration in total bilirubin after being treated with ginger supplement. The dissimilarity in the result may be due to different in dosages.

Hepatic CAT in Ginger curative was almost closer to normal control group. This is in agreement with Elmasry A, et al. [32] who reported that Ginger restored antioxidant levels and decrease hepatic MDA in acetic acid induced colitis in rats.

Administration of APAP + GINE has negative effect on the hepatic GSH antioxidant and this reduction in hepatic GSH may be due to the interaction of herb and drug [2].

APAP+GINE (Plate 4), the liver tissue showed normal lines of normal hepatocytes and ability to show normal line of hepatocytes in curative use indicated present of antioxidants.

Then curatively, [29] also reported that the structural organization of the liver appeared

almost normal with distinct hepatocytes having regeneration of central vein. This indicated that APAP+ GINE rats' livers are well protected from APAP toxicity when compared to APAP rats' liver (Plate 4).

The renal architecture of rats treated with APAP indicated destroyed renal tubules and shrinkage of glomeruli (Plate 6) indicating total destruction of the kidney structure. This is in agreement with Abdul Hamid Z, et al. [13] who reported disorganized glomerulus, dilated and inflammatory tubules.

(APAP+GINE) there were some preserved features shown with sparsely distributed glomeruli as shown in Plate 8. This was also reported by Eugenio-Perez, [30] that aqueous extract of Ginger has curative potential against APAP induced renal injury in rats by ameliorating the kidney histopathological structure and thus improved the kidney function. Thus, this indicated the antioxidant properties of Ginger.

#### **4. CONCLUSION**

This present study demonstrated that ginger supplement possesses hepato-renal-protective and hepato-renal-curative activities in acetaminophen induced hepato-renal-toxicity on male wistar rats at a dose of 500mg/kg and is preferable prophylactically in treatment of hepato-renal-toxicity on liver and kidney biochemistry but may be more effective curatively in histopathological treatment. In conclusion Ginger supplement drugs may be more effective when use prophylactically than curatively.

#### **CONSENT**

It is not applicable.

#### **ETHICAL APPROVAL**

Animal Ethic committee approval has been taken to carry out this study.

#### **COMPETING INTERESTS**

Authors have declared that no competing interests exist.

#### **REFERENCES**

1. Kaplowitz N Laurie. Drug-induced liver disease (3<sup>rd</sup> edition). Elsevier Incorporated. New York; 2013.

2. Mohammad SI, Mustafa IA, Abdulqader SZ. Ameliorative effects of aqueous extract of *Zingiber officinale* on the cadmium-induced liver and kidney injury in female rats. *Jordan Journal of Biological Sciences*. 2013;6(3):231-234.
3. Shalaby MA, Hamowieh AR. Pharmacological studies on ginger-Pharmacological actions of pungent constituents of 6-gingerol and 6-shogaol. *Journal of Pharmacobiodyn*. 2010;7: 836848.  
Available:<https://www.ncbi.nlm.nih.gov/pubmed/6335723>
4. Leach J. 11 proven health benefits of ginger; 2017.  
Available:[www.healthcare.com](http://www.healthcare.com)
5. Abere TA, Okoto PE, Agoreyo FO. Antidiarrhoea and toxicological evaluation of the leaf extract of *Dissotis rotundifolia* Triana (*Melastomataceae*). *BMC Complement Alternative Medicine*. 2010; 10:71.
6. Odo GE, Avoaja DA, Ivoke N, Debua U EM, Onyeko CC, Ajugwu CG, et al. Effects of Ethanolic extracts of *Pentaclethra macropphylla* leaves in experimentally induced diarrhoea in albino rats (*Rattus novengicus*) *International Journal of Indigenous Medicinal Plant*. 2013;46:1376-1385.
7. Mazhar F, Akram S. Acute renal damage in acetaminophen poisoning. *Journal of Young Pharmacology*. 2016;8(4):505-506.
8. Clark DJ, Gebhart GF, Gonder JC, Keeling ME, Kohn DF. *The 1996 Guide for the Care of Laboratory Animals*. Institute for Laboratory Animals Research Journal. 1997;3(1):41-48.
9. Daszeasah PEA. Safety evaluation and hepatoprotective activity of the aqueous stem bark extract of *Spathodea campanulata*. An unpublished Thesis. Kwame Nkrumah University of Science and Technology, Kumasi; 2012.
10. Gulnaz H, Tahir M, Mumir B, Sami W. Protective effects of garlic oil on Acetaminophen-induced nephrotoxicity in male albino rats. *Biomedical*. 2010;26(7):9-15.
11. Mahmoud MF, Diaai AA, Ahmed F. Evaluation of the Efficacy of Ginger, Arabic Gum, and Boswellia in Acute and Chronic Renal failure. *Renal Failure*. 2012;34:73-82.  
Available:<http://doi.org/10.3109/0886022x.2011.623563>
12. Subramaya S, Venkataraman B, Meeran MFN, Goyal SN, Patil CR, Shreesh O. Therapeutic potential of plants and plant derived phytochemicals against acetaminophen induced liver injury. *International Journal of molecular Sciences*. 2019;19:3776-3918.
13. Abdul Hamid Z, Budin S, Jie N, Hamid A, Mohamed KHJ. Nephroprotective effects of *Zingiber zerumbet* Smith ethyl acetate extract against paracetamol-induced nephrotoxicity and oxidative stress in rats. *Journal of Zhejiang University Science B*. 2012;13:176-185.
14. Badwi El SM, Al Tayib OA. Assessment of ameliorative effects of aqueous extracts of *Moringa oleifera* on acetaminophen-induced nephrotoxicity in rats. *JOSR Journal of Humanities and Social Sciences (LOSR-JHSS)*. 2016;21(9):1-7.
15. Guengerich P. Mechanism of Cytochrome P450 Catalyzed Oxidations. *National Center for Biotechnology*. 2016;8(12):10964-10976.
16. Pathan MM, Khan MA, Moregaonkar SD, Somkuwar AP, Gaikwad NZ. Amelioration of paracetamol-induced nephrotoxicity by *Maytenus emarginata* in male wistar rats. *International Journal of Pharmacy and Pharmaceutical Sciences*. 2013;5(4):471-474.
17. Al-Qudah MMA, Haddad MA, EL-Qudah JMF. The effects of aqueous ginger extract on pancreas histology and on blood glucose in normal and alloxan monohydrate-induced diabetic rats. *Biomed Res*. 2016;27:350-356.  
Available:[https://www.researchgate.net/publication/301649907\\_The\\_effects\\_of\\_aqueous](https://www.researchgate.net/publication/301649907_The_effects_of_aqueous)
18. Senders P. Causes of high liver enzyme test (ALT, AST and ALP). *Explain-Health.com*; 2011.
19. Mathew C, Nair C, Shenoy T, Varghese J. Preventive and curative effects of *Acalypha indica* on acetaminophen induced hepatotoxicity. *International Journal of Green Pharmacy*. 2011;49-54.
20. Masoud RE. Hepatoprotective effect of curcumin versus silymarin on paracetamol induced hepatotoxicity in rats. *International Journal of Pharmacology and Biological Sciences*. 2017;8(2):134-141.
21. Mingzhi Y, Hongbo H. Mechanisms of Acetaminophen-induced liver injury and its implications for therapeutic interventions. *Redox Biology*. 2018;17:274-283.

22. Elkott AF, El-Sayed SM, Abdel-Aziz AM. The effects of Ginger (*Zingiber officinale*) on histology and immunohistochemistry of liver and kidney and certain haematological parameters in Alloxan-induced Diabetic rats. Egypt Journal of Experimental Biology (zoology). 2018;6(1): 61-70.
23. Abdel-Azeem AS, Hegazu AM, Abraham K, Mahmud A, El-Sayed H. Hepatoprotective, antioxidant, and ameliorative effects of ginger (*Zinger officinale* Roscoe) and Vitamin E in Acetaminophen treated Rats. Journal of Dietary Supplement. 2013;10(3):195-209.
24. Lebda MA, Nabil MT, Korshim M, Amandour AA, Goda RI. Ginger (*Zingiber officinale*) potentiates paracetamol induced chronic hepatotoxicity in rats. Journal of Medicinal Plants Research. 2013;7(42) :3164-3170.
25. Ibrahim T, Agnihotri TI Agnihotri AK. Pracetamol toxicity: An overview. Emergency Medicine. 2013;3:158-3.
26. Badwi SM. Ameliorative effects of aqueous extracts of *Moringa oleifera* on acetaminophen- induced nephrotoxicity in rats. Journal of Humanities and Social Sciences. 2016;12(9):1-7.
27. Paliwal R, Sharma V, Precheta S, Yadav S, Sharma S. Anti-nephrotoxic effect of administration of *Moringa oleifera* Lam in amelioration of DMBA induced renal carcinogenesis in swiss albino mice. Biology and Medicine. 2011;3(2):27-35.
28. Mannem P. Protective effects of ginger extract against lead induced Hepatotoxicity in male albino rats. Journal of Environmental Sciences, Toxicology and Food Technology. 2014;8(5):53-59.
29. Hamed MA, Ali SA, El-Rigal NS. Therapeutic potential of ginger against renal injury induced by carbon tetrachloride in rats. The Scientific World Journal, 2012;12. Article ID 840421. Available:<http://doi.org/10.1100/2012/840421>
30. Eugenio-Perez. Role of food-derived antioxidant agents against Acetaminophen-induced hepatotoxicity. Pharmaceutical Biology. 2016;54(10):2340-2352.
31. Murad S, Nlaz K, Aslam H. Effect of ginger on LDL-C, Total cholesterol, body weight. Clinical Medicine Biochemistry. 2018;4: 140-142.
32. Elmasry A, Daba MH, El-Karet AA. Possible effects of *Moringa oleifera* versus Ginger (*Zingiber officinale*) on experimental colitis in mice. British Journal of Medicine and Medical Research. 2016; 16(2):1-19.

© 2021 Abaekwume and Kagbo; This is an Open Access article distributed under the terms of the Creative Commons Attribution License (<http://creativecommons.org/licenses/by/4.0>), which permits unrestricted use, distribution, and reproduction in any medium, provided the original work is properly cited.

*Peer-review history:*

The peer review history for this paper can be accessed here:  
<http://www.sdiarticle4.com/review-history/63885>