



## **Early Total Hip Replacement for Acetabular Fractures: Does Age Affect the Outcome?**

**Hosam El-Din Yosry Mashal<sup>1\*</sup>, Francesco M. Benazzo<sup>2,3,4</sup>,  
Walid Mohammed Ewis<sup>1</sup>, Moheb El-Din Ahmed Fadel<sup>1</sup>,  
Tarek Ibrahim Abo EINor<sup>1</sup> and Abdullah Said Hammad<sup>5</sup>**

<sup>1</sup>Orthopedic Surgery Department, Tanta University Hospital, Tanta, Egypt.

<sup>2</sup>Sezione di Chirurgia Protesica ad Indirizzo Robotico - Unità di Traumatologia dello Sport,  
U. O. Ortopedia e Traumatologia, Fondazione Poliambulanza, Brescia, Italy.

<sup>3</sup>Clinica Ortopedica E. Traumatologia, Fondazione IRCCS Policlinico San Matteo, Pavia, Italy.

<sup>4</sup>Università degli Studi di Pavia, Pavia, Italy.

<sup>5</sup>Orthopedic Surgery Department, Elhadarah University Hospital, Alexandria University, Alexandria, Egypt.

### **Authors' contributions**

*This work was carried out in collaboration among all authors. Eighteen patients underwent surgery by author ASH at Elhadarah University Hospital, Alexandria University, Egypt. Nine patients underwent surgery by author FMB at Fondazione IRCCS Policlinico San Matteo, University of Pavia, Italy. One patient underwent surgery at Tanta University Hospital, Egypt. Author HEI-DYM collected retrospective data through review of the patients' files, analyzed data and drafted the manuscript. Authors WME, MEI-DAF, TIAEIN and ASH supervised the study and revised the manuscript.*

### **Article Information**

DOI: 10.9734/JAMMR/2021/v33i1430978

Editor(s):

(1) Dr. Panagiotis Korovertis, General Hospital "Agios Andreas" Patras, Greece.

Reviewers:

(1) Ravitheja Jampani, Manipal University, India.

(2) Ameya Umesh Kulkarni, Sanjivan Hospital, India.

Complete Peer review History: <http://www.sdiarticle4.com/review-history/69842>

**Original Research Article**

**Received 18 April 2021**

**Accepted 23 June 2021**

**Published 29 June 2021**

### **ABSTRACT**

**Purpose:** The aim of this study is to compare the functional outcomes and complication rates of early total hip replacement (THR) for acetabular fractures in the young versus the elderly populations, in a trial to reach a higher level of evidence to know whether to expand or limit the application of early THR to young patients.

**Methods:** This was a multicenter retrospective comparative study that included patients who underwent early THR for an acetabular fracture in the period from February 2012 to December 2018 in one of three level one trauma centers. Patients were divided into an "elderly group" that included patients 65 years or older (seven males and seven females), and a "young group" that

\*Corresponding author: E-mail: [hosammashal@gmail.com](mailto:hosammashal@gmail.com);

included patients younger than 65 years (11 males and three females). The mean period of follow up was 33.57 months (range 12-84).

**Results:** The mean Harris Hip Score (HHS), at the final follow up, in the elderly group was 82.4 (range 75-92) while the mean HHS in the young group was 91.5 (range 72-100). The mean and median HHS in the young group were significantly higher than those in the elderly group. There was no statistically significant difference in the complication rate between the elderly and young patient groups.

**Conclusion:** Significantly superior functional outcomes are expected from young patients managed with early THR for acetabular fractures compared to elderly patients, with comparable complication rates between both age groups. Therefore, there is more confidence to apply this procedure to younger patients when indicated.

*Keywords: Acetabulum; fractures; total hip replacement; young; elderly.*

## INTRODUCTION

Acetabular fractures have a bimodal distribution, being common in young adults usually caused by high energy trauma, and nowadays becoming increasingly common in elderly patients usually caused by low energy trauma [1]. The definition of elderly is somewhat controversial. However, the World Health Organization (WHO) stated that most developed countries agreed on the age of 65 years to define an elderly person [2].

There is a relatively lower threshold to accept hip replacement as a primary treatment for acetabular fractures in the elderly population in comparison to younger adults. Many authors studied acute total hip replacement (THR) for treatment of fractures of the acetabulum in the elderly population. Most of them concluded that acute THR is a good treatment option in this patient population [3–11].

On the other hand, the gold standard for treatment of fractures of the acetabulum in younger patients is open reduction and internal fixation (ORIF) [12]. However, in certain situations ORIF is expected to yield unsatisfactory outcome. Poor outcome is expected with non-anatomic reduction, late presentation, posterior wall fracture, impaction of the articular cartilage of the acetabulum, full thickness damage or impaction of the cartilage of the head of femur, associated fractures of the head or displaced fractures of the neck of femur and extensive acetabular fracture comminution [12–15]. All of these factors, except for quality of reduction, are injury-related factors that are uncontrollable by the surgeon and will only predict poor outcome [16].

Poor outcome after ORIF of an acetabular fracture is typically salvaged by THR. However, THR following previous acetabular fracture

fixation surgery is complex with inferior results compared to primary THR for arthritis, longer surgical times, and higher complication and revision rates [17,18].

Therefore, in limited indications, acetabular fractures in young patients can be treated by acute THR [16,19,20]. Reviewing the literature, the number of young patients who underwent acute THR for acetabular fractures is relatively low and a few authors studied acute THR in the young patient population [16,19,20].

MacCormick et al. [16] compared acute THR versus ORIF for posterior wall fractures in middle aged patients. After a mean follow up period of 6.2 years, the mean Oxford Hip Score in the ORIF group was 40 compared to 44 in the acute THR group. Thirty seven percent of patients in the ORIF group had undergone or been referred for THR by the end of follow up, while 13% of patients in the acute THR group had undergone revision. They concluded that acute THR achieved higher functional scores and significantly better survival of the index procedure [16].

Mears and Velyvis [18] identified three distinct time periods after a fracture of the acetabulum when a THR merits consideration; acutely within three weeks of the injury, between three weeks and three months, and at three months or later. Eid [21] noted that although the first two groups had some differences regarding the increased difficulty of the operation due to fracture callus, but at last the fracture was always incompletely united and could still be manipulated and reduced as a way of management of the defects. Therefore, He combined the first two groups and referred to them as early THR [21].

To our knowledge, there are no comparative studies in literature comparing the functional outcomes and complication rates of early THR

for fractures of the acetabulum in the young versus the elderly populations.

The aim of this study is to compare the functional outcomes and complication rates of early THR for fractures of the acetabulum in the young versus the elderly populations, in a trial to reach a higher level of evidence to know whether to expand or limit the application of early THR to young patients.

**2. PATIENTS AND METHODS**

This was a multicenter retrospective comparative study that included patients who underwent early THR for an acetabular fracture in the period from February 2012 to December 2018 in one of three level I trauma centers; Orthopedic Surgery Department, Tanta University Hospital, Egypt, Orthopedic Surgery Department, Elhadarah University Hospital, Alexandria University, Egypt, and Orthopedic Surgery Department, Fondazione IRCCS Policlinico San Matteo, University of Pavia, Italy. Early THR was defined as THR within three months from injury according to Eid modification of Mears and Velyvis classification [18,21]. Retrospective data were collected through review of the patients' files after Ethics Committee approval. Patients with follow up of less than one year and patients with ipsilateral lower limb fractures distal to the hip were excluded. The study included 28 patients.

Patients were divided into two groups; "elderly group" that included patients 65 years or older at time of trauma according to WHO definition of elderly [2], and "young group" that included patients younger than 65 years at time of injury. The elderly group included 14 patients (seven males and seven females) and the young group included 14 (11 males and three females).

The mean age ± standard deviation (SD) in the elderly group was 76.86 years ± 7.62 (range 65-89 years) while the mean age ± SD in the young group was 45.36 ± 10.97 years (range 20-60 years).

The fractures were caused by a simple fall (low energy trauma) in eight out of 14 patients in the elderly group (57.14%) while the remaining six patients sustained a fracture due to a road traffic accident. All fractures in the young group were caused by road traffic accidents.

The classification of Letournel and Judet [22] was used to classify fractures. The elderly group included five anterior (ant.) column fractures, three posterior (post.) wall, two anterior column with posterior hemitransverse, two T-shaped, one transverse and one post. wall and column fracture. The young group included 11 post. wall fractures, two T-shaped and one post. wall and column fracture.

The mean duration from trauma to surgery ± SD in the elderly group was 14.5 ± 20.98 days (range 1-88 days) while the mean duration from trauma to surgery ± SD in the young group was 38.86 ± 30.05 days (range 1-84 days). Delay in surgery was due to associated injuries, the patient's medical condition, missed injuries or delayed referral from non-specialized centers.

The indications for the procedure are listed in table 1.

**2.1 Surgical Technique**

The surgical technique was the same for both the young and the elderly groups. Surgery was performed under spinal anesthesia in 16 patients and under general anesthesia in 12 patients. The patients received a dose of prophylactic intravenous antibiotics with induction of anesthesia. The fracture pattern was the key factor that determined the surgical approach and sequence of surgery. As a general rule, the aim was to achieve a stable fixation rather than perfect fracture reduction. The surgical technique is summarized in Figs. 1,2.

The wound was closed in layers over a vacuum drain in all patients. The mean operative time ± SD was 188.75 ± 75.33 minutes ranging from 105 to 395 minutes.

**Table 1. Indications for the procedure**

<b>Indication<sup>a</sup></b>	<b>Elderly group</b>	<b>Young group</b>
Extensive acetabular articular surface comminution or impaction	12	2
Late presentation (After > 4 weeks)	1	8
Associated femoral neck fracture	2	3
Associated femoral head fracture	0	2
Marked femoral head impaction	1	2
Concurrent hip osteoarthritis	1	0

*a: Many patients had more than one indication for the procedure*

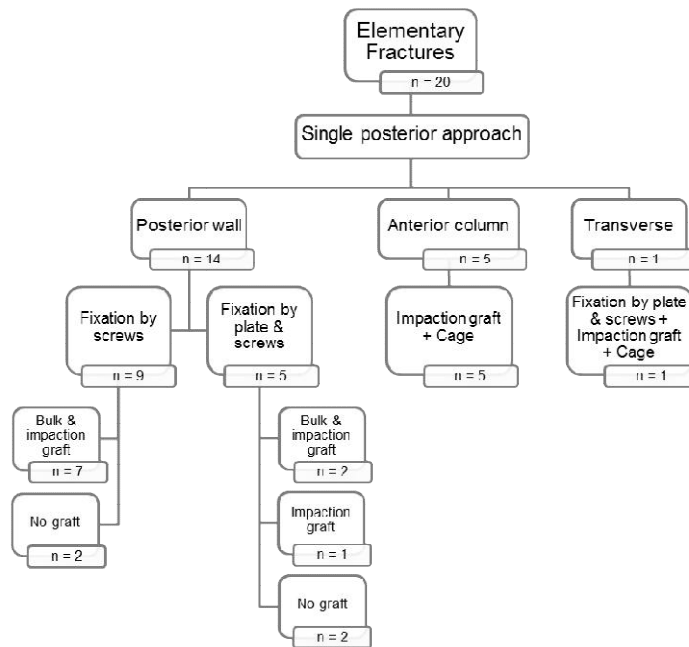


Fig. 1 Summary of surgical technique for elementary fractures

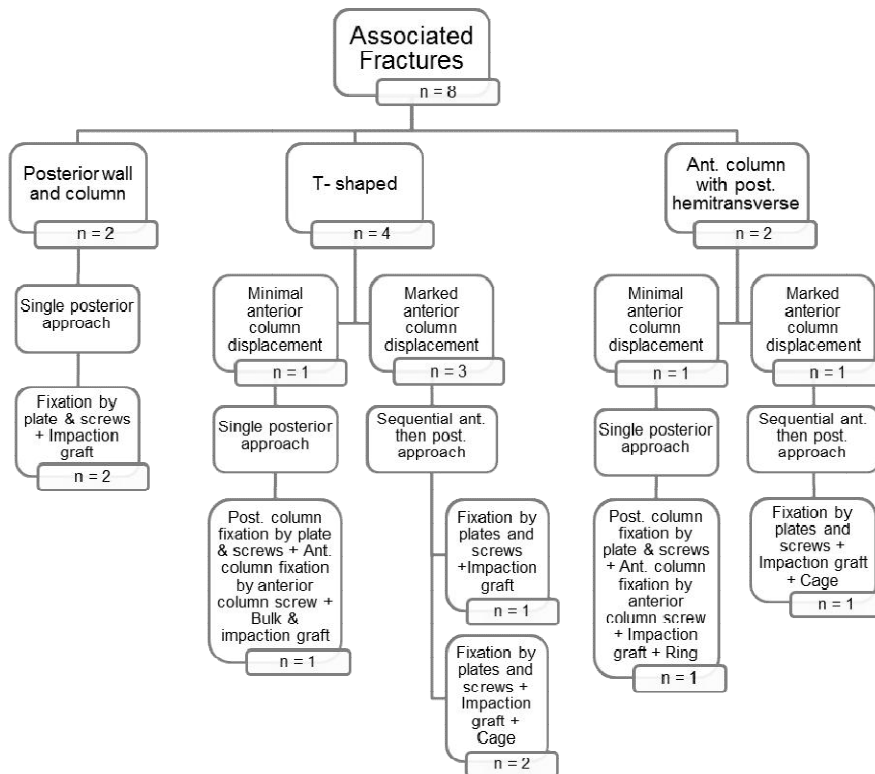


Fig. 2. Summary of surgical technique for associated fractures

## 2.2 Implants

In the elderly group, cemented THR was implanted in seven cases, reverse hybrid in six cases and cementless THR in one case. In the young group, cemented THR was implanted in six patients, cementless THR in five patients and reverse hybrid in three patients. Implant choice depended on bone quality, use of a cage or ring that necessitated cemented cup, surgeon's preference, implant availability and cost factors.

## 2.3 Post-operative Protocol

The post-operative protocol was the same for both the young and the elderly groups. The routine post-operative protocol included intravenous prophylactic antibiotics (first generation cephalosporin) for the first 24 hours after surgery, removal of the drain 48 hours after surgery, oral indomethacin 100 mg/day for one month as heterotopic ossification prophylaxis and low molecular weight heparin for six weeks as thrombo-embolic prophylaxis.

Weight bearing was delayed in six patients due to associated injuries that precluded early weight bearing. The remaining 22 patients were encouraged to start mobilization out of bed on the second day after surgery with touch down weight bearing that continued for six weeks. Afterwards, full weight bearing was gradually started depending on patient's ability and the reconstruction done.

## 2.3 Follow Up

The follow up protocol was the same for both patient groups. The mean period of follow up  $\pm$  SD was  $33.57 \pm 19.72$  months (range 12-84 months). The patients were subjected to clinical and radiological evaluations at each follow up visit which were scheduled at six weeks, three months, six months, and one year after surgery, and then annually thereafter.

Patients were assessed clinically using Harris Hip Score (HHS) [23]. The score obtained at the last follow up was considered the final score that was included in the statistical analysis of the results.

Plain radiographs of the affected hip in antero-posterior (AP) and lateral views were used for radiological assessment. Radiographs were used to assess fracture union, femoral head autograft incorporation, stability of the femoral and

acetabular components and to detect complications such as osteolysis and heterotopic ossification.

The safe zone of Lewinnek et al [24] was used to assess cup orientation. The method described by Russotti and Harris [25] was used to assess medial and vertical cup migration and changes in the cup angular position. Cup loosening was defined as cup migration greater than 4 mm in any direction or a change in the abduction angle of the cup greater than  $4^\circ$  compared to the immediate post-operative radiographs. Brooker et al method [26] was used to assess heterotopic ossification. Osteolysis around the cup and stem was assessed using the methods of DeLee and Charnley [27] and Gruen et al [28] respectively.

## 2.4 Statistical Analysis [29]

The IBM SPSS software package version 20.0 (Armonk, NY: IBM Corp) [30] was used for data analysis. Number and percent were used to describe qualitative data. Variables normality of distribution was verified using the Kolmogorov-Smirnov, Shapiro and D'Agostino tests. Range (minimum and maximum), mean, standard deviation and median were used to describe quantitative data. Chi-square test (Fisher or Monte Carlo) was used to compare categorical variables between groups. Comparing normally distributed quantitative variables between two groups was performed using Student t-test. Significance of the results was judged at the 5% level.

## 3. RESULTS

### 3.1 Clinical Assessment

The mean HHS  $\pm$  SD, at the last follow up, was  $82.4 \pm 6.4$  (range 75-92) in the elderly patient group while the mean HHS in the young patient group was  $91.5 \pm 8.5$  (range 72-100). The mean and median HHS in the young group were significantly higher than those in the elderly group (Table 2).

### 3.2 Radiological Assessment

All fractures were seen to be united radiographically by six months after surgery and femoral head autograft was well incorporated in all cases. There were no cases of delayed union, nonunion or loosening of the cup or stem at the last follow up.

### 3.3 Complications

Table 3 includes the encountered complications. Difference in the complication rate between the elderly and young patient groups was statistically insignificant.

### DISCUSSION

THR is a common treatment option for many diseases and traumatic conditions in the elderly population. Low functional demand and the need for early mobilization could justify this option after acetabular fractures in this age group. The condition in younger adults is different. Whether THR will behave similarly in both age groups or not was the essence of this study.

Early THR in geriatric acetabular fractures has been studied by many authors [6–8,10] while few authors studied early THR for acetabular fractures in younger patients [16,19,20]. We could not find comparative studies in literature comparing the results of early THR for fractures of the acetabulum in the elderly versus the young populations. However, some authors included elderly and young patients in their series. Mears and Velyvis [14] in their study included 57 patients with a mean age of 69 years (range 26-89). Most of the patients in their study were 60 years or older (68%). They found that the functional outcomes for the patients deteriorated with age which is concordant with the results of our study. However, they did not compare the complication rates in different age groups.

Reviewing the literature, heterotopic ossification (HO) was the most common complication following THR for acute acetabular fractures [31]. However, in most studies, function was not affected by HO which was therefore managed conservatively in most cases except for class IV that commonly required surgical excision [6–8,10,14]. In our study, although HO was more common in the elderly group in comparison to the young group, this was found to be statistically insignificant. Moreover, HO had an insignificant effect on the functional outcome of all patients except for a single patient who developed hip stiffness due to Class IV HO that required surgical excision eight months after the first surgery. This is concordant with the reviewed literature.

The second most commonly reported complication in literature was post-operative dislocation [31]. It was a common complication in our study as well. Dislocation rate was comparable between both groups in our study. Three patients reported dislocation after faulty movements. Therefore, a more restrictive post-operative protocol is required in early THR for acetabular fractures as patients were used to free motion of their native hips before injury. Impingement on the reinforcement cage or ring could be the possible cause in two patients, so careful intraoperative positioning of cages or rings and testing full range of movement at the end of surgery are mandatory to reduce impingement and dislocation rates. Future studies using dual mobility cups can be of great value in this aspect.

**Table 2. Comparison between both groups according to HHS**

	Elderly group (n = 14)	Young group (n = 14)	Test of sig.	p
<b>HHS</b>				
Mean ±SD.	82.4± 6.4	91.5 ± 8.5	t=3.187*	0.004*
Median (Min. – Max.)	80(75 – 92)	92(72 – 100)		

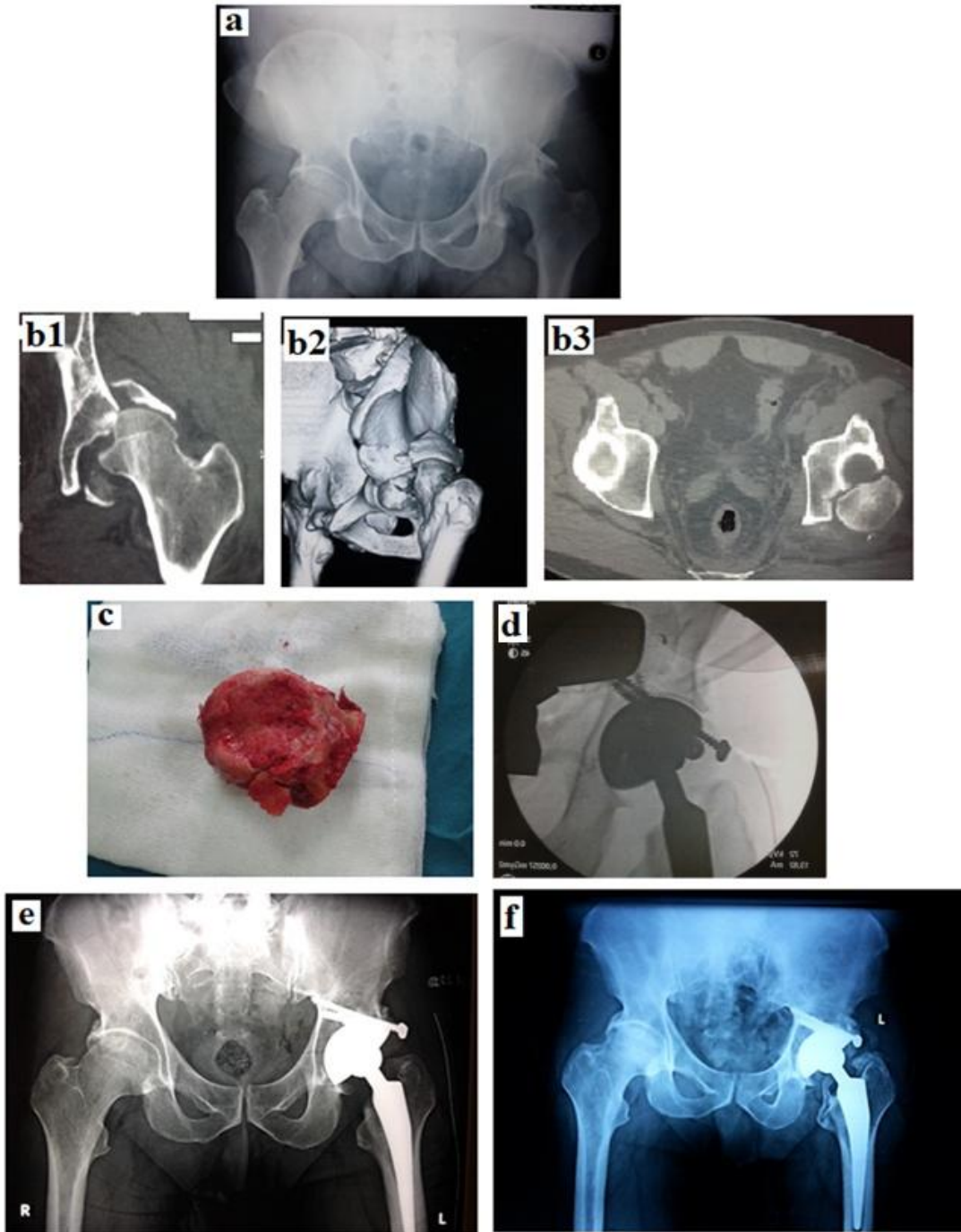
*t: Student t-test*

*p: p value for comparison between both groups; \*: Statistically significant at p ≤ 0.05*

**Table 3. Comparison between both groups according to complications**

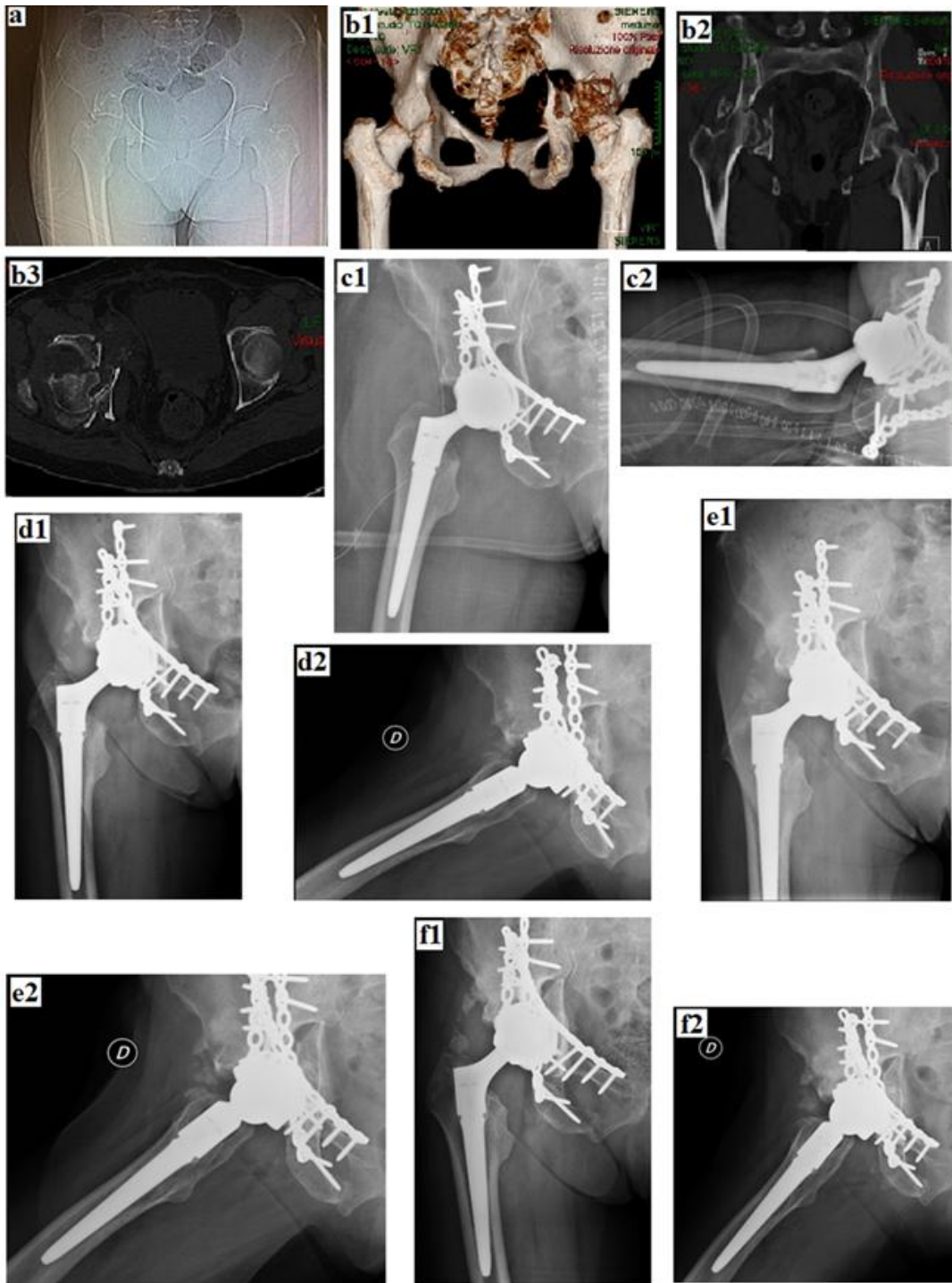
Complications	Elderly group (n = 14)	Young group (n = 14)	$\chi^2$	p
No	6(42.9%)	7(50%)		
<b>Yes</b>	<b>8(57.1%)</b>	<b>7(50%)<sup>a</sup></b>	0.144	0.705
Heterotopic ossification	6(42.9%)	2(14.3%)	2.800	0.209
Dislocation	2(14.3%)	3(21.4%)	0.243	1.000
Infection	0(0%)	1(7.1%)	1.037	1.000
Nerve injury	0(0%)	1(7.1%)	1.037	1.000
Vascular injury	0(0%)	1(7.1%)	1.037	1.000

$\chi^2$ : *Chi square test*; *p: p value for comparison between the studied groups; a: One patient had two complications*



**Fig. 3** Thirty six years man (from the young group) with left hip posterior fracture dislocation with posterior wall left acetabular fracture associated with femoral head fracture and marked impaction. a Pre-operative radiograph. b (b1, b2, b3) Pre-operative CT scan. c Intra-operative photo of the resected head of femur showing fracture and marked impaction. d Intra-operative fluoroscopic image. e Immediate post-operative radiograph. f Follow up radiograph two years post-operatively showing class III heterotopic ossification





**Fig. 4** Sixty nine years old woman (from the elderly group) presented with right hip posterior fracture dislocation with a T shaped with comminuted posterior wall right acetabular fracture associated with marked femoral head impaction. a Pre-operative plain X-ray. b (b1, b2, b3) Pre-operative CT scan. c (c1, c2) Immediate post-operative X-rays. d (d1, d2) Follow up X-rays three months post-operatively. e (e1, e2) Follow up X-rays six months post-operatively. f (f1, f2) Follow up X-rays one year post-operatively showing class II heterotopic ossification



Limitations of our study include its retrospective design, the relatively small cohort size in each group, different implants were used and the follow up period was relatively short with inability to judge implant survival. A future prospective study including a larger cohort of patients with a longer period of follow up is recommended. On the other hand, the strengths of this study include being the first study comparing functional outcomes and complication rates in the elderly versus the young patient groups. Moreover, the sample was representative for variable fracture types.

## CONCLUSION

In conclusion, significantly superior functional outcomes are expected from young patients managed with early THR for acetabular fractures compared to elderly patients, with comparable complication rates between both age groups. Therefore, there is more confidence to apply this procedure to younger patients when indicated.

## AVAILABILITY OF DATA AND MATERIAL

The data that support the findings of this study are available from the corresponding author upon reasonable request.

## CONSENT

As per international standard or university standard, patients' written consent has been collected and preserved by the author(s).

## ETHICAL APPROVAL

Ethical approval was waived by the local Ethics Committee of Tanta University and local Ethics Committee of Alexandria University in view of the retrospective nature of the study and all the procedures being performed were part of the routine care.

## COMPETING INTERESTS

Authors have declared that no competing interests exist.

## REFERENCES

1. Ferguson TA, Patel R, Bhandari M, Matta JM. Fractures of the acetabulum in patients aged 60 years and older: An epidemiological and radiological study. *J Bone Joint Surg Br.* 2010;92:250–257.
2. WHO. WHO Proposed working definition of an older person in Africa for the MDS Project. In: World Heal. Organ; 2016. Available: <https://www.who.int/healthinfo/survey/ageingdefnolder/en/>. Accessed 12 Jul 2020
3. Borens O, Wettstein M, Garofalo R, et al. Treatment of acetabular fractures in the elderly with primary total hip arthroplasty and modified cerclage. Early results. *Unfallchirurg.* 2004; 107:1050–1056
4. Mouhsine E, Garofalo R, Borens O, et al. Cable fixation and early total hip arthroplasty in the treatment of acetabular fractures in elderly patients. *J Arthroplasty.* 2004;19:344–348.
5. Simko P, Braunsteiner T, Vajcziková S. Early primary total hip arthroplasty for acetabular fractures in elderly patients. *Acta Chir Orthop Traumatol Cech.* 2006;73:275–282
6. Tidermark J, Blomfeldt R, Ponzer S, et al. Primary total hip arthroplasty with a Burch-Schneider antiprotrusion cage and autologous bone grafting for acetabular fractures in elderly patients. *J Orthop Trauma* 2003;17:193–197
7. Cochu G, Mabit C, Gougam T, et al. Total hip arthroplasty for treatment of acute acetabular fracture in elderly patients. *Rev Chir Orthop Reparatrice Appar Mot.* 2007;93:818–827
8. Malhotra R, Singh DP, Jain V, et al. Acute total hip arthroplasty in acetabular fractures in the elderly using the Octopus System: mid term to long term follow-up. *J Arthroplasty.* 2013; 28:1005–1009
9. Saxer F, Studer P, Jakob M. Open stabilization and primary hip arthroplasty in geriatric patients with acetabular fractures: combination of minimally invasive techniques. *Unfallchirurg.* 2011; 114:1122–1127
10. Herscovici Jr D, Lindvall E, Bolhofner B, Scaduto JM. The combined hip procedure: open reduction internal fixation combined with total hip arthroplasty for the management of acetabular fractures in the elderly. *J Orthop Trauma.* 2010;24:291–296.
11. Salama W, Mousa S, Khalefa A, et al. Simultaneous open reduction and internal fixation and total hip arthroplasty for the treatment of osteoporotic acetabular fractures. *Int Orthop.* 2017;41:181–189
12. Tannast M, Najibi S, Matta JM. Two to Twenty-Year Survivorship of the Hip in 810 Patients with Operatively Treated Acetabular Fractures. *JBJS.* 2012;94:1559–1567

13. Matta JM. Fractures of the acetabulum: accuracy of reduction and clinical results in patients managed operatively within three weeks after the injury. *J Bone Joint Surg Am.* 1996;78:1632–1645
14. Mears DC, Velyvis JH. Acute total hip arthroplasty for selected displaced acetabular fractures: two to twelve-year results. *JBJS.* 2002;84:1–9.
15. Johnson EE, Matta JM, Mast JW, Letournel E ( ) Delayed reconstruction of acetabular fractures 21-120 days following injury. *Clin Orthop Relat Res.* 1994;20–30.
16. Mac Cormick LM, Lin CA, Westberg JR, et al. Acute total hip arthroplasty versus open reduction internal fixation for posterior wall acetabular fractures in middle-aged patients. *Ota Int.* 2019; 2:e014
17. Romness DW, Lewallen DG. Total hip arthroplasty after fracture of the acetabulum. Long-term results. *J Bone Joint Surg Br.* 1990;72:761–764
18. Mears DC, Velyvis JH. Primary total hip arthroplasty after acetabular fracture. *Instr Course Lect.* 2001;50:335–354.
19. Wang ZM, Sun HZ, Wang AM, et al. Primary total hip arthroplasty for acetabular fracture. *Chinese J Traumatol Zhonghua chuang shang za zhi.* 2006;9:341–344.
20. Yang SH, Zhang YK, Xu WH, et al. Early total hip arthroplasty for severe displaced acetabular fractures. *Chinese J Traumatol Zhonghua chuang shang za zhi.* 2006;9:329–333.
21. Eid MA. Prosthetic Hip Replacement in Patients with Fractures of the Acetabulum. Dissertation, Cairo University; 2011.
22. Judet R, Judet J, Letournel E. Fractures of the acetabulum: classification and surgical approaches for open reduction: preliminary report. *JBJS.* 1964;46:1615–1675.
23. Harris WH. Traumatic arthritis of the hip after dislocation and acetabular fractures: treatment by mold arthroplasty: an end-result study using a new method of result evaluation. *JBJS.* 1969; 51:737–755
24. Lewinnek GE, Lewis JL, Tarr R, et al. Dislocations after total hip-replacement arthroplasties. *J Bone Jt Surg Am.* 1978;60:217–220.
25. Russotti GM, Harris WH. Proximal placement of the acetabular component in total hip arthroplasty. A long-term follow-up study. *J Bone Joint Surg Am.* 1991;73:587–592.
26. Brooker AF, Bowerman JW, Robinson RA, Riley Jr LH. Ectopic ossification following total hip replacement: incidence and a method of classification. *JBJS.* 1973;55:1629–1632.
27. DeLee JG, Charnley J. Radiological Demarcation of Cemented Sockets in Total Hip Replacement. *Clin Orthop Relat Res.* 1976;121:20–32
28. Gruen TA, McNeice GM, Amstutz HC. Modes of failure of cemented stem-type femoral components: a radiographic analysis of loosening. *Clin Orthop Relat Res.* 1979;17–27.
29. Kots S, Balakrishnan N, Read C, Vidakovic B. *Encyclopedia of statistical sciences*, 2nd edn. Wiley-Interscience, Hoboken, NJ; 2006.
30. Kirkpatrick LA, Feeney BC. *A simple guide to IBM SPSS statistics for version 20.0.* Wadsworth, Cengage Learning, Belmont, Calif; 2013.
31. Jauregui JJ, Clayton A, Kapadia BH, et al. Total hip arthroplasty for acute acetabular fractures: a review of the literature. *Expert Rev Med Devices.* 2015;12:287–295.

© 2021 Mashal et al.; This is an Open Access article distributed under the terms of the Creative Commons Attribution License (<http://creativecommons.org/licenses/by/4.0>), which permits unrestricted use, distribution, and reproduction in any medium, provided the original work is properly cited.3

*Peer-review history:*  
*The peer review history for this paper can be accessed here:*  
<http://www.sdiarticle4.com/review-history/69842>